



RESEARCH PAPER

OPEN ACCESS

Effects of essential amino acid “Tryptophan” in post burn skin wound healing

Alia Sadiq^{*1}, Muhammad Qasim Hayat¹, Gulshan Ara Trali², Ambreen Javed²

¹*Atta-ur-Rahman School of Applied Biosciences (ASAB), National University of Science and Technology (NUST), Islamabad, Pakistan*

²*Department of Biochemistry, HITEC-IMS Taxila Cantt. Pakistan*

Key words: Wound healing, Tryptophan, BrdU, CD31, Angiogenesis, Proliferation.

<http://dx.doi.org/10.12692/ijb/12.3.137-143>

Article published on March 26, 2018

Abstract

Skin wound healing is a complex process and regulated by various growth factors and vital compounds. This study was carried out to assess the role of tryptophan in post burn skin wound healing by using scald burn model in Balb C mice. We employed tryptophan as topical cream formulation in post burn wound model. Post-wounding analysis showed improved healing represented by smaller wound length, wound area and increased wound cellularity in tryptophan treated group as compared to the control. Comparatively, enhanced expression of CD31 also observed in tryptophan treated group, indicated improved angiogenesis. Immunohistochemical staining showed more number of BrdU+ve proliferating cells in the wound center, revealed that proliferation rate was significantly high in the treated group. It is suggesting that wounds treated with the tryptophan conceded the proliferation phase faster. This study revealed that tryptophan (an essential amino acid) has potential to improve the burn skin wound healing. Therefore, tryptophan-based therapeutics can be a potential candidate to investigate further about their mechanism of action for improved wound healing process.

* **Corresponding Author:** Alia Sadiq ✉ aliasadiq55@hotmail.com

Introduction

Skin injury that doesn't heal within the time of minimum three months, is categorized as chronic wound. Most of the chronic wounds which are result of burn or skin ulcers, exhibit more complications and delayed healing. Because of reduced healing tendency, these wound injuries become more susceptible to the infection and consequently increase the morbidity rate in those patients, despite the long-term wound management and hospitalization. This result in significant economic burden on health care sector as well (Mani *et al.*, 2002; Lerman *et al.*, 2003). Impairment in wound healing mechanism leads toward wound chronicity. Nowadays, this is an emerging challenge in healthcare sector. Since past, research studies have been focusing on exploration of new treatment alternatives having specific pharmacological manipulations for targeting chronic wound healing pathways for improved healing (Richter *et al.*, 1997). In spite of these efforts, promising therapeutics for improved wound healing process have not been fully established yet (Manzke *et al.*, 2010). This scenario reflects that despite the development of numerous therapies, still there is need for finding innovative therapeutics for improved and faster wound healing process (Demidova-Rice *et al.*, 2011).

Tryptophan is well known as vital compound and essential amino acid. It is a precursor of serotonin [5 hydroxytryptamine (5-HT)] a neurotransmitter, which regulates mood, gastrointestinal functions and appetite (Lieberman, 2003; Le Floch *et al.*, 2011). A pilot study found that malnutrition in patients due to inadequate protein dietary sources and micronutrient intake, is an important risk factor that cause the development of ulcer particularly in adult and older patients and its severity is associated with high risk of morbidity and mortality. Clinical investigations revealed that tryptophan level has been found very low in wound patients as compared to all other amino acids. Out of 18 wound cases, 16 were facing tryptophan deficiency that mean patients with wounds are most likely at high risk in term of compromised healing and wound chronicity (Dawson and Favaloro, 2007).

Tryptophan has been evaluated in various other clinical studies, particularly in neuroendocrinologic and neuropsychiatric domains (Richard *et al.*, 2009; Sandyk, 1992; Traskman-Bendz *et al.*, 1986; Celinski *et al.*, 2011), but its role in wound healing has not been investigated extensively. It is well known that normal wound repair process consists of several overlapping phases with time course such as inflammation, proliferation (new tissue formation), and remodeling, which occurs in a predictable series of cellular and biochemical events (Nunan *et al.*, 2014). Recently, it has been found that in chronically stressed mice, tryptophan treatment reduced the inflammation and accelerated the excisional wound healing by inhibiting TNF- α and activation of Indoleamine 2, 3- dioxygenase (Bandeira *et al.*, 2015). *In vitro* culture model showed that tryptophan treatment enhanced the rate of scratch recovery. Same experimental study extended in lower limb ulcer patients and tryptophan treatment applied as topical application. Research findings revealed that tryptophan showed promising potential for wound healing by inducing faster re-epithelization through activation of Aryl Hydrocarbon receptor (Barouti *et al.*, 2015). Another research study stated that tryptophan induced activation of Aryl Hydrocarbon receptor resulted in mucosal healing of intestinal epithelia (Lanis *et al.*, 2017). These findings prompt us to hypothesize that tryptophan may have healing potential in burn induced injuries as well. Therefore, taking into consideration healing potential of tryptophan, we conducted this study to evaluate the effect of tryptophan in burn wound healing process.

Material and Methods

Drugs

Tryptophan, Ketamine, Ringer's lactate solution, Buprenorphine (Sigma Aldrich® Inc).

Animal

Balb C mice were purchased from National Institute of Health (NIH), Islamabad, Pakistan. Study was approved and followed all guidelines of Animal Policy and Welfare Committee, at Atta-ur-Rahman School of Applied Biosciences (ASAB), National University of Science and Technology (NUST) H-12 Islamabad, Pakistan.

In vivo Thermal Injury Procedure

Animals (male Balb C mice, body weight 25g, 6 weeks old) were divided into two experimental groups (1) tryptophan treatment and (2) control group. These study groups were subjected to a scald burn animal protocol with slight modifications. Briefly, the mice were anesthetized with ketamine and body weights were recorded. Dorsal surface of the mouse was shaved. Buprenorphine was administered by intraperitoneal injection. Ringer's lactate solution (1mL, intraperitoneal injection) administered to resuscitate the mice. After anesthesia, mouse was positioned in a burn mold (exposing 25% TBSA; total body surface area, along with whole dorsal spine surface). Burn mold containing mice was immersed in hot water (98°C) for 10 seconds to produce scald burn. After that mice put back into experimental cages immediately. Mice were monitored until they were fully awake and shifted back into the animal room. Sham treatment only received anesthesia and Ringer's lactate solution to induce resuscitation. We applied tryptophan as 1% topical cream formulation twice a day for two weeks post-burn, till harvest day in treatment group. Vehicle used in control group following similar route of drug administration (Topical administration). Wound healing was monitored regularly, and observations were recorded daily till harvest day. Mice were sacrificed on day 14 and biopsies were taken from wound sites and normal skin for comparison. These tissue samples were subsequently processed for respective histology and immunohistochemistry (Ansell *et al.*, 2014).

Skin Histology

Animals were received an intraperitoneal injection of bromodeoxyuridine (BrdU), twenty-four hours before harvesting. Histological examination was carried in wound center. Skin tissue specimens were subjected to fixation, trichrome staining and photographed by using a light microscope (Zeiss Axiovert 200; 5x, 10x and 40x magnification). Quantification was carried out to measure the reepithelialisation, wound cellularity (cell count) and wound size (wound length and area). All analysis done blindly between the samples (5 images/sample) (Mori *et al.*, 2004; Ansell *et al.*, 2014).

Immunohistochemistry

Paraffin-embedded skin tissue slides were subjected to immunohistochemical staining. Skin sections were rehydrated and then deparaffinized with xylene. Antigen decloaker (1X; Biocare) was preheated for 4 minutes at 110°C and then slides were put into the chamber. Skin sections were denatured by using 1.5 N HCl (30 minutes at 37°C) and neutralized by 0.1 M borate buffer (twice for 5 minutes). H₂O₂ (3%) was used for 10 minutes to block the samples and then washed with wash buffer. Primary antibodies (Serotec; CD31, 1:250; mouse monoclonal anti-BrdU, 1:200; Cell Signaling) were diluted in PBS and incubated (room temperature for one hour). After this MACH3 mouse probe was added into slides and incubated for 15 minutes, washed and MACH3 mouse horseradish peroxidase polymer was added and washed again. Betazoid diaminobenzidine chromogen kit (Biocare Medical) was added for 5 minutes and the reaction was stopped with tap water. Later hematoxylin stain was used for 30 seconds to stain the nuclei. Differentiation was carried out by dipping into 1.5% acid alcohol three times and 0.1% Na₂CO₃. After this ethanol (95%) and absolute ethanol were used for dehydration and slides were mounted with mounting media. Stained skin section slides were subjected to photography by using Zeiss Axiovert 200 light microscope at magnification of 5x, 10x, and 40x. Images were analyzed for quantification blindly (Weller *et al.*, 2006).

Statistical Evaluation

Results were presented as mean ± standard deviation (SD), 95% confidence interval after applying student's t-test by using Microsoft Excel version 8. Statistical significance was set at *P ≤ 0.05 and **P ≤ 0.01.

Results

Tryptophan improved post burn skin healing

Post-harvest wound analysis showed that control group exhibited poor wound healing histology as compared to tryptophan treated group (Trp) (Fig 1A). The total wound area was found bigger in control group as compared to Trp treated group (18.94x10⁻³µm² ± 1.4 > 14.67x 10⁻³µm² ± 0.98 respectively) (Fig 1B).

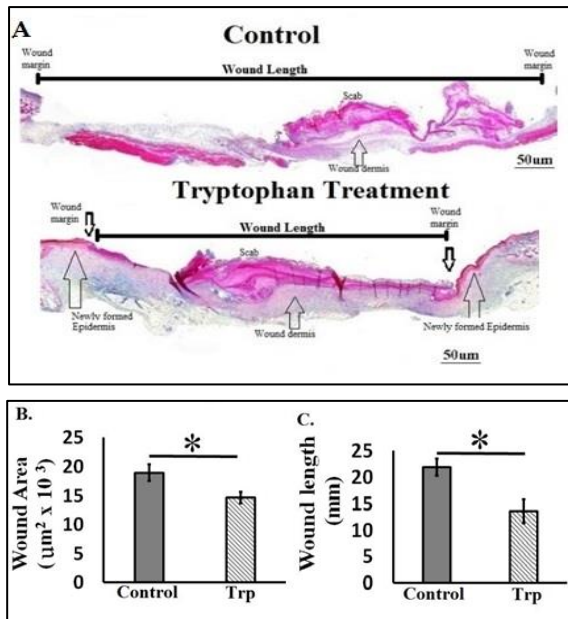


Fig. 1. (A) Comparative burn wound healing in control and tryptophan treated group in post thermal injury (Burn Model). Masson's trichrome staining of two weeks' post burned skin. Representative burn wound cross-section (10x images). (B) Wound area (μm^2). (C) Wound length (mm). Results presented as mean \pm Standard Deviation (S.D), (n=5, *P<0.05, **P<0.01).

Observations and quantitative analysis of wound revealed that wound length at 14th day post burn was also decreased in Trp treated group as compared to control group ($13.56 \text{ mm} \pm 2.3 < 21.94 \text{ mm} \pm 1.6$ respectively) (Fig 1C). Tryptophan treated group showed reepithelization process exhibited by the formation of new epidermal cover in wounded area, started near left and right wound margins and progressing towards wound center (Fig 2A and 2B).

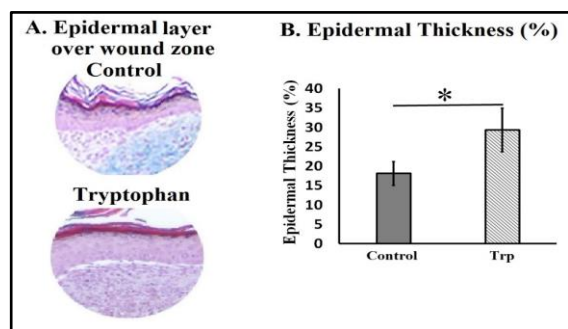


Fig. 2. (A) Newly formed epithelial layer zoomed at right margins in each image. (B) Reepithelialisation presented as percentage (%) \pm Standard Deviation (S.D), (n=5, *P<0.05, **P<0.01).

Newly formed epidermal layers over wound area were significantly thick in Trp treated group ($29.27 \text{ mm} \pm 5.6 > 18.09 \text{ mm} \pm 3.06$, respectively). It has been observed that tryptophan induced significantly high wound cellularity (number of cells $337 \pm 6 > 245 \pm 1.9$ respectively) (Fig 3A and 3B). This raises the possibility that tryptophan promotes the cell proliferation in dermal fibroblasts in wound area. Hence, tryptophan either through promoting the proliferation of cells or enhancing the cell migration, contribute to granulation tissue formation and subsequently results in better wound healing.

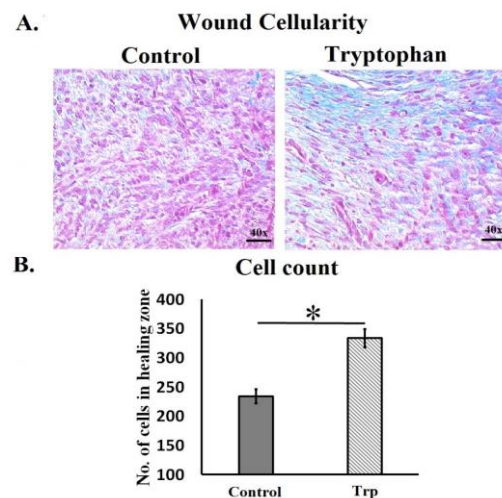


Fig. 3. (A) Wound cellularity in wound dermal region of tryptophan and control group (40x images). (B) Total cell count was presented as mean no of cells \pm Standard Deviation (S.D), (n=5, *P<0.05, **P<0.01).

This observation was supported by immunostaining for proliferation marker BrdU in dermal fibroblasts, that also showed significantly decreased BrdU expression in control group as compared to Trp treated ($16.03\% \pm 4.03 < 35.17\% \pm 1.7$, respectively) (Fig 4A and 4B).

Furthermore, to observe the angiogenesis during wound healing, wound section stained with CD31 endothelial marker. CD31 expression in Trp-treated group (Fig 5A and 5B) indicated a significant increase in blood vessels number (mean number of vessels = $33 \pm 7 > 11 \pm 4$) as compared to control group at 14th day post burn. These observations revealed that tryptophan treatment promoted and regulated the neovascularization process in postburn healing, which contributed towards better healing as compared to control.

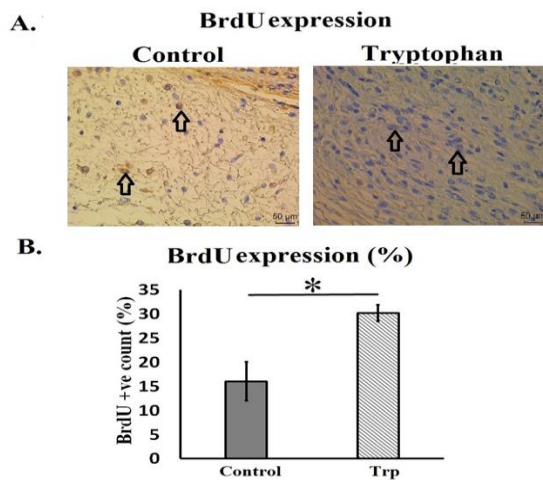


Fig. 4. (A) Tryptophan treatment enhanced dermal fibroblast proliferation (40x images). (B) BrdU expression was presented as percentage of BrdU positive cells \pm Standard Deviation (S.D), (n=5, *P<0.05, **P<0.01).

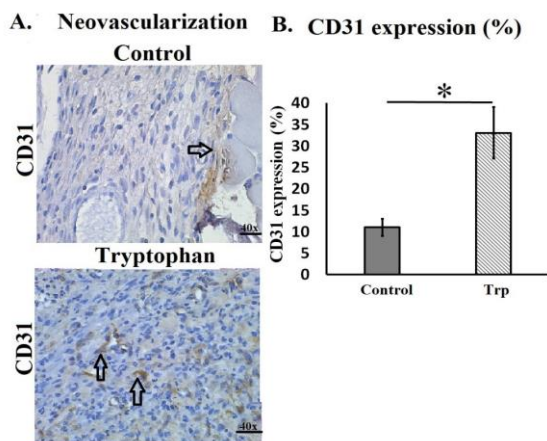


Fig. 5. (A) Immunohistochemical staining CD31+ endothelial cells marker expression during post burn skin wound healing (40x images). (B) CD31+ endothelial cell count was presented as percentage (%) \pm Standard Deviation (S.D), (n=5, *P<0.05, **P<0.01).

Discussion

Role of tryptophan has been established by previous studies in excisional wound healing but hasn't been studied in post burn wound healing. Therefore, this study planned to investigate the role of tryptophan (an essential amino acid) in post burn wound healing process. Post burn experimental evaluation in this study revealed that control mice group showed delayed and poor skin wound healing, exemplified by significantly larger wound size, poor re-epithelization and low cellularity.

Whereas, tryptophan treatment significantly reduced the wound size, improved the re-epithelization process and resulted in better healed wound.

During wound healing process initial series of events consist of formation and thickening of epidermal cover over the exposed wound zone. These series of events start from wound margins adjacent to the wound scab as shown in Fig 1. This thickening appears as a result from an increase in the volume of the epidermal cells adjacent to the wound (Odland and Ross, 1968). At the time of early phase of wound healing cellular proliferation is a vital characteristic feature that is needed to restore that structural components at wound site (Werner and Grose, 2003). Our results indicated that tryptophan also has potential to promote cell growth as its obvious by enhanced fibroblast proliferation in wound dermal area and thickening of newly formed epidermis.

These findings suggest that tryptophan may act as growth enhancer. Findings of this study also supported by previous investigations in which *in vivo* tryptophan fluorescence has been used to induced epidermal proliferation of wound area (Brancaleon *et al.*, 1999; Wang *et al.*, 2015). In this study we used topical cream formulation in postburn wound healing and results showed improved epithelial cover formation over the burn wound area, similar results were obtained in wound epidermal area, when topical tryptophan cream applied in patients having lower limb wound injuries in a study conducted by Barouti *et al* (2015) research group.

Experimental data revealed that tryptophan induced reepithelization process and this result is in accordance with findings of previous study conducted in stressed cutaneous wound mice model (Bandeira *et al.*, 2015). Along with these promising outcomes, the present *in vivo* study has few limitations as we realise that there is need to harvest and analysis all four stages of wound healing process. This will help to investigate further details of underlying healing mechanism of action of Tryptophan.

Conclusion

Tryptophan topical application improves the post burn skin wound healing in mice by promoting re-epithelialization, cell proliferation and neovascularization process.

Acknowledgement

We acknowledge the joint support provided by Attaur-Rahman School of Applied Biosciences (ASAB), National University of Science and Technology (NUST) and Higher Education Commission of Pakistan (HEC).

Conflict of interests

There is no competing interest among the authors of this study.

References

- Ansell DM, Campbell L, Thomason HA, Brass A, Hardman MJ.** 2014. A statistical analysis of murine incisional and excisional acute wound models. *Wound Repair and Regeneration* **22**, 281-287.
- Bandeira LG, Bortolot BS, Cecatto MJ, Monte-Alto-Costa A, Romana-Souza B.** 2015. Exogenous Tryptophan Promotes Cutaneous Wound Healing of Chronically Stressed Mice through Inhibition of TNF- α and IDO Activation. *PLoS ONE* **10**, e0128439.
- Barouti N, Mainetti C, Fontao L, Sorg O.** 2015. L-Tryptophan as a Novel Potential Pharmacological Treatment for Wound Healing via Aryl Hydrocarbon Receptor Activation. *Dermatology* **230**, 332-9.
- Brancaleon L, Gloria L, Nikiforos K.** 1999. The In Vivo Fluorescence of Tryptophan Moieties in Human Skin Increases with UV Exposure and is a Marker for Epidermal Proliferation. *Journal of Investigative Dermatology* **113**, 977-982.
- Celinski K, Konturek PC, Konturek SJ, Slomka M, Cichoz-Lach H, Brzozowski T, Bielanski W.** 2011. Effects of melatonin and tryptophan on healing of gastric and duodenal ulcers with *Helicobacter pylori* infection in humans. *Journal of Physiology and Pharmacology* **62**, 521-526.
- Dawson B, Favaloro EJ.** 2007. High Rate of Deficiency in the Amino Acids Tryptophan and Histidine in People with Wounds: Implication for Nutrient Targeting in Wound Management—A Pilot Study. *Advances in Skin & Wound Care* **22**, 79-82.
- Demidova-Rice TN, Durham JT, Herman IM.** 2011. Wound Healing Angiogenesis: Innovations and Challenges in Acute and Chronic Wound Healing. *Advances in wound care* **1**.
- Lanis JM, Alexeev E, Colgan S.** 2017. Tryptophan Metabolite Activation of the Aryl Hydrocarbon Receptor in Intestinal Epithelia Promotes Mucosal Healing. *The FASEB Journal* **31**.
- Le Floc'h N, Otten W, Merlot E.** 2011. Tryptophan metabolism, from nutrition to potential therapeutic applications. *Amino Acids* **41**, 1195-1205.
- Lerman OZ, Galiano RD, Armour M, Levine JP, Gurtner GC.** 2003. Cellular dysfunction in the diabetic fibroblast: impairment in migration, vascular endothelial growth factor production, and response to hypoxia. *The American Journal of Pathology* **162**, 303-12.
- Lieberman HR.** 2003. Nutrition, brain function and cognitive performance. *Appetite* **40**, 245-254.
- Mani H, Sidhu GS, Kumari R, et al.** 2002. Curcumin differentially regulates TGF-beta1, its receptors and nitric oxide synthase during impaired wound healing. *Biofactors* **16**, 29-43.
- Manzke T, Niebert M, Koch UR, Caley A, Vogelgesang S, Hülsmann S, Ponimaskin E, Müller U, Smart TG, Harvey RJ, Richter DW.** 2010. Serotonin receptor 1A-modulated phosphorylation of glycine receptor alpha3 controls breathing in mice. *Journal of Clinical Investigation* **120**, 4118-28.
- Mori R, Toshikazu K, Toshikazu N, Tohru O, Masahide A.** 2004. Impairment of Skin Wound Healing in β -1,4-Galactosyltransferase-Deficient Mice with Reduced Leukocyte Recruitment. *American Journal of Pathology* **164**.

Nunan R, Harding KG, Martin P. 2014. Clinical challenges of chronic wounds: searching for an optimal animal model to recapitulate their complexity. *Disease Models & Mechanisms* **7**, 1205-1213.

Odland G, Ross R. 1968. Human Wound Repair. *The Journal of Cell Biology* **39**.

Richard DM, Dawes MA, Mathias CW, Acheson A, Hill-Kapturczak N, Dougherty DM. 2009. L-tryptophan: basic metabolic functions, behavioral research and therapeutic indications. *International Journal of Tryptophan Research* **2**, 45-60.

Richter DW, Pierrefiche PMLO, Haji A, Bischoff AM, Wilken B, Hanefeld F. 1997. Intracellular signal pathways controlling respiratory neurons. *Respiration Physiology* **110**, 113-23.

Sandyk R. 1992. L-tryptophan in neuropsychiatric disorders: a review. *International Journal of Neuroscience* **67**, 127-144.

Traskman-Bendz L, Haskett RF, Zis AP. 1986. Neuroendocrine effects of L-tryptophan and dexamethasone. *Psychopharmacology* **89**, 85-88.

Wang Y, Gutierrez-Herrera E, Ortega-Martinez A, Anderson RR, Franco W. 2016. UV fluorescence excitation imaging of healing of wounds in skin: Evaluation of wound closure in organ culture model. *Lasers in Surgery and Medicine* **48**, 678-85.

Weller K, Foitzik K, Paus R, Syska W, Maurer M. 2006. Mast cells are required for normal healing of skin wounds in mice. *The FASEB Journal* **20**, 2366-8.

Werner S, Grose R. 2003. Regulation of wound healing by growth factors and cytokines. *Physiology Reviews* **83**, 835-70.