

ISPUB.com

Search...



# INTERNET SCIENTIFIC PUBLICATIONS

Navigate...



Navigate...



Original Article

## Palpable Breast Lumps: Fine-Needle Aspiration Cytology versus Histopathology: a Correlation of Diagnostic Accuracy

*A Khemka, N Chakrabarti, S Shah, V Patel*

### Keywords

### Citation

A Khemka, N Chakrabarti, S Shah, V Patel. *Palpable Breast Lumps: Fine-Needle Aspiration Cytology versus Histopathology: a Correlation of Diagnostic Accuracy*. The Internet Journal of Surgery. 2008 Volume 18 Number 1.

### Abstract

**Objective:** To study the correlation between diagnostic accuracy of FNAC and histopathology in palpable breast lumps.

**Methods:** A prospective study of 50 patients was conducted at K. J. Somaiya Medical College, Research Center and Hospital, Mumbai. All female patients were randomly selected, irrespective of their age, religion, marital status, occupation or social status. Every patient

underwent a FNAC done on OPD basis by a trained pathologist from the Pathology Department in K. J. Somaiya College, Research Center and Hospital, following a thorough clinical check-up. Every patient subjected to FNAC underwent a definitive surgical procedure. All specimens so obtained were subjected to histopathology. The results thus obtained from histopathology were matched with those of FNAC and a correlation was sought based on statistical tests.

Results: Results of all patients were collected and tabulated. Statistical analysis was performed on the tabulated data and sensitivity and specificity with positive and negative predictive value were obtained. Of all 50 patients selected, only 2 were false negative for malignancy i.e., they were detected as benign lesions on FNAC but found to be malignant on histopathology. Hence, the sensitivity of the study was 96% and the specificity for malignant lesions was 100%. The positive predictive value was 100% and the negative predictive value was 95.12%

Conclusion: FNAC is a cheap, rapid, reliable and accurate test of diagnosing a palpable breast lump if done by an expert and trained pathologist. It gives a good histological correlation. It may obviate the need for another surgical biopsy prior to definitive surgery for malignancy.

---

## **Introduction**

With growing awareness in the general population, especially about breast pathologies, a lady with a breast lump is one of the commonest presentations in outpatient departments. Clinical examination would be followed in most patients with a confirmatory diagnosis under the microscope. Previously, this involved invasive methods, such as an excision biopsy as an inpatient, under anaesthesia, followed by the definitive operative treatment a few days later in case the biopsy report demanded it. The final specimen so obtained would then be sent for histopathology again, for determination of other parameters. This entailed repeated admission to hospital in most cases, and more than one surgery along with its attendant social and physical inconvenience. The delay in procuring the histopathology report was also added to the woes of the patient.

The pioneering work at the Karolinska institute in Stockholm by Torsten Lowhagen and his colleagues, in the 60s and 70s helped to popularize a new minimally invasive technique of diagnosis known as Fine-Needle Aspiration Cytology (FNAC). It is a study of cellular material obtained by a small-gauge needle obtained by

material obtained by a small-gauge needle obtained by an airtight syringe. It is a study commonly used in breast, thyroid, and lymph nodes in neoplastic and non-neoplastic diseases. With help of a radiologist the effectiveness of the study can be maximized. This is a quick-to-perform, easy, out-patient and virtually painless procedure which became a standard tool for diagnosis in breast lumps. With a high percentage of true positives, nearly no false positives and virtually no complications, and no requirement of anaesthesia, it has established itself as an important patient-friendly out-patient procedure.

Though critics have rightly pointed to the possibility of false negative reports in respect to malignant lesions, with improved techniques and expertise, a FNAC reported by an expert cytologist as unequivocally malignant is now considered by most a sufficient evidence to proceed to definitive surgery.

Hence, this study was undertaken to see how well a preliminary FNAC in a breast lump correlated with the final histopathology report to which every excised specimen would invariably be subjected. Apart from reducing patient anxiety in many situations, it could help avoid the diagnostic excision / incisional biopsy in most patients. Patient comfort is an important consideration when they present to a hospital for treatment. With obvious advantages as mentioned, FNAC has been proved to be an important patient-friendly procedure in breast lumps. Therefore, the study aimed to determine the extent to which the FNAC report could be relied upon to proceed towards definitive excisional surgery without resorting to any other diagnostic procedure. For the conclusion that FNAC is indeed reliable, a good positive correlation is essential to be demonstrated between the FNAC and the final histopathology report. To try and to arrive at a conclusion regarding the reliability of FNAC has been the essence of this study.

## **Aims and Objectives**

Breast carcinoma is a common malignancy in urban women, the second leading cause of cancer-related death and the third most common cancer throughout the world. Its incidence is rising in the world due to widespread awareness, and better diagnostic aids to detect the lesion at an early stage.

The most common presentation is a breast lump, and worldwide, the most accepted protocol followed for diagnosis of breast lumps, is "Triple Assessment", which includes clinical assessment, radiological imaging and pathological diagnosis.

Since FNAC forms the most important aspect of

cytopathology as a part of triple assessment, it is expected to be an efficient technique which can be relied upon in terms of avoiding further diagnostic surgery before proceeding with the final definitive excisional procedure. To evaluate the correlation between accuracy of FNAC and histopathology in palpable breast lumps is the primary aim of our study.

The aims and objectives of our study therefore were:

1. To subject all patients in our study, presenting with a palpable breast lump in this general hospital, to Fine-Needle Aspiration Cytology on an outpatient basis.
2. To admit the patient for the required definitive excisional surgery and send the specimen for histopathology in all patients.
3. To compare the FNAC report with the final histopathology report of the excised specimen in all patients.
4. To derive conclusions about the correlation, including sensitivity, specificity, positive and negative predictive values, regarding the diagnostic accuracy of FNAC as compared to the final histopathology.

## **Materials and Methods**

The materials used in our prospective type of study were as follows:

Eligibility criteria for patients: Fifty female patients attending the surgical outpatient department of our hospital were selected keeping in mind the criteria mentioned below.

### **A. Inclusion Criteria**

- a. Age between 10 and 70 years
- b. Palpable breast lump of variable duration

### **B. Exclusion Criteria**

- a. Patient not willing (written informed consent taken)
- b. Frank malignant mass with skin infiltration

## **Equipment:**

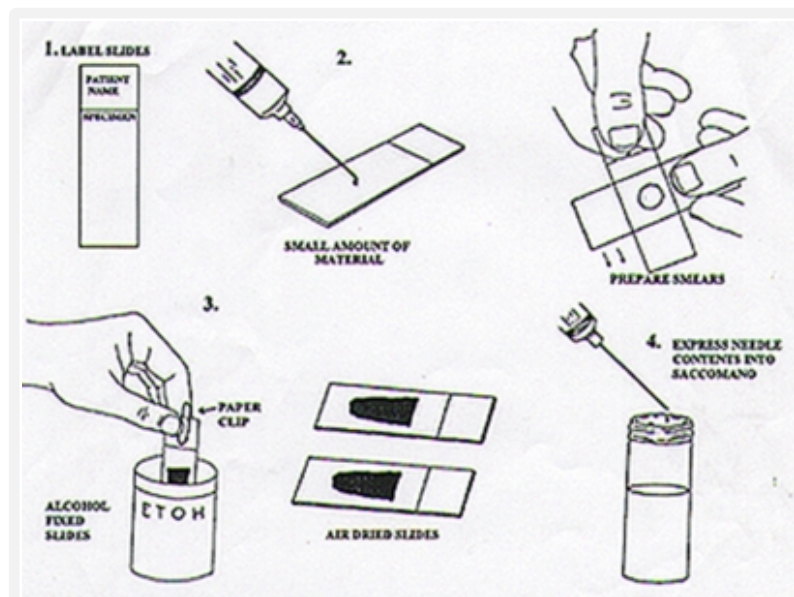
1. Needles: Fine-gauge number 23 single-use disposable needles were used in the study in all patients as a strict protocol.
2. Syringes: Regular 10 cc single-use disposable plastic Becton Dickenson syringes were used for aspirating the material from the breast lumps.
3. Slides: Two to three dry clean slides were used for preparing the smears. All slides were labelled with a glass pencil and air-dried.
4. Fixatives: As routine, all smears were fixed with 95% alcohol.
5. Stains: All the slides were stained with eosin and heamotoxyline stain. Special stains if required were used in those particular cases.

## Technique

### Patient preparation

After taking an informed valid written consent, the patient was explained the procedure in complete detail. The patient was always accompanied with a female attendant. The procedure was performed without any anaesthesia by a trained cytologist in the pathology department.

**Figure 1**



The skin over the suspicious area was cleaned with spirit, the lump was held by hand and stabilized. With the plunger retracted, many passes were made in the

lump till sufficient material was seen in the needle hub. Air was aspirated in the syringe and after attaching the needle again the aspirated material was sprayed on the glass and smears were made.

The smear was fixed with 95% alcohol and later stained with hematoxylin and eosin stain. The slides were then observed under microscope and graded accordingly.

Cytology Reports were interpreted as benign, malignant, suspicious pathology and unsatisfactory.

## Results

All the 50 patients underwent a diagnostic FNAC in our pathology department following which all underwent a definitive excisional surgical procedure after admission to hospital. All excised specimens obtained were subjected to histopathology. The FNAC report was correlated with the final histopathology report and statistical tests were used to interpret the results.

The observations and results of our study were tabulated and analyzed as below:

### Figure 2

Table 1: Age Distribution of Cases

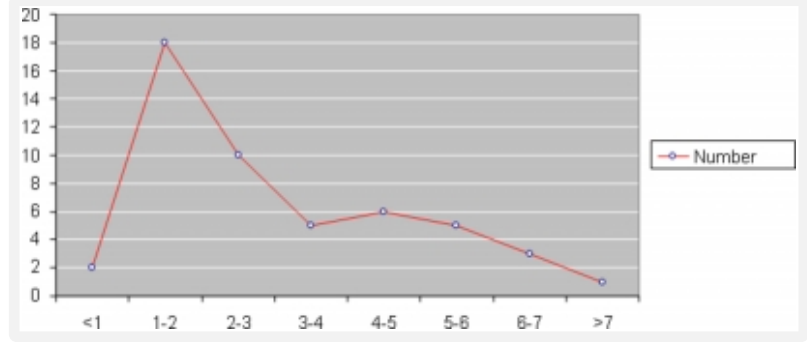
Age (years)	No.
10-14	1
15-19	7
20-24	6
25-29	7
30-34	8
35-39	4
40-44	9
45-49	3
50-54	2
55-59	-
60-64	3

The maximum number of women was in the age group of 40-44 years, followed by 30-34 years. There were no women in the age group of 55-59 and only one in the group of 10-14 years.

### Figure 3

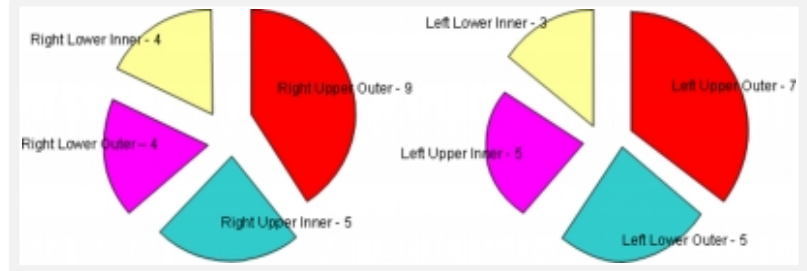
Figure 3: Duration of Illness (months)

Figure 1: Duration of illness (months)



**Figure 4**

Figure 2: Clinical Location of Breast Lumps



Hence, in this study, the patients' total number of lumps palpated in the right side was 22. The number of lumps palpated in the left breast was 28. The maximum number of lumps in one particular quadrant was in the upper and outer quadrant on the right side and they were 9 in number; on the left side, the upper and outer quadrant was the quadrant which had the maximum number of lumps palpated, too: they were 7. So without considering sides, the quadrant in which there was the maximum number of palpable lumps was the upper and outer quadrant.

**Figure 5**

Table 2: Age Distribution of Women with Benign Breast Disease on Histology

Age (years)	No.
10-14	1
15-19	7
20-24	6
25-29	7
30-34	8
35-39	2
40-44	3
45-49	1
50-54	1
55-59	-
60-64	1

The above table depicts the age distribution of women suffering from benign breast diseases on histology. The maximum number is seen in the age group of 30-34.

**Figure 6**

Table 3: Age Distribution of Women with Malignant Breast Disease on Histology

Age (years)	No.
10-14	-
15-19	-
20-24	-
25-29	-
30-34	-
35-39	2
40-44	5
45-49	2
50-54	2
55-59	-
60-64	2

This above table depicts the age distribution among women in our study who were detected with malignancy on histology. It shows that during the period of our study, among 13 women who were detected with malignancy, the maximum, that was 5, was present in the age group of 41-44.

In our study of fifty women, on FNAC, we found 29 women with a fibroadenoma, and one specimen was reported as phylloides tumor while 11 were reported as malignant. There was 1 patient with atypical hyperplasia, 1 with a retention cyst, and there were 2 with suppurative infection. The remaining 5 had a benign proliferative breast disorder (BPPD) as shown in Table 4a. The same women's histopathology reports were as follows: 29 women were detected with fibroadenoma, 4 had fibrocystic disease, there was 1 retention cyst and 1 phylloides tumor and there were 2 chronic abscesses and 13 malignancies detected as shown in Table 4b.

**Figure 7**

Table 4a&b

No.	FNAC	NUMBER	No.	HISTOPATHOLOGY	NUMBER
1	Fibroadenoma	29	1	Fibroadenoma	29
2	BPPD	5	2	Ductal carcinoma	13



3	Phylloides Tumor	1	3	Phylloides Tumor	1
4	Retention cyst	2	4	Retention cyst	1
5	Atypical hyperplasia	1	5	Fibrocystic disease	4
6	Suppurative infection	1	6	Chronic abscess	2
7	Ductal carcinoma	11			

The statistical tests used in the interpretation of the results obtained in our study were the determination of:

Sensitivity of FNAC as a diagnostic procedure for the entire study

Specificity of FNAC in relation to the malignant lesions

Positive predictive value of FNAC as a diagnostic procedure for the entire study

Negative predictive value in relation to the malignant lesions

In our study, of the 50 patients who underwent FNAC, in 48 the FNAC report matched with the final histopathology report.

### Figure 8

Table 5

FNAC / Histopathology correlation	Diseased	Not diseased
Positive	48	-
Negative	2	-
Total	50	

Out of the 2 patients, in which FNAC did not match, one showed a benign proliferative breast disorder and the other showed atypical hyperplasia on FNAC. An excision biopsy of the lump was performed in both patients and both showed duct carcinoma. (They then underwent further surgery in the form of a modified radical mastectomy).

Thus there were 48 true positives, 2 false negatives and no false positives and true negatives in our study.

The sensitivity of a test is the ability of a test to identify correctly all those who have the disease. In our study the sensitivity would be:

### Figure 9

$$\bullet \text{ Sensitivity} = \frac{\text{True positives}}{\text{True positives} + \text{false negatives}} \times 100 = \frac{48}{48+2} \times 100 = 96\%$$

The specificity of a test is the ability of the study to identify correctly the candidates who do not have the disease.

### Figure 10

$$\bullet \quad \text{Specificity} = \frac{\text{True negative}}{\text{True negative} + \text{false positive}} \times 100$$

In our study, only females with a lump in their breast were selected. Therefore, in purely statistical terms, there were no normal individuals i.e., those women with normal breasts were not selected. Hence, the ability of Fine-Needle Aspiration Cytology as a diagnostic test to identify correctly those individuals not having disease (i.e., true negatives) could not be calculated since in every patient in our study, FNAC would reveal some result.

Hence, to give a wider spectrum to our interpretation of the results, we calculated the specificity of FNAC for malignant lesions against benign lesions i.e., “how specific is FNAC as a test in the diagnosis of malignancy in a breast lump?”

### Figure 11

Table 6

Biopsy \ FNAC	Malignant	Non - Malignant	Total
Malignant	09	00	09
Non - Malignant	02	39	41
Total	11	39	50

So according to this table, in our study, the specificity of FNAC for malignancy would be calculated as:

### Figure 12

$$\text{Specificity} = \frac{39}{39+0} \times 100 = 100\%$$

The positive predictive value of a test indicates the probability that the patient with a positive test has, in fact, the disease in question.

### Figure 13

$$\text{Positive predictive value} = \frac{\text{True positives}}{\text{True positives} + \text{false positive}} \times 100$$

$$\text{Positive predictive value for FNAC} = \frac{48}{48+0} \times 100 = 100\%$$

It should be noted that this positive predictive value is for FNAC as a diagnostic test for all patients.

The negative predictive value of a test indicates the probability of a patient with a negative test not having the disease in question.

#### Figure 14

$$\text{Negative predictive value} = \frac{\text{True negative}}{\text{True negative} + \text{False negative}} \times 100$$

As stated above in our results, we had no true negatives. In the absence of true negatives, the predictive value of negative test is actually zero, since the numerator becomes zero. As with the calculation of specificity for malignant lesions, we broadened the interpretation of our results by calculating the negative predictive value of the test for malignant lesions.

#### Figure 15

$$\text{Thus, negative predictive value} = \frac{39}{39+2} \times 100 = \frac{39}{41} \times 100 = 95.12\%$$

### Discussion

A lump in the breast is a common complaint presenting in the surgical out-patient department of all major hospitals, with anxiety regarding a possible malignancy being extremely common. Hence a quick diagnosis of a lump in the breast is essential. Criteria such as cost effectiveness, use of anaesthesia, time between the diagnostic procedure and report, patients' hospital stay and most importantly, reliability in deciding subsequent treatment, are all factors to be taken into account in this regard. Considering patients' comfort, lack of requirement of anaesthesia, rapid analysis and reporting, and an absence of false positive results makes FNAC an ideal initial diagnostic modality in breast lumps. The expansion of FNAC in the primary diagnosis of cancer in the last 30 years has been enormous and hugely successful. Its use in detecting the presence of cancer before surgery and as a guide to rational treatment has been well documented. Countries with most developed aspiration biopsy techniques are Sweden, Slovenia, the USA and India. At Karolinska hospital (Stockholm, Sweden), FNACs average 11,000 annually and at the Institute of Oncology Ljubljana, Slovenia 10,000. In the USA, the highest number is encountered at M. D. Anderson at Houston, Texas with 7,000 aspirates every year. At All India Institute of

7,000 aspirates every year. <sup>1</sup> At All India Institute of Medical Sciences (AIIMS) the annual volume of cytology specimens is more than 15,000, with FNACs comprising roughly half of the aspirations <sup>1</sup> .

Our present study was conducted on 50 female patients with a palpable breast lump each of whom underwent a fine-needle aspiration cytology of the lump followed by excisional surgery either in the form of a lumpectomy or a definitive surgical procedure like a mastectomy, depending on the diagnosis at aspiration cytology. The aspiration cytology findings were then matched with the final histology report to see as to how accurate FNAC was as compared to open biopsy i.e., to assess the cyto-histologic correlation. None of our patients was subjected to a core biopsy and its correlation with FNAC was not a part of our study. Our study also did not attempt to draw any conclusions as to whether one diagnostic modality could replace the other.

Patients were selected regardless of their religion, occupation and financial status. All these patients underwent an FNAC and patients who did not follow up after FNAC were not included in this study. Every patient included in this study was admitted and underwent a definitive surgical procedure as demanded by the FNAC report. It varied from excision biopsy or incision and drainage to a modified radical mastectomy.

The procedure of FNAC was performed by trained personnel in the pathology department following a uniform protocol. All pathology specimens underwent a histopathological study, the final report was compared with that of FNAC and the correlation was sought. The results obtained were tabulated and conclusions drawn based on statistical tests. Though many aspects relating to the patient profile were tabulated and compared with those in other similar studies, the most important aspect of this study was to draw conclusions regarding the cytohistological correlation in these patients.

In the fifty consecutive women selected for our study, the age ranged from fourteen years to sixty-one years with an average of thirty-seven and a half years. The maximum (nine patients) was found in the forty to forty-four year group followed by eight patients in the thirty to thirty-four year group. We found that there were no patients before the age of thirty-five to thirty-nine who were detected with malignancy, with the maximum number of patients seen in the forty to forty-four age group. Whereas benign lesions were seen in patients of all age groups, they were more commonly seen in younger age groups with the maximum of eight patients in the thirty to thirty-four age group.

In a similar study done by Hussain <sup>26</sup> on 50 patients, the

In a similar study done by Hussain 36 on 50 patients, the age distribution was between fifteen and sixty-five years and the maximum patients were seen in the thirty one to forty year group (30%). Similar studies done by Homesh 62 et al., Tiwari 80 and Ariga et al. 75 showed similar age patterns.

In our study, the right breast was involved in 22 patients while the left breast was involved in twenty-eight patients. Bilateral involvement was seen in six patients. In their series, Hussain et al. 36 showed left breast involvement in 27 patients (54%) while in the other 23, the right breast was involved. No surgical importance can be attached to this observation since patient selection was in no way dictated by involvement of any particular breast.

The upper and outer quadrant was the commonest site of the lump in our patients (22 patients) while the upper inner quadrant was involved in 10, the lower and outer in 9 and the lower and inner quadrant in 9. Hussain 36, in his series, had 29 patients (58%) with a lump in the upper and outer quadrant and 9 had a lump in the upper and inner quadrant while 4 patients had a palpable lump in the lower and outer quadrant. There were 5 and 3 patients having a lump in the lower inner and central quadrant, respectively. Both studies showed the upper and outer quadrant to be the dominant quadrant to have a palpable lump.

Thirty-seven out of our fifty patients were married. This corresponds to 74% of patients in comparison to 69.3% of 296 patients who were married in the series by Homesh et al. 62 Thus, in both series more married women presented to the out-patient department than unmarried ones. Though not directly related to our study, these figures may indicate the relative reluctance of young unmarried women to present to the out-patients department for a breast examination, since benign breast lumps, especially variants of ANDI (Aberrations of Normal Development and Involution), are definitely not uncommon in the young unmarried patient. Also only 7 of our married patients were nulliparous and all those who had children had breastfed their babies.

In our patients, the duration of the lump ranged from 2 months in 18 patients to 7 months in 3 patients. All the others reported duration in between 2 and 7 months as shown in Table 2. In comparison, the study by Hussain 36 showed the duration of the lumps in a range between 1 month to 2 years with a majority of patients having a history of between 6 months and a year. Earlier presentation in case of our patients was probably due to the location of our hospital in a metropolitan city with a large urban population quite aware of the importance of

large urban population quite aware of the importance of a breast lump and the necessity of a medical consultation if one happened to develop a lump. This is definitely a reflection of the increased awareness regarding breast lumps amongst the female population.

The commonest pathology found in our patients was fibroadenoma in 29 patients. This was followed by fibrocystic disease in 4 patients and malignancy in 13 patients. In their study on 91 patients, Tiwari et al. 80 also reported fibroadenoma as the commonest pathology (39.6%). Other important conditions such as subareolar abscess, invasive ductal cancer, breast abscess, fibrocystic disease, duct ectasia, and galactocoele ranged from 5.5% to 7.7%.

Size of the needle used for FNAC has often been a point for discussion since patient comfort and patient friendliness is an important aspect of FNAC as a superior diagnostic procedure. Disadvantages of a finer needle were an inadequate aspirate while disadvantages of a thicker needle included pain and hematoma formation. All our patients underwent FNAC using a no. 23 needle with no patient discomfort and none of the patients complained of any untoward side effects. Walker et al. 22 compared the use of 21G and 23G needles for FNAC in breast lumps; 125 patients were included; 61 and 64 patients underwent FNAC with a 21G and 23G needle, respectively. A chi squared test had showed no statistical difference in the results whichever needle was used in their study.

Expertise of the person performing and interpreting the fine-needle aspiration often influences results. Yeoh et al. 73 from Hong Kong reported a high proportion of unsatisfactory samples (48%) with doctors who performed FNAC occasionally. Patel et al. 37 showed that FNAC results were influenced by the number of needle manoeuvres performed with less than ten needle manoeuvres being associated with a 54% unsatisfactory aspiration rate, as compared to 25% when more than ten manoeuvres were performed. They concluded that experience and technique are the most important factors in obtaining a satisfactory aspirate from breast lumps. Padel et al. 81 showed that sensitivity of FNAC increased and inadequate samples decreased when pathologists took the samples for cytodiagnosis. Cohen et al. 82 and Ljung et al. 32 also reported on the influence of training and experience in aspiration cytology of the breast with a maximum influence on sensitivity values which dropped sharply from 98.2% to 75% with an untrained person performing the aspiration, as seen in table 7.

Figure 10  
Table 7

Measurements	Formally trained	Not formally trained
Sensitivity(95%CI),%	98.2(88.8-99.9)	75.0(60.1-85.9)
Spedficity(95%CI),%	91.4(89.0-93.8)	88.8(83.1-94.5)
Positive predictive value(95% CI), %	54(44.2-63.8)	74(61.8-86.2)
Positive likelihood ratio	11.4	6.8
Malignant	$\alpha$	$\alpha$
Atypical/suspicious	2.6	5.2
Non-diagnostic	0	0.27
Negative likelihood ratio		
Benign	0.02	0.28

(Adapted from Ljung et al.<sup>32</sup>)

In our patients, FNAC was always performed by pathologists with at least five years of experience in FNAC which they were performing routinely not only from the breast but from other organs, too.

Image guidance during FNAC is another important aspect of various studies. Increased accuracy is the obvious advantage especially in the smaller, deeper or impalpable lesions. Sonographic and stereotactic guidance have been the most commonly used modalities. Numerous studies highlighting this aspect have been done. However, since we included only palpable breast lumps in our study, no image guidance was required in any patient.

As mentioned above, the primary aim of our study was to determine diagnostic correlation between fine needle aspiration cytology report and the final histopathology of the lump. In other words, how accurate and reliable was FNAC in diagnosing breast pathology which could help us in proceeding towards definitive excisional (and often mutilating) surgery without having an unpleasant surprise at the final histology report of the specimen. For centuries, conventional histology has remained the cornerstone of diagnostic pathology and was often described quite rightly as 'the final court of appeal' in the presence of controversy. The obvious advantages of FNAC are in form of a rapid and cost effective, out-patient's procedure, not requiring anaesthesia, which can be easily repeated without much pain or discomfort to the patient. Occasional complications include the formation of a hematoma or post procedure pain and rare chance of tumour seeding along the needle tract. With needles used now being quite fine, this chance is even less likely. However, there are a few limitations in terms of its inability to diagnose lesions if the aspirate is scanty either due to an inexperienced operator or a very small or deep lesion. More needle manoeuvres are required in some patients and it may be difficult to diagnose unusual tumours. Being a cytological study

diagnose ductal tumours. Being a cytological study, classification and grading is not possible. Diagnosis is also impossible if the aspirate is from the centre of a necrotic tumour.

In relation to breast pathologies there are obvious advantages (apart from the more general ones) in the form of very few false positives in differentiating between benign and malignant lesions, as well as of being diagnostic and therapeutic in most breast cysts. Recurrence of carcinoma of the breast, too, can often be diagnosed. The conditions which have a risk of a false positive result are papillary lesions, atypical epithelial hyperplasia, regenerating epithelial atypia, and atypia of ductal epithelium in a cyst.

A risk of false negative results exists in low grade malignancies, small or complex proliferative lesions as well as in tumours with central necrosis or a small cell carcinoma. Silverman et al. 63 concluded that for palpable lesions, FNAC, as compared to core biopsy, appears to have more predictive value in confirming the diagnosis of carcinoma and locally recurrent disease.

The sensitivity of a particular test is a statistical index of the diagnostic accuracy of that particular test. In the context of FNAC, it implies that if FNAC is positive, it definitely means presence of the disease but if it is negative, it does not rule out the disease. The specificity of a particular test, on the other hand, is the ability of the test to identify those individuals who do not have the disease. In purely statistical terms, there were no normal individuals in our study, i.e. women without a breast lump. Hence, the ability of Fine-Needle Aspiration Cytology as a diagnostic test to identify correctly those individuals not having disease (i.e., true negatives) could not be noted since in every patient in our study FNAC would reveal some result. Therefore, specificity of FNAC as a whole could not be calculated. To give a wider spectrum to our interpretation of the results, we calculated the specificity of FNAC as a diagnostic test for malignant lesions, i.e. how specific is FNAC as test in the diagnosis of malignancy in a breast lump? The positive predictive value of a test indicates the probability of a patient with a positive result to have the disease. Hence, it shows the diagnostic power of the test while the negative predictive value of a test, on the other hand, indicates the probability of a patient with negative result not to have the disease. As stated in our results, we had no true negatives. In the absence of true negatives, the predictive value of the negative test is actually zero, since the numerator becomes zero. As with the calculation of specificity for malignant lesions, we broadened the interpretation of our results by calculating the negative predictive value of the test for malignant lesions. This concept has already been



malignant lesions. This aspect has already been explained the results.

In our study, there were 48 true positives, no false negatives, no true negatives and 2 false positives. As shown previously, sensitivity and positive predictive value of FNAC in our study were calculated as 96% and 100%, respectively, while specificity and negative predictive value for malignancy were 100% and 95.12%, respectively.

While the value of sensitivity of FNAC in our study was 96%, an absolute value of 90.9% was obtained by the series by Hussain et al. 36 In a series of 100 patients, Dennison 58 reported the sensitivity of FNAC as 90.4% whereas Wu et al. 61 compared postoperative pathology results and showed a sensitivity of 75% for FNAC, while trucut biopsy showed a sensitivity value of 92% and frozen section 100%. Westend et al. 53 depicted a value of 92% for FNAC which was slightly lower than our findings.

As already discussed above, the positive and negative predictive value of a test are the ones which measure the performance of a test by measuring its “predictive value” which reflects the diagnostic power of the test. They depend upon the sensitivity, specificity and disease prevalence. In this regard, Franco et al. 35 , in his study of 300 patients on the utility of FNAC, reported a positive predictive value of 100% and a negative predictive value of 92%. A very large study of 1,297 patients done by Choi et al. 83 , on correlation of FNAC and histopathology reports, found the positive predictive value to be 98.4% and a negative predictive value of 88%. In this context, the following table showing the values obtained in several similar studies is relevant.

**Figure 17**

Table 8

Name of study	Sensitivity	Specificity	Positive Predictive value	Negative Predictive value
Ishikawa et al. <sup>23</sup>	86.3%	98.2%	97.9%	-
Watson et al. <sup>5</sup>	74%	96%	98%	-
Choi et al. <sup>83</sup>	77.7%	99.2%	98.4%	88%
Medina et al. <sup>25</sup>	82.6%	-	100%	92%
Jayaram et al. <sup>67</sup>	97.4%	92.4%	-	-
Yeoh et al. <sup>73</sup>	79%	98%	92%	94%
Ariga et al. <sup>25</sup>	99%	99%	99%	99%
Ariga II et al. <sup>25</sup>	98%	97%	99%	86%
Ahmed et al. <sup>26</sup>	85.29%	100%	100%	98.79%
Hussain <sup>36</sup>	90.9%	100%	-	-
Muhammed et al. <sup>73</sup>	90.6%	100%	100%	99%
Florentine et al. <sup>79</sup>	-	-	100%	99%
Tiwari et al. <sup>80</sup>	83%	100%	-	-
Somers et al. <sup>4</sup>	78%	100%	100%	-
Rubin et al. <sup>89</sup>	87%	100%	100%	89%

It can be seen clearly that our results match well with

It can be seen clearly that our results match well with those of previous studies reported in the literature. While attempting to find the reason for variation in the values in some of the studies, we felt that the commonest cause was probably related to expertise of the person doing the aspiration. Maximum variations in terms of lower values were in the sensitivity. With the procedure of performing FNAC fairly standardized by now in all institutions, the only important variable remains the person doing the actual aspiration. In such a scenario the procedure itself should not be maligned and a plethora of studies done on this aspect bear testimony to the fact that this factor is being considered, when such studies are interpreted and reported. In our study, the consistently high values of all the parameters was most likely due to the fact that, as mentioned before, only pathologists with at least five years of experience were performing the aspiration. In this way, a major obstacle in getting better results is removed and better cyto-histologic correlation is obtained.

## Conclusions

Fine-needle aspiration cytology is a patient friendly, easy, reliable, repeatable and simple diagnostic test. When performed by an expert pathologist, the diagnostic accuracy of FNAC is very high. A high sensitivity and a high positive predictive value proved that a positive FNAC in the breast means a definite diagnosis of the concerned pathology if compared with the final histology report. The high specificity and a high negative predictive value for malignancy illustrated the high accuracy of FNAC in the diagnosis of malignancy in the breast. Very importantly, a report negative for malignancy was highly accurate (>92%) in predicting an absence of malignancy. Thus, we have no hesitation in concluding that FNAC is a very important preliminary diagnostic test in palpable breast lumps, and done by expert hands, the results show a high degree of correlation with the final histopathology report.

---

## References

1. Amrish Kambhoj, Investigating a lump for suspected cancer: fine needle aspiration cytology by AIIMS, 2007.
2. Ansari NA, Derias NW. Fine needle aspiration cytology. *J Clin Pathol* 1997; 50: 541-543.
3. Martin H, Ellis E. Biopsy by needle puncture and aspiration. *Ann Surg* 1930; 92: 169-181.
4. Somers RJ, Young KP, Kaplan MT, Bernhard UM, Rosenberg M, Somers D. Fine Needle Aspiration biopsy in management of solid breast tumors. *Am J Surg* 1985; 120: 673-7.
5. Watson DP, McGuire M, Nicholson F, Given HF. Aspiration cytology and its relevance in diagnosis of solid breast tumors. *Surg Gynecol Obstet* 1987; 165: 435-41.
6. Ciatto S, Cariaggi P, Bulgaresi P, Confortini M, Bondari R. Fine needle aspiration cytology of breast; review of 9533 consecutive cases. *The Breast* 1993; 2:

- Review of 6333 consecutive cases. *The Breast* 1999; 2: 87-90.
7. Dixon J M, Clarke P J, Crucoli V, Dehn T C, Lee E C, Greenall M J. Reduction of the surgical excision rate in benign breast disease using fine needle aspiration cytology with immediate reporting. *Br J Surg* 1987; 74: 1014-6.
  8. Hitchcock A, Hunt CM, Locker A, Koslowski J, Strudwick S, Elston CW. A one year audit of fine needle aspiration cytology for the pre-operative diagnosis of breast disease. *Cytopathology* 1991; 2: 167-76.
  9. Horgan PG, Waldron D, Mooney E, O'Brien D, McGuire M, Given HF. The role of aspiration cytology examination in the diagnosis of carcinoma of the breast. *Surg Gynecol Obstet* 1991; 172: 290-2.
  10. Khan AU, Muhammad G. Fine needle aspiration cytology in the diagnosis of breast masses. *J Coll Physicians Surg Pak* 1994; 4: 98-101.
  11. Zuk JA, Maudslay G, Zakhour HD. Rapid reporting of fine needle aspiration of breast lumps in our patients. *J Clin Pathol* 1989; 42: 906-11.
  12. Layfield LJ, Glasgow B J, Cramer H. Fine needle aspiration in management of breast masses. *Pathol Annu* 1989; 24: 23-62.
  13. Bates AT, Bates T, Hastrich DJ, Mackie ME, Padley SJ, Cornfield NS. Delay in diagnosis of breast cancer; the effect of the introduction of fine needle aspiration cytology to breast clinic. *Eur J Surg Oncol* 1992; 18: 433-7.
  14. Giard RW, Hermans J. The value of aspiration cytologic examination of breast. A statistical review of medical literature. *Cancer* 1992; 69: 2104-10.
  15. Dusenbery D, Frable WJ. Fine needle aspiration cytology of phylloides tumor, potential diagnostic pitfalls. *Acta Cytol* 1992; 36: 215-21.
  16. Ciatto S, Carriagi P, Bulgaresi P, Confortini M, Bonardi R. Fine needle aspiration cytology of the breast; review of 9533 consecutive cases. *The Breast* 1993; 2: 87-90.
  17. Ciatto S, Bonardi R, Carriagi MP. Performance of fine needle aspiration cytology of breast; a multi-center study of 23,063 aspirates in ten Italian laboratories. *Tumori* 1995; 81: 13-17.
  18. The uniform approach to breast fine needle aspiration biopsy. National Cancer Institute Fine Needle Aspiration of Breast Workshop Subcommittees. *Diagn Cytopathol* 1997; 16: 295-311.
  19. Rubin J, Horiuchi K, Joy N, Haun W, Read R, Ratzer E, Fenoglio M. Use of FNAC for solid breast lesions is accurate and cost effective. *Am J Surg* 1997; 174: 694-6.
  20. Hindle WH, Chen EC. Accuracy of mammography appearances after fine needle aspiration. *Am J Obstet Gynecol* 1997; 176: 1286-90.
  21. Dominguez F, Riera JR, Tojo S, Junco P. Fine needle aspiration of breast masses. An analysis of 1,398 patients in a community hospital. *Acta Cytol* 1997; 41: 341-7.
  22. Walker SR. A randomized trial comparing a 21G needle with a 23G needle for fine needle aspiration of breast lumps. *J R Coll Edinb* 1998; 4: 322-23.
  23. Pissano ED, Fajardo LL, Caudry DJ, Sneige N, Frable WJ, Berg WA. Fine needle aspiration biopsy of non-palpable breast lesions in a multicenter clinical trial: results from the radiologic diagnostic oncology group V. *Radiology* 2001; 219: 785-92.
  24. Carriagi NP, Bulgaresi P, Confortini M, Bonardi R, Maddau C, Matucci N. Analysis of the causes of false negative cytology reports on breast cancer fine needle aspirates. *Cytopathology* 1995; 6: 156-61.
  25. Willis SL, Ramzy L. Analysis of false results of 835 fine needle aspirates of breast lesions. *Acta Cytol* 1995; 39: 858-64.
  26. Painter RW, Clark WE. Negative findings of fine needle aspiration biopsy of solid breast masses: patient management. *Am J Surg* 1998; 155: 387-90.
  27. Lee HC, Ooi PJ, Poh WT, Wong CY. Impact of inadequate fine needle aspiration cytology on the outcome of patients with palpable breast lesions. *N Z J Surg* 2000; 70: 656-9.
  28. Ishikawa T, Hamaguchi Y, Tanabe M, Momiyama N, Chishima J, Nakatani Y, Nozawa A, Sasaki T, Kitamura

- H, Shimada H. False positive and false negative cases of fine needle aspiration cytology for breast lesions. *Breast Carcinoma* 2007; 14: 388-92.
29. Litherland JC. Should fine needle aspiration cytology in breast assessment be abandoned? *Clin Radiol* 2002; 57: 81-4.
30. Tabbara SO, Frost AR, Stoler MH, Sniege N, Sidawy MK. Changing trends in breast fine needle aspiration: results of the Papanicolaou Society of Cytopathologist Survey. *Diag Cytopathol* 2000; 22: 126-30.
31. Swiatecka J, Laudanski P, Dzieciol J. The role of needle biopsy in the diagnosis of breast lesions. *Breast J* 2001; 10: 383-7.
32. Ljung BM, Drejet A, Chiampi N, Jeffrey J, Goodson WH 3rd, Chew K. Diagnostic accuracy of fine needle aspiration biopsy is determined by physician training in sampling technique. *Cancer* 2001; 93: 263-8.
33. Chaiwun B, Settakorn J, Ya-In C, Wisedmongkol W, Rangdaeng S, Thorner P. Effectiveness of fine needle aspiration cytology of breast analysis of 2,375 cases from northern Thailand. *Diagn Cytopathol* 2002; 26: 201-5.
34. Das DK. Fine needle aspiration cytology: its origin, development, and present status with special reference to a developing country India. *Diag Cytopathol* 2003; 28: 345-51.
35. Medina Franco H, Abara Perez L. Fine needle aspiration biopsy - institutional experience. *Zubiran* 2005; 57: 394-8.
36. Hussain MT. Comparison of fine needle aspiration cytology with excision biopsy of breast lump. *J Coll Physicians Surg Pak* 2005; 15(4): 211-214.
37. Patel JJ, Gartell PC, Guyer APB, Herbert A, Taylor I. Use of ultrasound localization to improve results of fine needle aspiration cytology of breast masses. *J R Soc Med* 1988; 81: 10-12.
38. Ciatto S, Rosselli Del Turco M, Ambrogetti D, Bravetti P, Catrzi S, Moorrone D. Solid nonpalpable breast lesions. Success and failure of guided fine needle aspiration cytology in a consecutive series of 2444 cases. *Acta Radiol* 1997; 38: 815-20.
39. Laws SA, McNamara IR, Cheetham JE, Rainsbury RM. Fine needle aspiration cytology prior to breast ultrasonography does not alter ultrasound diagnostic accuracy or patient management. *Breast J* 2002; 11: 320-3.
40. Martelli G, Pilotti S, Coopmans de, Yoldi G. Diagnostic efficiency of physical examination, mammography, fine needle aspiration cytology (triple test) in solid breast lumps: an analysis of 1708 consecutive cases. *Tumori* 1990; 76: 476-479.
41. Markowitz S, Markowitz R, Chaff RA, Lacerate MN. TRU-CUT needle biopsy of breast: An analysis of its specificity and sensitivity. *Cancer* 1986; 57: 320-3.
42. Parker SH, Burbank F, Jackman RJ, Aucreman CJ, Cardenosa G, Cink TM. Percutaneous large core breast biopsy; a multi-institutional study. *Radiology* 1994; 193: 359-64.
43. Dahlstorm J E, Jain S, Sutton T, Sutton S. Diagnostic accuracy of stereotactic core biopsy in a mammographic breast cancer screening programme. *Histopathology* 1996; 28: 421-7.
44. Ballo MS, Sneige N. Can core biopsy replace fine-needle aspiration cytology in the diagnosis of palpable breast carcinoma: A comparative study of 124 women. *Cancer* 1996; 78: 773-7.
45. Pijnappel RM, van Dalen A, Rinkes IH, van Den Tweel JG, Mali WP. The diagnostic accuracy of core biopsy in palpable and non palpable breast lesions. *Eur J Radiol* 1997; 24: 120-3.
46. Lifrange E, Kridelka F, Colin C. Stereotactic needle core biopsy and fine needle aspiration biopsy in the diagnosis of nonpalpable breast lesions: controversies and future prospects. *Eur J Radiol* 1997; 24: 39-47.
47. Andreu FJ, Sentis M, Castener E, Gallarado X, Jurado I, Diaz-Ruiz MJ. The impact of stereotactic large core needle biopsy in treatment of patients with nonpalpable breast lesions; a study of diagnostic accuracy in 510 consecutive cases. *Eur Radiol* 1998; 8: 1468-74.
48. Jackman RJ, Nowels KW, Rodrigues-Soto J, Marizoni EA, Jr, Finkelstein SI, Shephard MJ

Maniotti PA J, Finkelshtien SI, Shephard MJ. Stereotactic, automated, large-core needle biopsy of non-palpable breast lesions; false negatives and histologic underestimation rates after long term follow-up. *Radiology* 1999; 210: 799-805.

49. Liberman L, Feng TL, Dershaw DD, Morris EA, Abramson AF. US- guided core breast biopsy; use and cost effectiveness. *Radiology* 1998; 288: 717-23.

50. Liefland K, Lagersteadt U, Svans G. Comparison of stereotactic fine needle aspiration cytology and core biopsy in 522 non palpable breast lesions. *Acta Radiol* 2003; 44: 387-91.

51. Gundry KR, Berg WA. Treatment issues and core needle breast biopsy; clinical context. *Am J Roentgenol* 1998; 171:41-9.

52. Young WS, Chia KH, Poh WT, Wong CY. A comparison of trucut biopsy with fine-needle aspiration cytology in the diagnosis of breast cancer. *Singapore Med J* 1999; 40: 587-9.

53. Westend PJ, Sever AR, Beekman-DeVolder HJ, Liem SJ. A comparison of aspiration cytology and core needle biopsy in evaluation of breast lesions. *Cancer* 2001; 93: 146-50.

54. Verkooijen HM, Peeters PH, Buskens E, Koot VC, Borel Rinkes IH, Mali WP. Diagnostic accuracy of large-core needle biopsy of nonpalpable breast disease: a meta-analysis. *Br J Cancer* 2000; 82: 1017-21.

55. Berner A, Davidson B, Sigstad E, Risberg B. Fine-needle aspiration cytology vs. core biopsy in the diagnosis of breast lesions. *Diagn Cytopathol* 2003; 29: 344-8.

56. Liberman L. Percutaneous image-guided core breast biopsy. *Radiol Clin North Am* 2002; 40: 483-500.

57. Jacobs TW, Connolly JL, Schnitt SJ. Nonmalignant lesions in breast core needle biopsy: to excise or not to excise? *Am J Surg Pathol* 1095-110.

58. Dennison G, Anand R, Makar SH, Pain JA. A prospective study of the use of fine needle aspiration cytology and core biopsy in the diagnosis of breast cancer. *Breast J* 2003; 9: 491-3.

59. Agarwal T, Patel B, Rajan P, Cunningham DA, Darzi A, Hadjiminias DJ. Core biopsy versus FNAC for palpable breast cancers. Is image guidance necessary? Breast Care Unit and Academic Surgical Unit, St. Mary's Hospital, London, UK.

60. Farshid G, Rush G. The use of fine needle aspiration cytology and core biopsy in the assessment of highly suspicious mammographic microcalcification: analysis of outcome for 182 lesions detected in the setting of a population-based breast cancer program. *Cancer* 2003; 99: 357-64.

61. Wu XP, Cia PQ, Zhang WZ, Tang J, Gu YK, Li L. Clinical evaluation of three methods of fine needle aspiration, large-core needle biopsy and frozen section biopsy with focus staining for non-palpable breast disease. *Ai Zheng* 2004; 23: 346-9.

62. Homesh NA, Issa MA, El-Sofiani HA. The diagnostic accuracy of fine needle aspiration cytology versus core needle biopsy for palpable breast lump(s) Dept of General Surgery, Sana'a University Sana'a, Yemen. *Saudi Med J* 2005; 26(1): 42-6.

63. Silverman JF, Elsheikh TM, Singh HK. The Role of Fine Needle Aspiration Cytology of the Breast in the Core Biopsy Era. *Pathology Case Review* 2007; 12(1): 44-48.

64. Marcaccio MJ, O'Brian SE, Chen VS. Fine-needle aspiration cytology in breast lumps. *Can J Surg* 1986; 29(6): 405-7.

65. Hann L, Ducatman BS, Wang HH, Fein V, McIntire JM. Nonpalpable breast lesions: evaluation by means of fine-needle aspiration cytology. *Radiology* 171: 373-376.

66. Layfield LJ. Can fine needle aspiration replace open biopsy in diagnosis of palpable breast lesions? *Am J Clinical Pathol* 1992; 98: 145-147.

67. Jayaram G, Alhady SF, Yip CH. Cytological analysis of breast lesions: A review of 780 cases. *Malaysian Journal of Pathology* 1996; 18: 81-87.

68. Seltzer MH. Preoperative prediction of open breast biopsy results. *Cancer* 1997; 79: 1882-1827.

69. Antlry CM, Mooney EE, Layfield LJ. A comparison between open biopsy, cutting needle biopsy and fine needle aspiration biopsy of the breast; a three year

- experience. *The Breast Journal* 1998; 4: 3-8.
70. Feichter GE, Harberthur F, Gobat S, Dalquen P. Breast cytology. Statistical analysis and cytohistologic correlation. *Acta Cytol* 1997; 41: 327-32.
71. Logan-Young W, Dawson AE, Wilbur DC, Avila EE, Tomkiewicz ZM, Sheils LA. The cost effectiveness of fine needle aspiration cytology and 14-gauge core needle biopsy compared with open surgical biopsy in the diagnosis of breast carcinoma. *Cancer* 1998; 82: 1867-73.
72. Burkhadt JH, Sunshine JH. Core needle and surgical biopsy; comparison of three methods of assessing costs. *Radiology* 1992; 212: 181-8.
73. Yeoh GPS, Chan KW. Fine-needle aspiration of breast masses: an analysis of 1533 cases in private practice. *Hong Kong Medical Journal* 1998; 4: 283-7.
74. O'Neil S, Castelli M, Gattuso P, Kluskens L, Madsen K, Arnaha G. Fine-needle aspiration of 697 palpable breast lesions with histopathological correlation. *Surgery* 1997; 122: 824-8.
75. Ariga R, Bloom K, Reddy VB, Klusens L, Francescotti D, Dowlat K, Siziopikou P, Gattuso P. Fine-needle aspiration of clinically suspicious palpable breast masses with histopathological correlation. *M J Surg* 2002;184: 410-3.
76. Aziz M, Ahmed N, Zahid J, Faizullah, Aziz M. Comparison of FNAC and open biopsy in palpable breast lumps. *J Coll Physicians Surg Pak* 2004; 14: 654-6.
77. Lau SK, McKee GT, Weir MM. The negative predictive value of breast fine-needle aspiration biopsy: The Massachusetts General Hospital Experience. *The Breast Journal* 2004; 10: 487-91.
78. Muhammed AZ, Edino ST, Ochicha O, Alhasan SU. The value of fine-needle aspiration biopsy in preoperative diagnosis of palpable breast lumps in resource-poor countries: a Nigerian experience. *Annals of African Medicine* 2005; 4: 19-22.
79. Florentine BD, Staymate B, Rabadi M. The reliability of fine-needle aspiration biopsy as the initial diagnostic procedure for palpable masses. *Cancer* 2006; 107: 406-416.
80. Tiwari N. *Katmandu University Medical Journal* 2007; 5(2)18: 215-217.
81. Padel AF, Coghill SB, Powis SJ. Evidence that sensitivity is increased and the inadequacy rate decreased when pathologists take aspirates for cytodiagnosis. *Cytopathology* 1993; 4: 161-5.
82. Cohen MB, Rodgers RP, Hates MS, Gonzales JM, Ljung BM, Beckstead JH. Influence of training and experience in fine-needle aspiration biopsy in breast. Receiver operating characteristic curve analysis. *Arch Pathol Lab Med* 1987; 111: 518-20.
83. Choi YD, Choi YH, Lee JH, Nam JH, Juhng SW, Choi C. *Acta Cytol.* 2004; 48: 801-6.
- {full\_citation}

## Author Information

### Aditya Khemka

MBBS Student, K. J. Somaiya Medical College & Research Centre

### Nilay Chakrabarti, MS (General Surgery), DHA

Professor & Head, Dept. of Surgery,, K. J. Somaiya Medical College & Research Centre

### Shivani Shah

MBBS Student, K. J. Somaiya Medical College & Research Centre

**Vitthal Patel**

Post Graduate Student in Surgery, K. J. Somaiya  
Medical College & Research Centre

---

### Share This Article



*Your free access to ISPUB is funded by the following advertisements:*

Advertisement



After embarking on her own healing journey, Lauren followed her passion for alternative therapies so that she could share this gift with others.








Introducing  
your new best  
cold-fighting  
friend

[FIND OUT MORE ▶](#)



Always read the label and use only as directed.  
If symptoms persist, see your doctor.

**Sick of  
getting  
sick?**





 [BACK TO TOP](#)



