

## Review

# Male circumcision: review and authors perspective

Hegazy AA<sup>1,2</sup>, Al-Rukban MO<sup>3</sup>

<sup>1</sup>Department of Anatomy & Embryology, College of Applied Medical Sciences, Majmaah University, Saudi Arabia,

<sup>2</sup>Faculty of Medicine, Zagazig University, Egypt, <sup>3</sup>Department of Family & Community Medicine, College of Medicine, King Saud University, Saudi Arabia

## Correspondence

Abdelmonem Awad Hegazy  
Department of Anatomy &  
Embryology, Faculty of  
Medicine, Zagazig University,  
Egypt & College of Applied  
Medical Sciences, Majmaah  
University, Saudi Arabia

## E-mail:

dr.abdelmonemhegazy@yahoo.com

## Keywords:

Male Circumcision, Prepuce,  
Preputial Sac, Anatomy

## Funding

None

## Competing Interest

None declared.

Received: January 7, 2012

## Abstract

**Background:** The aim of this article was to evaluate the proposed benefits and consequences of male circumcision and highlight the penile prepuce, the poorly understood and much controversial part of the human body.

**Methods:** Databases of Pubmed, Science Direct, Springer Link, Wiley Interscience and others were searched. The research papers were studied and discussed. Finally, the opinion of the authors was recorded.

**Results:** Male circumcision is a legacy of the human civilization, originating in Egypt. It confers many prophylactic benefits for the recipient and his female partner. The benefits include protection against urinary tract infections, sexually transmitted diseases including HIV, penile and prostate cancer and cervical cancer in the female partner. At the same time, it is a simple and safe procedure, having minimal risks. The removed prepuce is not a vestigial but an important and unique structure, being used in repair of the common malformations of the penile urethra.

**Conclusion:** Benefits of circumcision vastly outweigh its potential risks. Newborns with penile anomalies are best treated by deferring the procedure until the defect can be corrected using prepuce at few months of age.

## Introduction

Though the human anatomy has been the object of scientific study since the sixteenth century, surprisingly little is known about the structure and function of the penile prepuce (foreskin).<sup>1</sup> Frequently, it is surgically removed shortly after birth by the procedure called circumcision. Although, it is the world's oldest known planned surgical procedure,<sup>2</sup> no consensus has been defined till now about its performance.<sup>3</sup> Many authors proposed that the prepuce is not 'vestigial' but in fact a critical component of the male sexual anatomy.<sup>4-6</sup> There are ectopic sebaceous glands on the inner preputial surface producing natural emollients and lubricants, necessary for normal sexual function.<sup>7</sup> Other authors said that the cause of preputial moistening is the secretions of prostate, seminal vesicles and urethral glands.<sup>8</sup>

This study aimed to evaluate the proposed benefits and consequences of male circumcision, and highlight the penile prepuce, a poorly understood and much controversial part of the human body. This might help urologists and health care members to better counsel men for elective circumcision and mothers submitting their babies for prophylactic circumcision.

## Methods

Databases of PubMed, ScienceDirect, SpringerLink, Wiley Interscience and others were searched. Search included all the available years. It was conducted between January 2010 and May 2011. The available research papers were studied and discussed. Finally, our opinion was recorded. The contents included the results, discussion, research recommendations and conclusions. The results contained two main titles; circumcision and prepuce.

## Results

### Circumcision

#### *Historical background of circumcision*

The origination of male circumcision is not known with certainty. However, it has been suggested that the procedure originated in Egypt over 15,000 years ago and spread throughout heliolithic cultures across the world during prehistoric migration.<sup>9</sup> Egyptian mummies and wall carvings offer some of the earliest recorded history of circumcision dating back to at least 6000 years ago (Figure 1a).<sup>10</sup> In ancient Egypt, prior to biblical times, circumcision was performed to improve male hygiene.

ISSN (print): 2218-3299

ISSN (online): 2219-8083




Figure 1a (left): Circumcision in Ancient Egypt  
[[http://upload.wikimedia.org/wikipedia/commons/8/8f/Egypt\\_circ.jpg](http://upload.wikimedia.org/wikipedia/commons/8/8f/Egypt_circ.jpg)]

Figure 1b (right): Ventral aspect of uncircumcised penis with retracted foreskin showing the frenulum

Later, routine circumcision of male infants was a part of the Abrahamic covenants with Jehovah, giving rise to religious circumcisions that continue until today in the Jewish and Muslim faiths. Then, circumcision of male infants has been advocated by Western culture as a preventive health measure.<sup>11</sup> Originating in the mid-19th century, 'routine' circumcision became widespread in white English-speaking nations, in the hope of reducing the incidence of venereal disease.<sup>12</sup> Also, in the early 1900s, circumcision was suggested as a way to prevent masturbation and tuberculosis.<sup>11</sup> Nowadays, many groups opposing neonatal circumcision have been formed and have become visible lobbyists. Examples include the National Organization to Halt the Abuse and Routine Mutilation of Males, San Francisco, and the National Organization of Circumcision Information Resource Centers based in San Anselmo, California, with branches across the United States and in Canada and other countries.<sup>13</sup>

#### Prevalence of circumcision

Ritual circumcision is common in Jewish and Islamic faiths and in sub Saharan Africa. Also, it was estimated that 69 to 97% of all boys and men in the USA had been circumcised, in comparison with 70% in Australia, 48% in Canada and 24% in the United Kingdom. The reported prevalence of the procedure in the United States increased from about 30% in the 1930s to nearly 80% in the early 1970s.<sup>13</sup> Nelson et al<sup>14</sup> noticed a significant increase in the rate of newborn circumcision in USA, according to data taken from the nationwide inpatient sample. The increased incidence is attributed to perceived health benefits, particularly improved hygiene and reduced penile cancer.<sup>13</sup>

#### Indications of circumcision

Circumcision is usually performed for social, religious or medical reasons. The common medical indications for circumcision are usually seen in adults. Medical reasons for circumcision

include phimosis, paraphimosis, trauma, recurrent skin infections and lesions,<sup>15</sup> preputial cysts, redundant foreskin,<sup>12</sup> and dyspareunia due to short frenulum.<sup>16</sup> Phimosis which means narrowing of the preputial orifice is the most common medical indication for circumcision in all age groups. Severe phimosis may cause pain on voiding, urinary retention, urinary tract infections, localized skin infections, and calculi, and later in life may be associated with sexual dysfunction and squamous-cell carcinoma.<sup>17</sup> Adhesions developing between the foreskin and the glans and preventing it to become retractile is another indication for circumcision. Secretions may collect under the foreskin producing infections and subsequent balanitis, or it may produce phimosis.<sup>13</sup>

#### Medical benefits of circumcision

Circumcision of newborns facilitates genital hygiene throughout life under varying environmental conditions. It prevents preputial colonization with uropathic bacteria in infancy and childhood.<sup>18</sup> Compared with circumcised infants, the uncircumcised boys have a ten to twenty-fold greater risk of urinary tract infections (UTIs) in the first few months of life.<sup>19</sup>

Circumcision appears to have a role in the protection against sexually transmitted diseases. Uncircumcised males were more prone to genital ulcer disease (syphilis, chancroid, herpes simplex).<sup>20</sup> Meanwhile, adult male circumcision could potentially reduce the transmission efficiency of HIV.<sup>21</sup> Conclusive evidence from three studies demonstrating the efficacy of male circumcision in preventing HIV infection showed that the range of protection is 51-61% (Table 1).<sup>22-24</sup> Therefore, circumcision programs are promoted to reduce the spread of HIV and AIDS in HIV-endemic areas.<sup>15</sup>

Male circumcision is associated with a reduced risk of penile human papilloma virus (HPV) infection and, in the case of men with a history of multiple sexual partners, a reduced risk of cervical cancer in their current female partners.<sup>25</sup> Like cervical cancer, the penile cancer is caused by high-risk (cancer causing) HPV.<sup>26</sup> The risks of developing cancer of the penis are almost eliminated by performing circumcision.<sup>27</sup> This effect appears to be a consequence of a lower incidence of infections with HPV and herpes simplex type 2.<sup>18</sup> For most cancers related to infectious organisms, chronic inflammation is an important component of pathogenesis. Moreover, some viruses incorporate their genetic materials directly into the host cell DNA.<sup>28</sup> Prostate cancer is another type of cancer to be noticed in uncircumcised men more than in the circumcised ones. Morris et al<sup>29</sup> concluded that a 1.6–2.0-fold higher risk of prostate cancer is contributed by the lack of circumcision. It has been proposed that HPV may also play a role in the development of cancers of prostate.<sup>30</sup>

Table 1: Studies demonstrating the efficacy of male circumcision in preventing HIV infection

Authors	Country	Total Participants	Age (yrs)	Protective effect (%)
Auvert et al. [22]	South Africa	3274	18-24	60-61
Bailey et al. [23]	Kenya	2784	18-24	60
Gray et al. [24]	Uganda	4996	15-49	51-55

### *Contraindications to circumcision*

Prophylactic circumcision is contraindicated in cases of congenital disorders, where the foreskin is required for surgical reconstruction of the penis. Such conditions include hypospadias, epispadias, chordee, buried penis and micropenis.<sup>13</sup> As the hypospadias complex is the most common of these conditions, it must always be excluded by careful inspection of the penis.<sup>18</sup> Moreover, circumcision should not be performed in cases of prematurity, as the premature infant is more prone to septicemia after circumcision.<sup>31</sup> Also, non-therapeutic circumcision is not recommended in cases of hemophilia, due to the high risk of bleeding.<sup>13</sup>

### *Best time to circumcision*

The procedure of circumcision can be done at any time throughout the life for therapeutic purposes. However, prophylactic circumcision is recommended as early as possible in the neonatal period. This proposal is based on the potential role of the preputial sac as a reservoir of fecal bacteria causing urinary tract infections, especially in the first year of life.<sup>32</sup> Submission of a child in the period of awareness to circumcision may result in an intensification of his genital anxiety. Before the age of two years, the child has no memory of the procedure.<sup>33</sup> Both neonatal and adult circumcisions are safe, but adult circumcision may have more associated adverse events than the childhood or neonatal circumcision.<sup>34</sup>

When it is performed in the adult male, he should abstain from sex for 4-6 weeks and realize that final cosmetic appearance requires several months. Therefore, for optimum health benefit, cosmetic result (no stitches), simplicity, speed, convenience and cost, infancy is the ideal time to perform a circumcision.<sup>26</sup> There are other recommendations, suggesting that circumcision should be delayed till the fifth<sup>35</sup> or sixth month<sup>36</sup> after birth to reduce complications, such as meatal stenosis, infections and adhesions.<sup>35</sup>

### *Potential complications of the circumcision procedure*

Studies reported few severe complications of circumcision. Mild or moderate complications are seen, especially when circumcision is undertaken at older ages, by inexperienced operators or in non-sterile conditions.<sup>37</sup> The 1989 review of the American Academy of Pediatrics' Task Force on Circumcision reported that the rate of postoperative complications of male circumcision is approximately 0.2% to 0.6%. The majority of complications are minor, the most common being local infection and bleeding.<sup>38</sup> Other cited complications are meatal stenosis, removal of excessive or inadequate foreskin, penile injury, urethral injury and painful scarring.<sup>39</sup> Other major but rare complications included glans amputation.<sup>40</sup>

### *Sexual consequences of circumcision*

The function of the prepuce in human sexual response continues to be a topic of debate. Anti-circumcision groups claimed that the foreskin is necessary for the normal sexual function.<sup>4-</sup>  
<sup>6</sup> Male circumcision permanently removes normal, functional, specialized tissue.<sup>41</sup> It deletes the junctional mucosa that ap-

pears to be an important component of the overall sensory mechanism of the penis.<sup>42</sup> The residual exposed glans mucosa becomes abnormally keratinized with an increase in the number of cell layers in glanular mucosal epithelium. Moreover, the foreskin that is retracted over the body of the glans during coitus facilitating the intromission.<sup>43</sup> This is attributed to what is called "gliding mechanism". The gliding mechanism is Nature's intended mechanism of intercourse which makes sex easier without using artificial lubricants.<sup>44</sup> Regarding the sexual satisfaction of female partners, O'Hara and O'Hara<sup>45</sup> surveyed women who had experience of sex with circumcised and uncircumcised partners. A significant number of women preferred vaginal intercourse with uncircumcised penis. The authors claimed that when the uncircumcised penis thrusts in the vagina, it does not slide, but rather glides on its own 'bedding' of movable skin, leading to less discomfort.

On the other hand, many objective studies have shown no significant difference in sexual function between circumcised and uncircumcised men.<sup>46-48</sup> If anything, improved genital hygiene favors more varied sexual activity in circumcised men.<sup>49</sup> Circumcised men have more liberal sexual attitudes<sup>50</sup> and the circumcised penis has been reported to be preferred by women in a study in Middle America.<sup>51</sup> This sexual preference for male circumcision within the American culture is considered as a valid reason for continuing the practice.

## **B. Prepuce**

### *Gross anatomy of the prepuce*

The prepuce is a fold of skin that covers the glans. It is connected to the glans just below the urethral orifice by a fold called the frenulum (Figure 1b).<sup>52</sup> The prepuce and glans penis enclose a potential cleft, the preputial sac, and two shallow fossae flank the frenulum.<sup>53</sup> The frenulum tethers the bottom of the prepuce to the ventral aspect of the glans. It restricts proximal movement of the ridged band and assists in returning the prepuce to its distal position over the glans.<sup>54</sup> In fact, the frenulum is collectively known as the "sex nerve" in France. It is hypothesized that its stretching during coitus forms a stimulus for ejaculation.<sup>55</sup>

### *Histological features of the prepuce*

The prepuce looks like a double fold of skin.<sup>52,53,56,57</sup> Its outer layer represents an extension from the thin and dark skin of body of penis, at the corona of the penis. The inner layer is confluent at the neck of penis with the thin skin covering and adhering firmly to the glans.<sup>53</sup> There is no significant difference between the inner and outer foreskin keratin thickness in adults "25.37 ± 12.51 and 20.54 ± 12.51 μm respectively, p=0.451".<sup>57</sup>

Other authors reported that the prepuce is not a simple fold of skin, but it is a fold, bounded by skin externally and mucosa internally.<sup>4,42,58</sup> Its mucocutaneous junction resembles that of eyelids, lips, anus, and labia minora.<sup>4</sup> When retracted in uncircumcised penis, the inner surface of the prepuce displays two zones; ridged and smooth. The crests of the ridged zone contain numerous tactile nerve endings of Meissner

(Meissner's corpuscles). They are not present in the sulci (furrows) between the ridges.<sup>42</sup>

The lamina propria of the prepuce is very vascular, which explains the common hemorrhagic complications associated with circumcision.<sup>4</sup> It is devoid of lanugo hair follicles, sweat and sebaceous glands.<sup>42</sup> Also, there is a mosaic of smooth muscle bundles and elastic fibers enclosed between the external and internal skin of the prepuce.<sup>56</sup> The muscle fibers represent extensions of dartos muscle which is specific to the male external genitalia. When comparing the dartos muscle layer of prepuce in males before and after puberty, the ratio of muscle fibers to elastic fibers decreases. This may explain why on gross inspection the distal prepuce is puckered in the infant and appears more relaxed in adults.<sup>4</sup>

#### *Development of the prepuce*

The prepuce develops early in intrauterine life as a fold originating at the coronal sulcus (the groove that demarcates the shaft from the glans penis). This fold inverts (the outside becoming the inside) as it grows forward over the glans. Shared epidermal cells of the glans and the advancing prepuce create a common balanopreputial membrane which firmly attaches the prepuce to the glans. The complete enfolding of the glans by the prepuce is accomplished by the twenty fourth week.<sup>54</sup> Although the actual separation of the prepuce from the glans begins at 24 weeks of gestation, the inner preputial surface and the surface of the glans are contiguous and appear to be adherent at birth. Such adhesions are physiologic and universal during neonatal period and infancy.<sup>59</sup> Over the next years, preputial separation gradually occurs as the cells in the fused layers mature and desquamate. This separation occurs spontaneously along an age-related continuum, with approximately 90% of foreskins are retractable by 3 years of age.<sup>60</sup>

#### *Function of the prepuce*

The function of the foreskin is uncertain, but protection of the underlying penile glans and meatus, as well as reduction of friction during sexual intercourse, has been proposed.<sup>60</sup> It has been suggested that the moist lubricated male preputial sac provides for atraumatic vaginal intercourse.<sup>4</sup>

#### *Clinical use of the excised prepuce*

The normal human prepuce has unique histological structure,<sup>58</sup> being nonhirsute, flexible, and versatile.<sup>61</sup> It provides a good autologous full-thickness skin graft of good elastic quality, avoiding secondary retraction. However, the most common problem reported after its use as a donor skin is hyperpigmentation. This problem is not a contraindication for its use as a skin graft, especially in the hidden parts.<sup>62</sup>

The prepuce has been used for repair of many cases of congenital deformities. Such cases include hypospadias,<sup>63, 64</sup> which represents one of the most common congenital anomalies,<sup>65</sup> of an incidence 1:300 in male newborns.<sup>66</sup> Also, it has been used in repair of epispadias for both urethral reconstruction and dorsal skin coverage,<sup>67, 68</sup> repair of syndactyly

with good aesthetic results<sup>69</sup> and cutaneous grafting after nevus excision.<sup>62</sup> Moreover, it can provide a large amount of soft delicate skin suitable for replacement of lost conjunctiva or in the surgical treatment of ectropion. Three typical examples of its uses are described; two of ectropion following burns and one case with a carcinoma of the conjunctiva which was excised and replaced with a free graft from the inner lining layer of the prepuce.<sup>70</sup> Other examples for use of prepuce include cutaneous grafting after burns,<sup>71</sup> reconstruction of anal stenosis<sup>72</sup> and repair of urethral stricture.<sup>61</sup>

#### **Discussion**

Male circumcision has many therapeutic indications as well as it carries a lot of lifetime medical benefits. The therapeutic indications include phimosis, paraphimosis and trauma, whilst the commonly cited benefits include the decreased incidence of urinary tract infections and protection against sexually transmitted diseases, penile cancer and cervical cancer in the female partner. These reported advantages must be weighed against the complications of the procedure. Circumcision is usually a safe and simple procedure.<sup>73</sup> The majority of its complications are minor, the most common being local infection and bleeding. The bleeding which is usually slight oozing, is most often controlled with pressure, and the infection is treated with wound care or antibiotics. Hence, the advantages of circumcision vastly outweigh its potential risks.

The data indicating that circumcision may confer a protection against the spread of HIV has raised the interest in the procedure. It is possible that large population-based programs to promote circumcisions may significantly reduce the spread of HIV and AIDS in areas where routine circumcision is uncommon. Communities, and especially women, may benefit much more from circumcision interventions, and these results provide an even greater imperative to increase scale-up of safe male circumcision services.<sup>74</sup> Schoen<sup>49</sup> added that the procedure gives a protection greater than was originally expected for a successful HIV vaccine. The presence of foreskin is a risk factor in two ways. Firstly, the delicate inner mucous membrane is easily torn during intercourse creating mini-abrasions through which the virus can enter. Secondly, it has been shown that special phagocytic cells in the foreskin, Langerhans cells, act as magnets to the virus which attaches to the cell but cannot be destroyed and thus enters the body. Regarding the

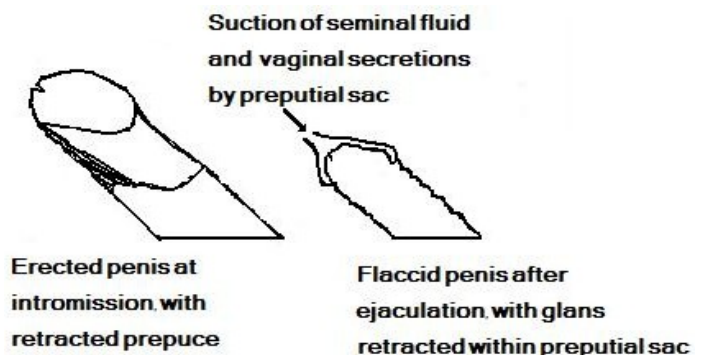


Figure 2: Mechanism of suction of vaginal contents into the preputial sac



first point, it can be suggested that increased abrasions might be due the traction on the frenulum by the redundant foreskin during intromission, especially in case of narrow vagina. Also, the foreskin is nearly everted at intromission; being pulled back down the shaft of the penis, so that the whole inner delicate layer of the foreskin becomes in contact with the vaginal secretions. This increases the surface area exposed to HIV transmission.

The reported association between the uncircumcised status and the increased incidence of other sexually transmitted diseases and urinary tract infections might be explained by a negative pressure mostly created in the preputial sac at the end of male sexual cycle. Shortly after ejaculation, the penis becomes flaccid and then the glans retracts within the preputial sac. This creates a vacuum suction for the vaginal secretions and even the seminal fluid into preputial sac (Figure 2). It will not only increase the incidence of sexually transmitted diseases, but also it may reduce the incidence of fertilization especially in cases of oligospermia, through its expected action as a suction-trap for the ejaculated semen. This proposal is based on the potential role of the preputial sac as a trap HIV and HIV-infected cells after intercourse.<sup>75</sup> Additionally, the micro-environment of the preputial sac may be conducive to viral survival, keeping infected vaginal or anal fluid in a warm, moist state.<sup>76</sup> Male circumcision could reduce the risk of Chlamydia trachomatis infection in female sexual partners<sup>77</sup> that represents a major factor in causing female infertility.<sup>49</sup>

Evidence regarding sexual consequences of circumcision is still conflicting. Anti-circumcision groups mainly based their refusal for the routine circumcision on the grounds that the procedure affects the sensitivity of the glans and the pleasure with sexual intercourse. It has been claimed that when the uncircumcised penis thrusts in the vagina, it does not slide, but rather glides on its own 'bedding' of movable skin, leading to less discomfort.<sup>45</sup> This suggestion likens the sexual intercourse as masturbation and hence it will not increase the sexual pleasure. The sexual pleasure comes from the direct contact and gliding of genitalia of the couple against each other, not from gliding against the own skin. Other authors claimed that the increased keratinization of the glans following the foreskin's removal causes reduction in the sensation.<sup>13</sup> However, such decrease in the glans sensitivity may be the cause for the significant increase in the ejaculatory latency time noticed by Senkul et al<sup>78</sup> after circumcision. This increase in the ejaculatory latency time is considered to be an advantage rather than a complication. As a result of this increase, circumcision may be advised to treat premature ejaculation. Gallo et al<sup>79</sup> found the genital anomaly of short frenulum in 43% of individuals affected by lifelong premature ejaculation. Because of the "surprising excellent increase in the mean intravaginal ejaculatory latency time" after frenulectomy, the authors proposed frenulectomy as a first-line treatment in these cases. Therefore, circumcision which includes partial or complete frenulectomy could be indicated as a treatment for premature ejaculation.

It has been claimed that circumcision removes tissues necessary for normal sexual function.<sup>42</sup> On the other hand, a recent study has shown no sexual dysfunction following circumcision, but there is increased penile sensitivity and enhanced ease to reach orgasm.<sup>80</sup> Also, it has been shown that there is no significant difference between the circumcised and uncircumcised men regarding the quantitative somatosensory testing results at the glans penis.<sup>3</sup> The glans is the principal source of afferent information for the induction and maintenance of sexual response. This finding is supported by the electrical representation of glanular innervations revealing it to be filled with nerve endings.<sup>81</sup>

Opponents of routine circumcision said that the prepuce should be left in its natural state. It is naturally equipped with several defenses against infection. Also, it has a pronounced tight tip with a sphincter formed by the whorl of muscle tissue that stays closed to keep out foreign matter but opens to allow urine outflow.<sup>55</sup> This claimed function might be not found, due to two factors. Firstly, the prepuce mostly becomes retractable between the ages of one and three years. Secondly, urinary tract infections occur in the first few months of life, much more in uncircumcised infants than in circumcised ones.<sup>19</sup>

Regarding the best time for circumcision, Banieghbal<sup>33</sup> stated that prophylactic circumcision should be done at the first week after birth, since the risk of complications increases in older babies, boys and adults. Moreover, the first week of life is a physiologic period in respect to the prothrombin levels.<sup>82</sup> Other authors suggested that it should be delayed till the fifth or sixth month.<sup>35, 36</sup> However, such delayed time is a part of the period of infancy which is characterized by rapid physical growth. At the age of four months of age, the baby begins to grasp and manipulate small things and to crawl backwards. Then at the sixth month, he crawls on his abdomen with arms.<sup>83</sup> Therefore, the phallus of the baby is more prone to injury and infections if circumcision is performed at that time.

Review of the previous literatures about the prepuce showed that it has unique histological structure; being covered externally by skin and lined by mucosa, or thin skin internally. This makes it to be used as an autologous full-thickness graft. It also has good elastic tissue, avoiding secondary retraction.<sup>62</sup> Moreover, its lamina propria is very vascular<sup>4</sup>, leading to good healing. The graft is used for repair of many defects, especially congenital anomalies of the male urethra. Newborns with visible penile anomalies are best treated by deferring the procedure until the defect can be corrected using general anesthesia at few months of age.<sup>84</sup> Therefore, the baby must be carefully examined before performing the circumcision to exclude such congenital anomalies.

### Research Recommendation

Prospective studies are needed to better understand the structure of the inner layer of the prepuce at different ages, aiming to define if it is a mucous membrane or skin or it begins as mucous membrane then becomes keratinized with the

the advance of age. This will enable the plastic surgeons to better plane its clinical uses as a graft. Also, it will help to know the source of wetness of the preputial sac, whether it is secretions from the inner layer or colonization of bacteria and other microbes. Up to 30% of couples are unable to conceive, in spite of failure of the basic infertility evaluation to reveal any obvious abnormality. They are determined to have unexplained infertility.<sup>85</sup> Houle<sup>86</sup> stated that circumcision reduces the incidence of infertility through prevention of Chlamydia infections. Based on our proposal of the potential role of the preputial sac as a trap for the ejaculated semen, the sac might be a factor in cases of unexplained infertility. This suggestion might be investigated through future studies.

### Conclusions

Male circumcision is a legacy of the human civilization, originating in Egypt. It confers many prophylactic benefits for the recipient and his female partner. At the same time, it is more or less safe procedure, having minimal risks. It might be recommended as a prophylactic measure for all males. The removed prepuce is not vestigial but an important and unique structure, used in repair of the common malformations of the penile urethra.

### References

1. Bay NS, Bay BH. Greek anatomist herophilus: the father of anatomy. *Anat Cell Biol.* 2010; 43:280-3.
2. Alanis MC, Lucidi RS. Neonatal circumcision: a review of the world's oldest and most controversial operation. *Obstet Gynecol Surv.* 2004; 59:379-95.
3. Bleustein CB, Fogarty JD, Eckholdt H, Arezzo JC, Melman A. Effect of neonatal circumcision on penile neurologic sensation. *Urology.* 2005; 65:773-7.
4. Cold CJ, Taylor JR. The prepuce. *BJU Int.* 1999; 83:34-44.
5. Cold CJ, McGrath KA. Anatomy and histology of the penile and clitoral prepuce in primates. In male and female circumcision, Denniston GC, Hodges FM, Milos MF (eds.). 1999. New York: Kluwer Academic/Plenum Publishers.
6. Denniston GC, Hill G. Circumcision in adults: effect on sexual function. *Urology.* 2004; 64:1267.
7. Fleiss PM, Hodges F. Nontherapeutic circumcision should not be performed. *Ame Med News.* 1995; 38:16-21. Bigelow J. *The Joy of Uncircumcizing* (3rd ed).
8. Prakash S, Rao R, Venkatesan K, Ramakrishnan S. Sub-preputial wetness- its nature. *Ann Nat Med Sci (India).* 1982; 18:109-12.
9. Dunsmuir WD, Gordon EM. The history of circumcision. *BJU Int.* 1999; 83:1-12.
10. Rizvi SAH, Naqvi SA, Hussain M, Hasan AS. Religious circumcision: a Muslim view. *BJU Int.* 1993; 83:13-6.
11. Baskin LS. Patient information: circumcision in baby boys (Beyond the basics). Available: <http://tinyurl.com/85nmjpc> [accessed 9 March 2012].
12. Rickwood AM. Medical indications for circumcision. *BJU Int.* 1999; 83 Suppl 1:45-51.
13. Hirji H, Charlton R, Sarmah S. Male circumcision: a review of the evidence. *JMHG.* 2005; 2:21-30.
14. Nelson CP, Dunn R, Wan J, Wei JT. The increasing incidence of newborn circumcision: data from the nationwide inpatient sample. *J Urol.* 2005; 173:978-81.
15. Peterson AC. Elective, adult circumcision does not affect patient perception of sexual health as defined by male sexual health questionnaire (MSHQ). *JMHG.* 2010; 7:368-72. Available: <http://tinyurl.com/78x2fzx> [accessed 9 March 2012].
16. Whelan P. Male dyspareunia due to short frenulum: an indication for adult circumcision. *Br Med J.* 1977; 2:1633-4.
17. Spilsbury K, Semmens J, Wisniewski ZS, Holman CD. Circumcision for phimosis and other medical indications in Western Australian boys. *Med J Aust.* 2003; 178:155-8.
18. Gerharz EW, Haarmann C. The first cut is the deepest? Medicolegal aspects of male circumcision. *BJU Int.* 2000; 86:332-8.
19. Wiswell TE, Roscelli JP. Corroborative evidence of the decreased incidence of urinary tract infections in circumcised male infants. *Pediatrics.* 1986; 78:96-9.
20. Malone P, Steinbrecher H. Medical aspects of male circumcision. *BMJ.* 2007; 335:1206-9.
21. Atashili J. Adult male circumcision to prevent HIV? *Int J Infect Dis.* 2006; 10:202-5.
22. Auvert B, Taljaard D, Lagarde E, Sobngwi-Tambekou J, Sitta R, et al. Randomized, controlled intervention trial of male circumcision for reduction of HIV infection risk: The ANRS 1265 Trial. *PLoS Med.* 2005; 2:e298.
23. Bailey RC, Moses S, Parker CB, Agot K, Maclean I, et al. Male circumcision for HIV prevention in young men in Kisumu, Kenya: a randomized controlled trial. *Lancet.* 2007; 24:369:643-56.
24. Gray RH, Kigozi G, Serwadda D, Makumbi F, Watya S, et al. Male circumcision for HIV prevention in men in Rakai, Uganda: a randomized trial. *Lancet.* 2007; 24:369:657-66.
25. Castellsagué X, Bosch FX, Muñoz N, Meijer CJ, Shah KV, et al. Male circumcision, penile human papillomavirus infection, and cervical cancer in female partners. *N Engl J Med.* 2002; 346:1105-12.
26. Morris BJ. Why circumcision is a biomedical imperative for the 21(st) century. *Bioessays.* 2007; 29:1147-58.
27. Morris BJ, Gray RH, Castellsagué X, Bosch FX, Halperin DT, et al. The strong protective effect of circumcision against cancer of the penis. *Adv Urol.* 2011; 2011:81 2368.
28. Thun MJ, DeLancey JO, Center MM, Jemal A, Ward EM. The global burden of cancer: priorities for prevention. *Carcinogenesis.* 2010; 31:100-10.
29. Morris BJ, Waskett J, Bailis SA. Case number and the financial impact of circumcision in reducing prostate cancer. *BJU Int.* 2007; 100:5-6.
30. Dennis LK, Dawson DV. Meta-analysis of measures of sexual activity and prostate cancer. *Epidemiology.* 2002; 13:72-9.
31. Warner E, Strashin E. Benefits and risks of circumcision. *Can Med Assoc J.* 1981; 125: 967-76, 992.
32. Savaş C, Cakmak M, Yorgancigil B, Bezir M. Comparison of the preputial sac and urine cultures in healthy children. *Int Urol Nephrol.* 2000; 32:85-7.
33. Banieghbal B. Optimal time for neonatal circumcision: an observation-based study. *J Pediatr Urol.* 2009; 5:359-62.
34. Perera CL, Bridgewater FH, Thavaneswaran P, Maddern GJ. Safety and efficacy of nontherapeutic male circumcision: a systematic review. *Ann Fam Med.* 2010; 8:64-72.
35. Machmouchi M, Alkhotani A. Is neonatal circumcision judicious? *Eur J Pediatr Surg.* 2007; 17:266-9.
36. Leditschke JF. Guidelines for circumcision. Australasian Association of Paediatric Surgeons. Herston, QLD: 1996. Available: <http://www.cirp.org/library/statements/aaps/> [accessed 20 March 2010].
37. Weiss HA, Larke N, Halperin D, Schenker I. Complications of circumcision in male neonates, infants and children: a systemic review. *BMC Urol.* 2010; 10:2.
38. Moses S, Bailey RC, Ronald AR. Male circumcision: assessment of health benefits and risks. *Sex Transm Infect.* 1998; 74:368-73.
39. Johnson PRV. Childhood circumcision. *Surgery.* 2005; 23(9):338-40. Available: <http://tinyurl.com/7bme5pu> [accessed 9 March 2012].

40. Faydaci G, Ugur K, Osman C, Şermin S, Bilal E. Amputation of glans penis: a rare circumcision complication and successful management with primary anastomosis and hyperbaric oxygen therapy. *Korean J Urol.* 2011; 52:147-9.
41. Dalton JD. Male circumcision-see the harm to get a balanced picture. *JMHG.* 2007; 4:312-7.
42. Taylor JR, Lockwood AP, Taylor AJ. The prepuce: specialized mucosa of the penis and its loss to circumcision. *Br J Urol.* 1996; 77:291-5.
43. Taves D. The intromission function of the foreskin. *Med Hypotheses.* 2002; 59:180-2.
44. Circumcision Information and Resource Pages (CIRP). Anatomy of the penis, mechanics of intercourse. 2005. Available: <http://www.cirp.org/pages/anat/>. [accessed 11 March 2011].
45. O'Hara K, O'Hara J. The effect of male circumcision on the sexual enjoyment of the female partner. *BJU Int.* 1999; 83 Suppl:79-84.
46. Laumann EO, Masi CM, Zuckerman EW. Circumcision in the United States. Prevalence, prophylactic effects, and sexual practice. *JAMA.* 1997; 277:1052-7.
47. Fink KS, Carson CC, DeVellis RF. Adult circumcision outcomes study: effect on erectile function, penile sensitivity, sexual activity and satisfaction. *J Urol.* 2002; 167:2113-6.
48. Cortés-González JR, Arratia-Maqueo JA, Gómez-Guerra LS. Does circumcision has an effect on female's perception of sexual satisfaction? *Rev Invest Clin.* 2008; 60:227-30.
49. Schoen EJ. Circumcision as a lifetime vaccination with many benefits. *JMHG.* 2007; 4:306-11.
50. Richters J, Smith AM, de Visser RO, Grulich AE, Rissel CE. Circumcision in Australia: prevalence and effects on sexual health. *Int J STD AIDS.* 2006; 17:547-54.
51. Williamson ML, Williamson PS. Women's preferences for penile circumcision in sexual partners. *J Sex Educ Ther.* 1988; 14:8-12.
52. Snell RS. *Clinical Anatomy* (7<sup>th</sup> edition). 2004. Philadelphia, Baltimore: Lippincott Williams & Wilkins.
53. Standring S, Ellis H, Healy JC et al. *Gray's Anatomy: The anatomical basis of clinical practice* (39<sup>th</sup> edition). 2008. Elsevier Inc. Churchill Livingstone.
54. Scott S. The anatomy and histology of the human prepuce. Book chapter; *Male and Female Circumcision*, Section 2, 1999. P. 9-18.
55. Circumcision Information and Resource Pages (CIRP). The penis and foreskin: preputial anatomy and sexual function. 2007. Available: <http://www.cirp.org/library/anatomy/> [accessed 22 April 2010].
56. Lakshmanan S, Parkash S. Human prepuce: some aspects of structure and function. *Ind J Surg.* 1980; 44:134-7.
57. Dinh MH, McRaven MD, Kelley ZL, Penugonda S, Hope TJ. Keratinization of the adult male foreskin and implications for male circumcision. *AIDS.* 2010; 24:899-906.
58. Tuncali D, Bingul F, Talim B, Surucu S, Sahin F, et al. Histologic characteristics of the human prepuce pertaining to its clinical behavior as a dual graft. *Ann Plast Surg.* 2005; 54:191-5.
59. Kumar P, Deb M, Das K. Preputial adhesions – a misunderstood entity. *Indian J Pediatr.* 2009; 76:829-32.
60. Johnson PRV. Circumcision. *Surgery* 2004; 22:263-65. The Medicine Publishing Company Ltd.
61. Hussein MM, Moursy E, Gamal W, Zaki M, Rashed A, et al. The use of penile skin graft versus penile skin flap in the repair of long bulbo-penile urethral stricture: a prospective randomized study. *Urology* 2011; 77:1232-7.
62. D'Alessio A, Piro E, Brugnoli M, Abati L. Use of preputial skin as cutaneous graft after nevus excision. *Int J Pediatr.* 2010; 2010:951270.
63. Nagai A, Nasu Y, Watanabe M, Kusumi N, Tsuboi H, et al. Clinical results of one-stage urethroplasty with paramental foreskin flap for hypospadias. *Acta Med Okayama.* 2005; 59:45-8.
64. Yu B, Zhou J, Wang Z, Cai ZK, Dong GQ, et al. Duckett's procedure of one-stage urethroplasty for hypospadias. *Zhonghua Nan Ke Xue.* 2009; 15:12-5.
65. Baskin LS, Himes K, Colborn T. Hypospadias and endocrine disruption: is there a connection? *Environ Health Perspect.* 2001; 109:1175-83.
66. Djakovic N, Nyarangi-Dix J, Öztürk A, Hohenfellner M. Hypospadias. *Adv Urol.* 2008; 650135. Available: <http://www.ncbi.nlm.nih.gov/pmc/articles/PMC2577154/?tool=pmcentrez> [accessed 12 January 2011].
67. Thomalla JV, Mitchell ME. Ventral preputial island flap technique for the repair of epispadias with or without exstrophy. *J Urol.* 1984; 132:985-7.
68. Monfort G, Morisson-Lacombe G, Guys JM, Coquet M. Transverse island flap and double flap procedure in the treatment of congenital epispadias in 32 patients. *J Urol.* 1987; 138:1069-71.
69. Oates SD, Gosain AK. Syndactyly repair performed simultaneously with circumcision: use of foreskin as a skin-graft donor site. *J Pediatr Surg.* 1997; 32:1482-4.
70. Parkash S. The use of preputial skin to replace conjunctiva and to correct ectropion. *Br J Plast Surg.* 1982; 35:206-8.
71. Doğrul AB, Aytaç O, Kiliç YA, Konan A, Yorgancı K. Preputial skin can be used in all boys with burns requiring grafting. *Ulus Travma Acil Cerrahi Derg.* 2009; 15:58-61.
72. Sakai S, Yoshinaga R. The prepuce flap in the reconstruction of male anal stenosis. *Br J Plast Surg.* 1999; 52:660-2.
73. Sherman J, Borer JG, Horowitz M, Glassberg KI. Circumcision: successful glandular reconstruction and survival following traumatic amputation. *J Urol.* 1996; 156:842-4.
74. Hallett TB, Alsallaq RA, Baeten JM, Weiss H, Celum C, et al. Will circumcision provide even more protection from HIV to women and men? New estimates of the population impact of circumcision interventions. *Sex Transm Infect.* 2011; 87:88-93.
75. Anderson D, Politch JA, Pudney J. HIV infection and immune defense of the penis. *Am J Reprod Immunol.* 2011; 65 220-9.
76. Weiss HA. Male circumcision as a preventive measure against HIV and other sexually transmitted diseases. *Curr Opin Infect Dis.* 2007; 20:66-72.
77. Castellsagué X, Peeling RW, Franceschi S, de Sanjosé S, Smith JS, et al. Chlamydia trachomatis infection in female partners of circumcised and uncircumcised adult men. *Am J Epidemiol.* 2005; 162:907-16.
78. Senkul T, Işerl C, Şen B, Karademir K, Saraçoğlu F, et al. Circumcision in adults: effect on sexual function. *Urology.* 2004; 63:155-8.
79. Gallo L, Perdonà S, Gallo A. The role of short frenulum and the effects of frenulectomy on premature ejaculation. *J Sex Med.* 2010; 7:1269-76.
80. Krieger JN, Mehta SD, Bailey RC, Agot K, Ndinya-Achola JO, et al. Adult male circumcision: effects on sexual function and sexual satisfaction in Kisumu, Kenya. *J Sex Med.* 2008; 5:2610-22.
81. Yang CC, Bradley WE. Innervation of the human glans penis. *J Urol.* 1999; 161:97-102.
82. Hovsepian D. The pros and cons of routine circumcision. *Calif Med.* 1951; 75:359-61.
83. Potter PA, Perry AG. *Fundamentals of nursing* (6<sup>th</sup> edition). 2005. Elsevier Mosby, USA.
84. Snodgrass WT, Khavari R. Prior circumcision does not complicate repair of hypospadias with an intact prepuce. *J Urol.* 2006; 176:296-8.
85. Alabama B. Effectiveness and treatment for unexplained infertility. *Fertil Steril.* 2006; 86:S111-4.
86. Houle A. Circumcision for all: the pro side. *Can Urol Assoc J.* 2007; 1:398-400.