

Retropharyngeal Lipoma – A Case Report

O. S. Radhakrishna Pillai · S. Vijayalakshmi · T. V. Adarsha · Mohammed Thahir ·
Uday Kumar Gopinathan · Navisha Mohammed

Abstract

Lipomas of the retropharyngeal region are rare. They attain a large size before producing symptoms like dyspnoea and dysphagia. A case of lipoma in the retropharyngeal space is reported with characteristic radiological findings and surgical management.

Keywords Lipoma · Retropharyngeal space ·
Trans oral excision

Introduction

Retropharyngeal tumors are relatively rare. Most of these tumors are malignant, though benign tumors like lipoma, myoma and fibroma also occur rarely. These have to be managed surgically when symptoms are severe.

A 42-year-old man presented with severe dyspnoea and inability to lie down flat of three days duration. He also gave a history of snoring during sleep of fifteen years duration and change in voice with mild dyspnoea of three years duration. The change in voice was stationary for the past three years but dyspnoea used to get aggravated at times especially during episodes of upper respiratory tract infection. Dyspnoea was relieved on medication. Patient also had difficulty to lie down flat for the past one year and he used to sleep propped up with 2 or 3 pillows. Patient was a known diabetic for past 10 years, controlled with oral hypoglycemic drugs. Examination revealed a well-built gentleman in moderate inspiratory stridor. He had a short neck and thick tongue. On depressing the tongue, a huge bulge could be seen on the posterior pharyngeal wall extending from the nasopharynx down below to the hypopharynx. In view of the inspiratory stridor, indirect laryngoscopy was not attempted. Examination of nose and ear was normal. Patient was admitted on the same day and nursed in semi recumbent position. He was put on IV antibiotics (Ciprofloxacin).

Routine investigations were within normal limits. X-ray Chest and ECG were normal. X-ray neck lateral view showed Pre-vertebral widening (Fig. 1). CT scan neck revealed a fat density mass in the retropharyngeal space extending from C1 to C7 levels. The margins of the mass were well defined. The lesion extended from the nasopharynx and appeared to be continuous with the fat in the superior mediastinum. The prevertebral muscles were compressed but otherwise appeared normal. The mass measured approximately 8x5 (axial) x 11 (cranio caudal) cms. (Figs. 2, 3).

Transoral excision of the tumor was planned. Though informed consent for tracheostomy was taken, anesthesiologist could intubate the patient with minimal difficulty,

O. S. Radhakrishna Pillai · S. Vijayalakshmi (✉) ·
T. V. Adarsha · M. Thahir · U. K. Gopinathan · N. Mohammed
Department of Otorhinolaryngology,
Yenepoya Medical College, Deralakatte,
Mangalore – 575 018

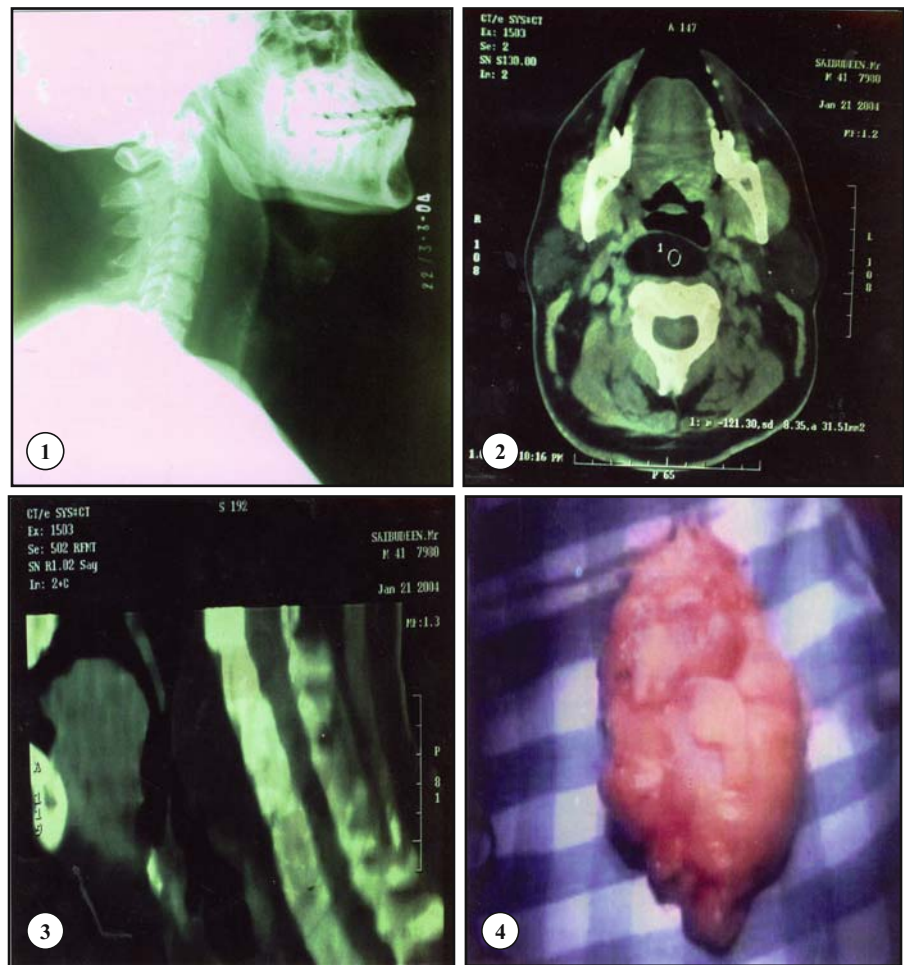
Asst. Prof. Dept. of Otorhinolaryngology,
Yenepoya Medical College,
Deralakatte,
Mangalore – 575 018
Karnataka
Email: vijisubbu@gmail.com

Fig. 1 X-ray Lateral view of the neck showing Pre-vertebral widening extending from C1 to C7

Fig. 2 Axial CT Scan showing fat density mass (HU-121) in retropharyngeal space

Fig. 3 Sagittal reformatted CT image showing fat density mass in the Retropharyngeal space

Fig. 4 Photograph of excised specimen



thus avoiding a tracheostomy. Patient was put in Rose's position. Boyle Davis mouth gag was introduced and posterior pharyngeal wall exposed. A vertical incision was made in the midline and mucosal flaps were retracted laterally with Mollison's pillar retractor. The tumor was held with tonsil Vulsellum forceps and dissection carried out from above downwards with traction over the tumor. The mass was removed in toto (Fig. 4). The wound was closed with 3'0 vicryl. Postoperatively the patient was put on IV antibiotics (Ciprofloxacin and Gentamicin). Ryle's tube feeds were given for a week.

Histopathological examination of the excised specimen was reported as lipoma.

Discussion

Lipomas are common tumors of mesenchymal origin. Majority of lipomas occur as subcutaneous lesions. Approximately 13% of them occur in the head and neck. Histologically, they are composed of mature adipose tissue with no cellular atypia and are usually surrounded by a thin capsule of connective tissue. The clinical history of lipoma is that of a slow growing mass and deep lesions may go undiagnosed because of patients getting habituated

to symptoms. Retropharyngeal lipomas often present with progressive dyspnoea and dysphagia [1, 2]. The patient in the present report had a 15 year history of sleep apnoea before retropharyngeal lipoma was diagnosed. Diagnosis is often made by CT scan, which also helps in delineating the extent of the lesion [2–4]. CT studies show a low attenuation related to fat tissue ranging between -50 to 150 Hounsfield units². Histopathological examination is confirmatory. Surgery is the treatment of choice [1, 3]. Orotracheal intubation may sometimes be difficult. In such cases preliminary tracheostomy would help anesthesia. The retropharyngeal space can be approached through three routes namely per oral, anterior and posterior external. Transoral approach with a vertical incision over posterior pharyngeal wall is the preferred method [2]. Although, the malignant potential of lipoma is low, these tumors need to be surgically excised if they produce life-threatening symptoms. Observation and serial imaging has been recommended as a safe alternative when surgical morbidity is high.

Conclusion

Lipomas of the retropharyngeal space are rare and often attain significant size before causing life-threatening

symptoms. CT scan is the imaging modality of choice in diagnosis of retro pharyngeal lipomas.. Surgical excision is the treatment of choice.

References

1. Shivakumar A.M, Naik A.S, Shetty D.K Yogesh B S (2004) Lipoma of the retropharyngeal space. *Indian J Paediatr* 71(3): 271–272
2. Hockstein N.G, Anderson T.A, Moonis G Gustafson K S, Mirza N (2002) Retropharyngeal lipoma causing obstructive sleep apnea: case report including five years follow-up. *Laryngoscope* 12(9):1603–1605
3. Akhtar J, Shaykhon M, Crocker J, D'Souza A R (2001) Retropharyngeal lipoma causing dysphagia. *Eur Arch Otorhinolaryngol* 258(9):458–459
4. Chandermohan, Mashankar A.S, Sharma O.P, Merchant N H (1991) Retropharyngeal lipoma. *Indian J Cancer* 28(3): 162–164