

Adenocarcinoma of the Duodenum Arising in a Tubulo-Villous Adenoma

A.-C. Lemyé, V. Guy-Viterbo, E. van Vyve

Department of Surgery, Saint Jean Clinic, Brussels, Belgium.

Key words. Villous tumour, duodenum ; adenocarcinoma, small bowel.

Abstract. Villous adenoma of the duodenum is rare and has a high prevalence of cancer. We report here an unusual case of a 73-year-old man who presented with a tumour on the second part of the duodenum with moderate dysplasia of a tubulo-villous adenoma at the biopsies. A segmental duodeno-jejunal resection was performed and the resection margins were negative. The final histological analysis was a moderately differentiated invasive duodenal adenocarcinoma (pT3Nx). Management of these tumours is discussed here.

Introduction

Villous adenoma of the duodenum is a rare entity among small bowel neoplasms (1, 2, 4, 6, 7). Most of the time, this tumour is diagnosed late. Symptoms are variable, from dyspepsia to obstruction or jaundice (1-4, 6). The main problem is the co-existence of malignancy, present in 21% to 47% of these tumours (3,6), which can be missed at the histological examination of biopsies by esophagogastroduodenoscopy (EGD) (3, 4, 8). Thus, different ways of managing these tumours exist and are still debated. We report here, a case of a 73-year-old man who presented with an adenocarcinoma arising from a tubulo-villous adenoma.

Case report

A 73-year-old man was admitted with vomiting, solid dysphagia and a six kilogramme weight loss during the previous two months. His medical history included oesophagitis, arterial hypertension, left ventricular hypertrophy and prostatism, but there was no bowel pathology in his family. The physical examination, the blood tests and tumour markers were normal. The EGD detected a stenosis of the D2-D3 junction, a sliding hiatal hernia, grade C oesophagitis and Barrett's image without dysplasia. The biopsies revealed a moderate duodenal dysplasia with no infiltrating tumour. The abdominal CT (computed tomography) demonstrated a 3 cm hemi-circumferential duodenal thickening of the inferior genus without periduodenal infiltration. The upper gastrointestinal contrast study (UGI) confirmed this circumferential ulcero-nodular lesion of the distal part of D2 (Fig. 1). An endoscopic ultrasonography (EUS) showed no regional lymphadenopathy but revealed a mass in the

D3, located in the mucosa and spreading into the sub-mucosa. The patient underwent an exploratory median laparotomy. The mass was found between D2 and D3. A cholecystectomy with cholangiography was made to confirm the position of the papilla above the upper part of the lesion, which was located 3 cm below. A segmental duodeno-jejunal resection (DJR) was performed starting from D2 to the second jejunal loop. This surgical option was decided upon in order to preserve the pancreatic head. The intra-operative pathological examination of the proximal margin shows moderate dysplasia. A wider resection conserving the papilla was performed. The specimen re-examination was negative and an end-to-side duodeno-jejunal anastomosis was made. A post-operative UGI control did not show any leakage and biology was normal. The final pathological diagnosis received five days later was unexpected : D2 adenocarcinoma with moderate differentiation (1 cm invasive lesion arising from a 3.5 cm-length tubulo-villous adenoma, located on all the duodenal circumference, with a low grade dysplasia) (Fig. 2). The staging was pT3 Nx. The oncologic staff opted for a follow-up since the resection was complete with negative margins.

Discussion

Small bowel tumours are rare (5). Duodenal neoplasms represent approximately one third of all benign and one fifth of all malignant small bowel tumours (7). 52% of the duodenal neoplasms are malignant and 90% are adenocarcinomas (1). Villous adenomas account for 1% of all duodenal neoplasms (6). The female : male ratio is 1:1 to 1.6:1 with an average age of 60.1 years (1-4, 6, 8). Familial adenomatous polyposis and Gardner and Peutz-Jeghers syndrome constitute risk factors for the develop-

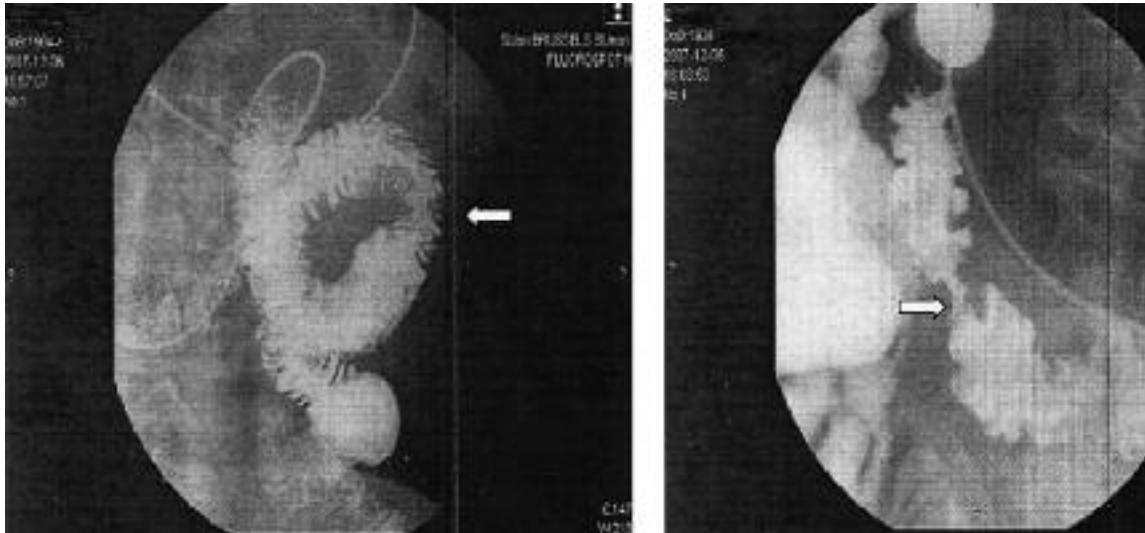


Fig. 1

The upper gastro-intestinal contrast study showed a 3 cm-long hemi-circumferential tumour of the distal part of D2

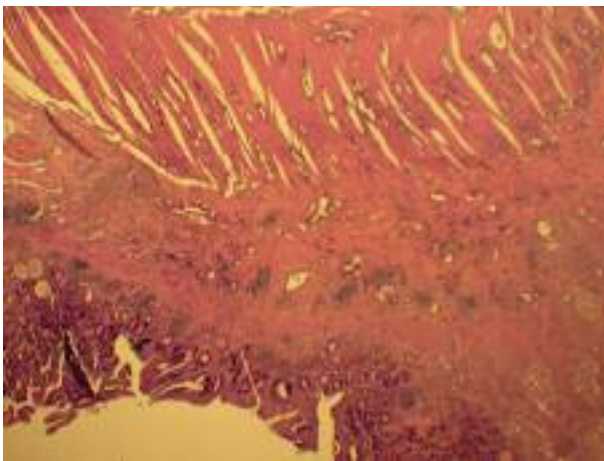


Fig. 2

Tubulo-villous adenoma of the duodenum with lesions of adenocarcinoma into the submucosa.

ment of these tumours (3-8). The most frequent symptoms are nausea, vomiting, weight loss, anorexia, as in our patient and also epigastric pain, jaundice, melena or fever. However, some patients are totally asymptomatic (1-4, 6). The examinations of choice are EGD, endoscopic retrograde cholangiopancreatography, UGI, abdominal CT and EUS. But, sometimes, the final diagnosis is only done during the surgery. Malignancy occurs inside the lesion with a 30-50% rate. Cell atypia is found in 30% of the patients, in situ carcinoma in 14% and invasive carcinoma in 33% (6). The problem is that

malignancy can be missed on the EGD biopsy, as in this case. Up to 40% of false negative are reported (2) and multiple biopsies or complete excision may be required for an accurate diagnosis (1, 3, 4, 7). Because of their malignancy rate and the possibility of misdiagnosis, some authors propose to consider all these tumours as malignant until proven otherwise (3). Criteria such as patient age (> 50 years), presence of jaundice and growth shape (ulceration or intraluminal protrusion) are associated with a higher suspicion of an aggressive tumour (2, 4, 6, 7). Here we had 2 of these criteria. But if this pathological diagnosis could be detected during the surgical procedure, a wider resection, such as a pancreaticoduodenectomy (PD) should be performed rather than a DJR. Several approaches of the treatment are still debated (1-4, 6). An individualised treatment based on symptoms, tumour location, size and extension, presence and stage of adenocarcinoma and the medical status of the patient must be taken into account (4, 8). The possible techniques are endoscopic resection, transduodenal submucosal excision, segmental DJR, PD and when the tumour is not resectable or when the disease is not curable, a palliative procedure can be adopted (biliary-enteric bypass and/or gastro-enterostomy) (3, 4, 6). The endoscopic technique is adequate for benign and pediculated lesions but has some limitations (3, 4). Local excision is recognised as being suitable for treating benign neoplasms and the in situ (stage T1) adenocarcinomas. The most recent recurrence rates are 32% and 43% at 5 and 10 years (7). This means that a regular endoscopic surveillance should be performed in order to detect these recurrences. Patients with invasive adenocarcinoma, like our patient, should be treated by PD. The question that is still contro-

versial is whether we should treat all the patients suffering from duodenal villous adenomas and who are fit for the surgery with PD. The main reasons are the rate of recurrence, the pre-operative difficulty in differentiating benign from malignant lesions and the necessity for a complete excision of the tumour (4, 7). BAKAEEN *et al.* (8) compare the 5-year survival rate in patients who underwent radical or limited resection with negative margin (R0) for duodenal adenocarcinoma. They do not find any difference, around 60% in both groups, but the local recurrence is higher in the second group. In fact, the lymphatic drainage of the distal portion of the duodenum is into the small bowel mesentery and not via the pancreaticoduodenal lymphatic basin removed by PD. They therefore propose to make a PD when the mass is on D1 or D2 and a DJR for selected patients, especially with distal lesions (8). Another debate is whether we should give adjuvant treatment like radiotherapy and/or chemotherapy (RT-CT) ? Unfortunately, the 5-year risk of recurrence for R0 patients is 40%. A recent study show that patients undergoing R0 resection with CT-RT, 5-year survival and local control were 83% and 89% respectively which compares with surgery alone. However, the number of patients was limited and larger studies should be done (9).

References

1. KUTIN N. D., RANSON J. H. C., GOUGE T. H., LOCALIO S. A. Villous tumours of the duodenum. *Ann Surg*, 1975, **181** : 164-168.
2. CHAPPUIS C. W., DIVINCENTI F. C., COHN I. Villous tumours of the duodenum. *Ann Surg*, 1989, **209** : 593-598.
3. GALANDIUK S., HERMANN R. E., JAGELMAN D. G., FAZIO V. W., SIVAK M. V. Villous tumours of the duodenum. *Ann Surg*, 1988, **207** : 234-239.
4. RYAN D. P., SCHAPIRO R. H., WARSHAW A. L. Villous tumours of the duodenum. *Ann Surg*, 1986, **203** : 301-306.
5. PENNAZIO M. Adenocarcinoma of the small bowel. *Acta Endoscopica*, 2005, **35** : 179-185.
6. McFARLANE M. E. C. Villous tumours of the duodenum : a report of a case and review of the literature. *J Hepatobiliary Pancreat Surg*, 2001, **8** : 107-109.
7. CAVALLINI M., CAVANIGLIA D., FELICIONI F., VITALE V., PILOZZI E., ZIPARO V. Large peri-ampullary villous tumour of the duodenum. *J Hepatobiliary Pancreat Surg*, 2007, **14** : 526-528.
8. BAKAEEN F. G., MURR M. M., SARR M. G. *et al.* What prognostic factors are important in duodenal adenocarcinoma ? *Arch Surg*, 2000, **135** : 635-642.
9. KELSEY C. R., NELSON J. W., WILLET C. G. *et al.* Duodenal adenocarcinoma : patterns of failure after resection and the role of chemoradiotherapy. *Int J Radiat Oncol Biol Phys*, 2007, **69** : 1436-1441.

Dr. A.-C. Lemyé
Cours St Michel 98, bte 28
B-1040 Bruxelles, Belgium
E-mail : aclemye@hotmail.com