

Case Report

Occipital Neurostimulation-Induced Muscle Spasms: Implications for Lead Placement

Salim M. Hayek, MD, PhD¹, Joseph F. Jasper, MD², Timothy R. Deer, MD³,
and Samer N. Narouze, MD⁴

From: ¹Division of Pain Medicine, Department of Anesthesiology, University Hospitals of Cleveland, Case Western Reserve University, Cleveland, OH; Outcomes Research Consortium; ²Advanced Pain Medicine Physicians, Tacoma, WA; ³The Center For Pain Relief, Charleston, West Virginia; ⁴Department of Pain Management, Cleveland Clinic Foundation, Cleveland, OH.

Address correspondence:
Salim M Hayek, MD, PhD
11100 Euclid Avenue
Cleveland OH 44106
E-mail:
Salim.hayek@UHospitals.org

Disclaimer: There was no external funding in the preparation of this manuscript.

Conflict of interest: Dr. Deer is a consultant for St. Jude Medical, Minneapolis, MN. Dr. Hayek is a consultant for Boston Scientific, Valencia, CA. Dr. Narouze is a consultant for Medtronic, Minneapolis, MN.

Manuscript received: 03/27/2009
Revised manuscript received:
05/06/2009
Accepted for publication:
07/24/2009

Free full manuscript:
www.painphysicianjournal.com

Background: For many headache types, occipital peripheral nerve stimulation (ONS) provides significant relief of chronic, frequent, and severe headaches. Though rarely reported, ONS may cause painful muscle spasms that make stimulator use impractical. The classic description of the technique advocates placement of the leads transversely at the level of the arch of C1 or at C1-2. At that level, the greater occipital nerve (GON) infrequently pierces the superficial fascia of the neck muscles to become superficial. However, important anatomic variability exists.

Objective: To report placement of leads higher at the nuchal line rather than the classically recommended C1 level to avoid ONS-induced muscle spasm.

Methods: Four interventional pain physicians independently revised ONS leads due to painful muscle stimulation. Five case reports of surgical ONS lead revision for management of ONS-induced muscle spasms are described and discussed.

Results: Placement of peripheral neurostimulator leads at or above the nuchal line in these 5 cases provided good paresthesiae without causing neck muscle spasm.

Conclusion: Lead placement at the level of C1 or C1-2 may cause some patients to have intolerable neck/occipital spasm during neurostimulation. This is the first known published report of technical variation in the location of lead placement, at the nuchal line in a transverse fashion, for ONS. Placing ONS leads at the level of the occipital protuberance appears to eliminate ONS-induced muscle spasm while allowing good paresthesia coverage.

Limitations: Stimulation parameters vary, thus posting parameters may be misleading as muscle spasms occurred despite multiple reprogramming attempts and were a function of lead position, not program settings.

Key words: Occipital nerve stimulator, peripheral neurostimulation, muscle spasm, complication, interventional pain management, cephalgia, headache, migraine, occipital neuralgia, greater occipital nerve

Pain Physician 2009; 12:867-876

Occipital neurostimulation, also known as greater occipital nerve (GON) stimulation, is a minimally invasive form of peripheral nerve stimulation that has been used in the management of chronic severe headache disorders. Occipital nerve stimulation (ONS) has been used successfully

in the treatment of a number of headache entities including occipital neuralgia (1-5), cervicogenic headache (6,7), migraine (8), transformed migraine (4,9-11), hemicrania continua (8-11), cluster headache (8,11-17), post-traumatic (8), C2-mediated headaches (3,18) and occipital region pain after surgery (3,6,19).

The ONS leads are implanted in the superficial dermal layers at the occipito-cervical junction. ONS is believed to work by stimulating distal branches of the C2 and C3 nerves, those of the greater and lesser occipital nerves. Proximally, these nerves synapse onto second order neurons that are part of the trigeminocervical complex (20,21), hence providing an anatomic and physiologic basis for the headache and its treatment by stimulation. The current practice of occipital neurostimulation has followed the original description of the technique by Weiner in 1999 (5). The technical aspects of implantation were recently reviewed extensively (22); however, all descriptions thus far involve placement of the leads subcutaneously at the C1 level. The stimulator lead can be directed medially from a lateral entry point medial and inferior to the mastoid process (3-5,16,18,23,24) or laterally from a midline entry point (1,2,6,13,18,25-27). Complications do occur and involve lead migration, lead fracture or disconnect, lead tip erosion, infection, unpleasant stimulation, and localized pain at implant sites (22,23,28,29). Another complication that can lead to failure of the system is unpleasant muscle recruitment causing spasm in the neck or occipital region. Patients are unable to benefit from neurostimulation when neck muscles are recruited by the stimulating current at a threshold below or near that needed for activation

of the occipital nerve branches. This article discusses the occurrence of ONS-related neck muscle spasms in 5 patients from 4 different practices who were managed successfully by revision of the leads to a level just above the nuchal ridge. Technical recommendations for avoidance of such complications are given.

CASE 1

A 46-year-old thin white male presented with 10 years of chronic daily headache with bilateral occipital pain. There was no known trauma. He was extensively trialed on a variety of medications by his neurologist. Headaches were daily of varying intensity from moderate to severe. He was taking sumatriptan about 15 days per month. The patient expressed a desire to find an alternative to medications. His neurological examination and imaging was within normal limits and he had a favorable psychological evaluation.

Initial trial was performed with 2 regular Medtronic quadripolar leads placed posterior to the arch of C1. He felt relief and was able to stop using his medications. Permanent implantation followed with quadripolar paddle arrays (Medtronic Resume II®) bilaterally (Fig. 1A) and a rechargeable pulse generator (Medtronic Restore Ultra®). Ten days post-operatively the patient complained of posterior neck muscle spasm that occurred whenever stimulation was turned on.

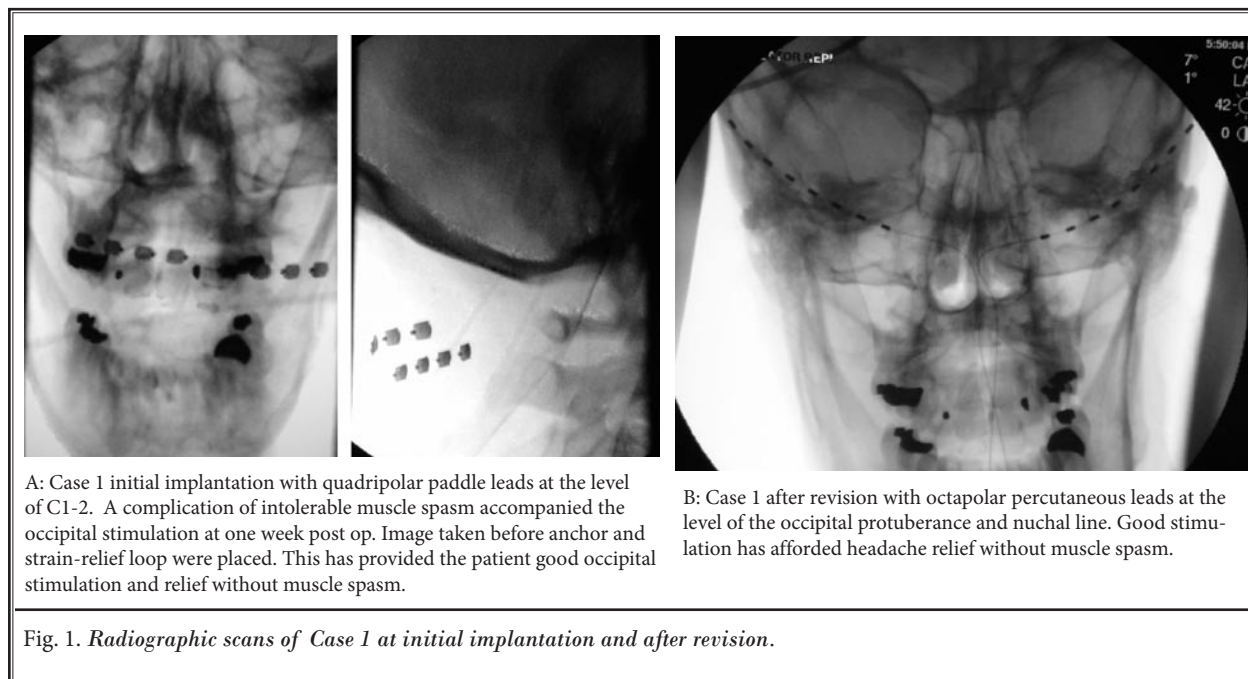


Fig. 1. Radiographic scans of Case 1 at initial implantation and after revision.

Multiple programming parameters were manipulated with inadequate improvement; this included various trials of pulse width (PW) 150–450, rate 35–150, contact polarity, and amplitude.

Revision (Fig. 1B) was performed by explanting the 2 paddle lead arrays and replacing them with regular spaced octapolar arrays (Medtronic PISCES Octad®). At 3 months post revision, the patient is reporting moderate relief and better coverage than he had experienced with either the trial or the paddle leads. His medication use is now infrequent, less than once weekly with only Imitrex.

CASE 2

A 25-year-old woman presented to the neurology service for unremitting headaches and neck pain. Her symptoms started following a motor vehicle accident and whiplash injury at the age of 18. Since the accident, she has complained of right-sided cervicogenic headaches with pain radiating from her neck up to the head and also down to her right shoulder area. Neurologic exam was within normal limits. She had mild decrease in the range of motion of the cervical spine and tenderness over the right upper cervical facets. Extensive diagnostic and radiologic workup was within normal limits. She has had a number of interventions including trigger point injections, greater occipital nerve blocks, right atlantoaxial joint injection, facet medial nerve blocks, and one radiofrequency lesioning with partial and short-lasting relief. The pain was interfering with the patient's activities of daily living. Psychological evaluation revealed no contraindications to neurostimulation. The patient underwent a trial of occipital nerve stimulation with the classic C1 level entry medial to the right mastoid using dual compact octapolar leads (5). The trial leads were maintained for one week. The patient reported a remarkable decrease in the number of headache episodes and intensity of the pain, an improvement of > 80%. The leads were discontinued with the plan of implantation at a later date.

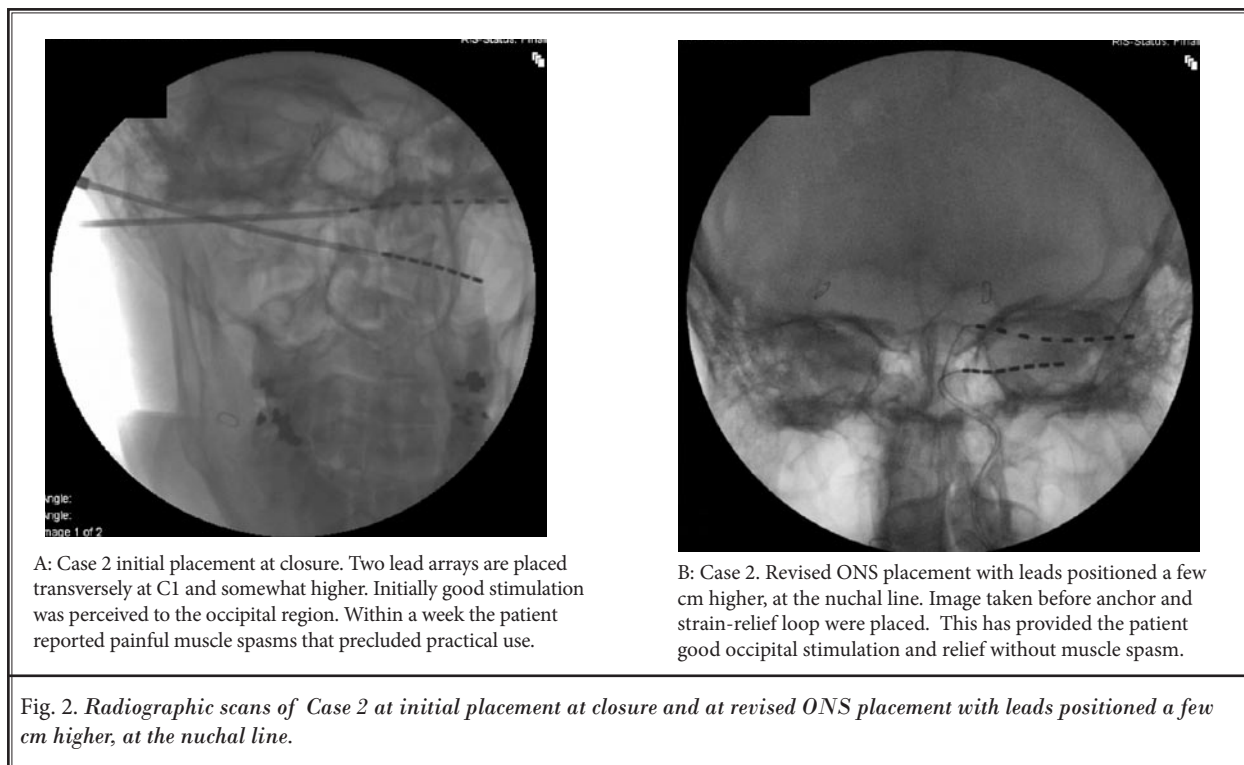
The patient presented for implant one month later but requested that the generator not be placed in the right infraclavicular region for cosmetic reasons. The operation was carried out under monitored anesthetic care. A midline sagittal incision was carried out longitudinally at the level of C1 and a compact lead (Medtronic Neurological, Minneapolis, Minnesota) was advanced subcutaneously in a horizontal di-

rection at a depth of about 1 cm. A subcompact lead (Medtronic Neurological, Minneapolis, Minnesota) was advanced in a caudolateral direction to cover a more caudad area of neck pain (Fig. 2A). Stimulation with the subcompact lead resulted in only local coverage. The patient had good headache relief for about a week but then started experiencing posterior upper neck muscle contractions when she increased the current stimulation to levels required for occipital paresthesiae. Despite multiple reprogramming attempts, the problem persisted and the patient eventually underwent a surgical revision. The midline longitudinal scar was re-opened and extended cephalad to the occipital protuberance. Both leads were freed from the anchors and pulled back. Two parallel 14-gauge introducer needles were inserted on the right side from a point about 10 cm lateral to the upper aspect of the midline incision and advanced over the periosteum until the needles exited through the upper aspect of the wound at the level of the occipital protuberance. The compact and subcompact octapolar leads were then introduced through the needles and the needles were removed leaving the leads at the level of the nuchal ridge (Fig. 2B). Stimulation of either lead resulted in rostral spread of paresthesiae to the vertex in the absence of muscle contractions. The patient has had good paresthesiae coverage without ONS-induced muscle spasms since the revision, over 5 months ago.

CASE 3

A 28-year-old white female presented with severe occipital neuralgia that occurred in the afternoon and usually progressed to a severe migraine headache one to 2 hours later. The patient had headaches that were disabling more than 20 days per month. She had been evaluated by 4 neurologists, and treated by a nationally prominent headache center with 2 research protocols. Unfortunately, despite the use of antidepressants, anticonvulsants, triptans, and opioids her pain persisted. She underwent cervical facet injections and pulsed radiofrequency of the C2 dorsal root ganglion. After failing these interventions she underwent 10 injections of the occipital nerves with temporary relief.

At this point she was referred for consideration of an occipital nerve stimulation system to treat her C2 induced migraines. The patient underwent a trial of stimulation at the C1 level using the classic approach described by Weiner (5) with 2 widely spaced quadripolar leads (Medtronic Neurological, Minneapolis,



Minnesota). The stimulation gave a 60 to 70% reduction in pain by the visual analog scale and she was determined by psychology to be an acceptable candidate for the permanent device.

The permanent percutaneous leads were placed by a medial approach at the C1 level as determined by fluoroscopy and connected to an implanted generator (Synergy, Medtronic Neurological, Minneapolis Minnesota). The stimulation pattern was excellent for a 3-day period, but unfortunately and with use of neurostimulation, she developed painful spasm of the neck and occiput that made it intolerable to use the device. Reprogramming was attempted with the addition of more cathodes to spread the current, but this was unsuccessful in reducing the problem.

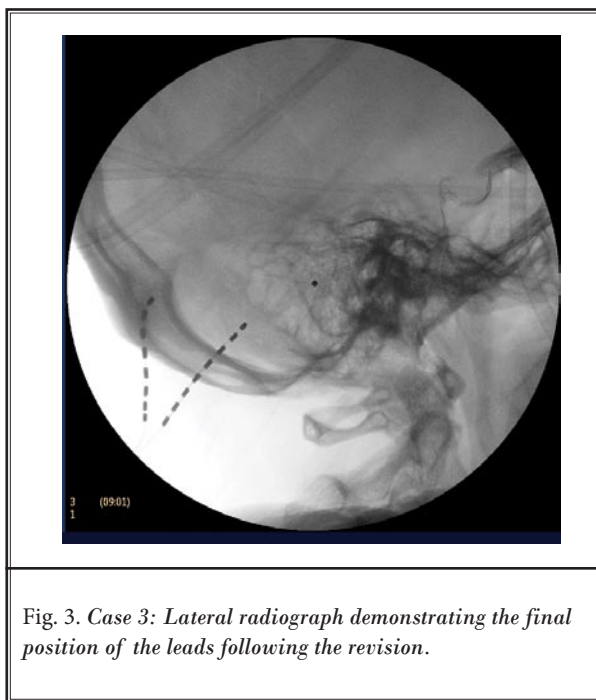
The patient underwent surgical revision whereby the midline incision was extended cephalad to just below the nuchal ridge. The previously implanted leads and generator were removed and a curved 14-gauge needle was used to achieve a percutaneous lead placement above the nuchal line lateral to the distribution of the greater and lesser occipital nerves. The leads were normally spaced octapolar arrays (Octad, St. Jude Medical, Minneapolis, MN). The leads were just below the dermis in the subcutane-

ous fat, and relatively superficial to the fascia (Fig. 3). The leads were screened on the table and excellent stimulation was obtained that was felt to be superior to the previous implant or the previous trial period. The leads were secured without an anchor using a combination of 3.0 nylon sutures to fasten them to the fascia. The generator was placed in the left infraclavicular region based on patient preference. The patient did well post operatively using the device 24 hours per day and at 24 months follow up was off all medications and averaged one to 2 occipital based headaches per month, treated by rest and increased amplitude of stimulation.

CASE 4

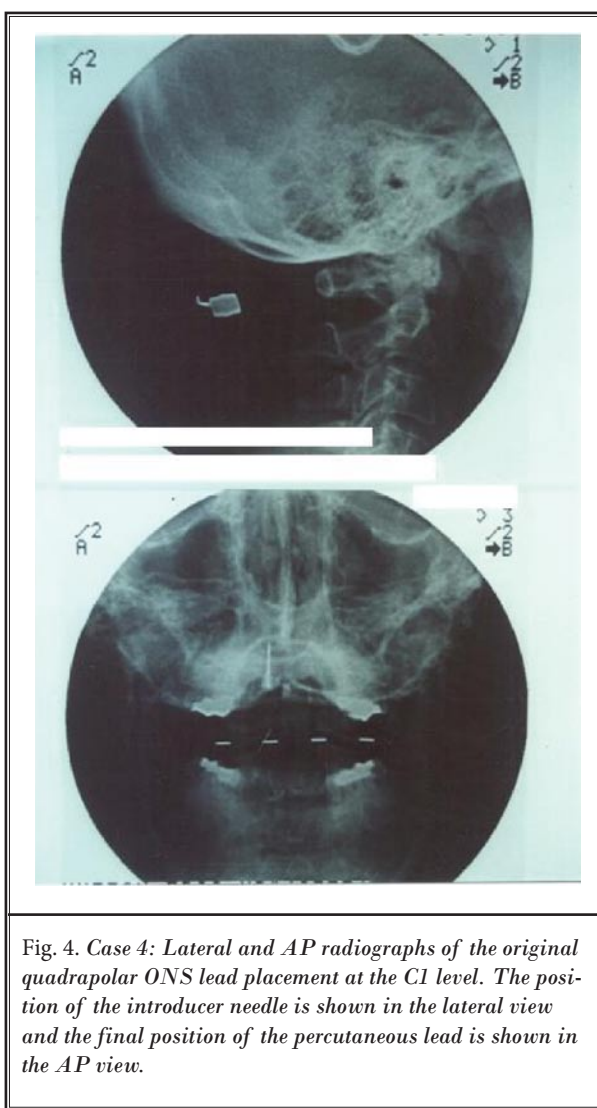
A 44-year-old man was struck in the neck and head by a beam while performing mine roof bolting. He recovered from a compression fracture of C2 with conservative management, but developed severe daily occipital headaches. The patient did not tolerate any medications orally, continued to work full time but was considering disability, and rated his quality of life as "very poor" with the need to stay in bed 12 to 14 hours a day.

He had no response to muscle injections, cervical



epidurals, or cervical facet injections. He did respond to injections of the occipital nerve, but only for a few hours despite the addition of dexamethasone and triamcinolone.

He underwent a single lead occipital nerve stimulation trial at the level of C1 with good response resulting in relief bilaterally. The permanent system was placed with a widely spaced quadripolar lead at the C1 level giving good stimulation in the operating room (Fig. 4). A generator was placed at above the belt line (Restore Ultra, Medtronic Neurological, Minneapolis, MN). Over the next 72 hours, he developed severe spasm of the neck with activation of the leads. The patient was taken back to the operating room and the lead was repositioned in the same area under local anesthesia without resolution of the problem. A new incision was made just below occipital prominence and 2 14-gauge needles were placed just above the nuchal line laterally where 2 octapolar leads were placed (Octad, St. Jude Medical, Minneapolis, MN). The leads were secured with 0 nylon sutures without the use of commercial anchors. The generator was placed in the area of the fatty tissue just above the trapezius muscle (Mini Eon, St. Jude Medical, Minneapolis, MN). At 6-month follow-up the patient rated his pain reduction at 90% with continued ability to work and function.



CASE 5

A 42-year-old female presented with right-sided chronic unilateral intractable migraines. She had failed other conservative modalities of treatment. She underwent a successful ONS trial at the level of C1 with a Medtronic percutaneous octapolar lead for 7 days with no headaches noted during the trial period (she used to have migraines daily). She proceeded with the permanent implant with the same lead (Medtronic Neurological, Minneapolis, MN) and during surgery she had appropriate paresthesiae without muscle contractions. Following implant, the patient was very pleased

during the first 2 weeks having no headaches. She then noticed that the paresthesiae were becoming faint and she started to get breakthrough headaches. Occipital neurostimulation with weak paresthesiae would not control the headaches. She had the ONS reprogrammed to higher settings in an effort to recapture stronger paresthesiae and headache control. On increasing voltage, strong paresthesiae similar to those of the trial and early implant period were elicited, however, the patient started to complain of uncomfortable muscle spasms in the suboccipital region. Higher current amplitude delivery resulted in worse spasms which were visible and palpable in the suboccipital region. Eventually, she underwent a revision with the new lead placed subcutaneously at the level of the insertion of the trapezius muscle at the nuchal line. Intraoperatively she reported good paresthesiae at lower voltages than the original implant. Increasing current, even to the discomfort threshold, would not induce muscle contractions or spasms. She has continued to do well since revision, experiencing 2-3 migraines/month for the following year (to date). These breakthrough headaches are less severe than her usual ones and are easily manageable with medications. She continues to work full time.

Discussion

Complications are dreaded consequences of any procedure, detracting from the value of the intervention. Current technical descriptions of ONS dictate lead placement in the subcutaneous tissues at the level of C1. Placing the leads too superficially risks failure of nerve stimulation and lead erosion through the skin or patients experiencing burning sensations that are unpleasant. On the other hand, leads placed too deep risk stimulating posterior neck muscles and causing unpleasant muscle spasms. End points for appropriate lead depth and technical guidance in the literature have not been clearly defined. The rationale for choosing C1 level as the target for subcutaneous stimulation has not been expounded, although this is the classic location first published in the peer reviewed literature.

The GON arises from the dorsal primary rami of C2 and usually circumvents the inferior oblique muscle of the head, passing around it. It then most often penetrates through the semispinalis capitis and variably penetrates through the trapezius muscle fibers at or inferior to its occipital insertion (Fig. 5) (30-32).

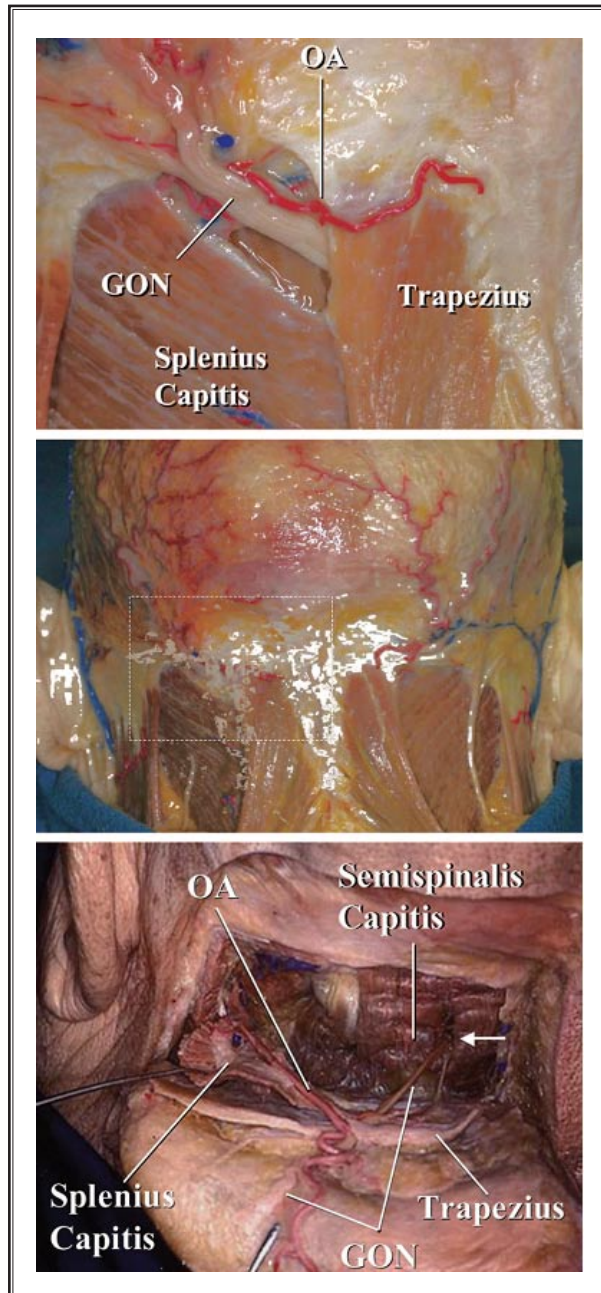

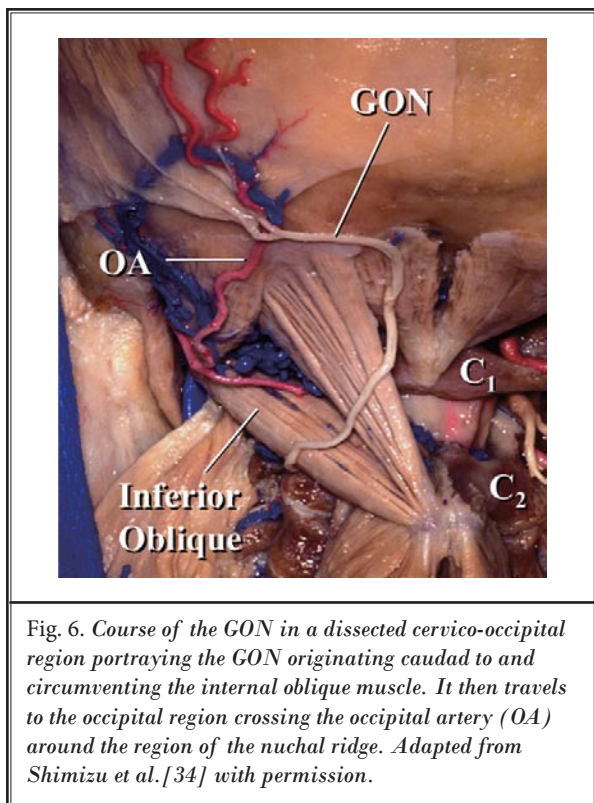


Fig. 5. Anatomical relationship of the greater occipital nerve (GON) to the occipital artery branch (OA) and adjacent muscles in the cervico-occipital region. Retraction of the trapezius and splenius capitis muscles shows the occipital artery running beneath the splenius capitis muscle and the GON piercing the semispinalis capitis muscle (arrow). Reproduced with permission from Shimizu et al (34).



While Bovim and colleagues (30) found that the GON pierces the trapezius in nearly half the subjects, others have described a much lower likelihood of penetration of the trapezius by the GON (31,32). Often, the GON was invested in the aponeurosis of the trapezius (31). In all the anatomic studies important anatomical variability was noted in the GON pathway. Along the intermastoid line, the GON surfaces from its overlying muscles between 5 mm and 28 mm from the midline. The lesser occipital nerve passes laterally to the greater occipital nerve over the nuchal ridge (33). In a recent anatomic study by Shimizu and colleagues (34), it was noted that the GON was always located superficial to the artery at the superior nuchal line (Fig. 6). The study by Becser et al (31), however, noted that the GON frequently formed a rich nerve network around a tortuous occipital artery and sometimes these complex vessel-nerve structures were embedded in the aponeurosis.

The GON penetrates the semispinalis capitis muscle fibers at a distance between 2 and 5 cm caudad to the occipital protuberance (Fig. 7) (30). More superficially and rostrally, it may penetrate additionally

the trapezius muscle fibers or aponeurosis, becoming superficial between 5 mm and 18 mm below the intermastoid line (31). Positioning the stimulator lead subcutaneously at the C1 level, places it at a significant distance from the nerve (Fig. 8) while overlying the muscles. Using fluoroscopy, the arch of C1 is located at an average distance of about 5 cm caudad to the level of the occipital protuberance. It is plausible then, that in order to achieve paresthesiae in the distribution of the GON, muscle fibers in this region are likely to be recruited including the semispinalis capitis, trapezius, and less likely the splenius capitis, sternocleidomastoid, levator scapula, and splenius cervicis.

The reasons for developing muscle spasm after a permanent ONS implant are not well understood. After implanting the ONS leads, and with resolution of the surgical edema and appearance of scarring around the lead, patients may require different stimulation settings. Usually, these are higher amplitude settings. As the stimulation voltage is increased in an attempt to obtain similar paresthesiae to those obtained during the ONS trial, nearby muscles may be recruited and muscle spasms may occur.

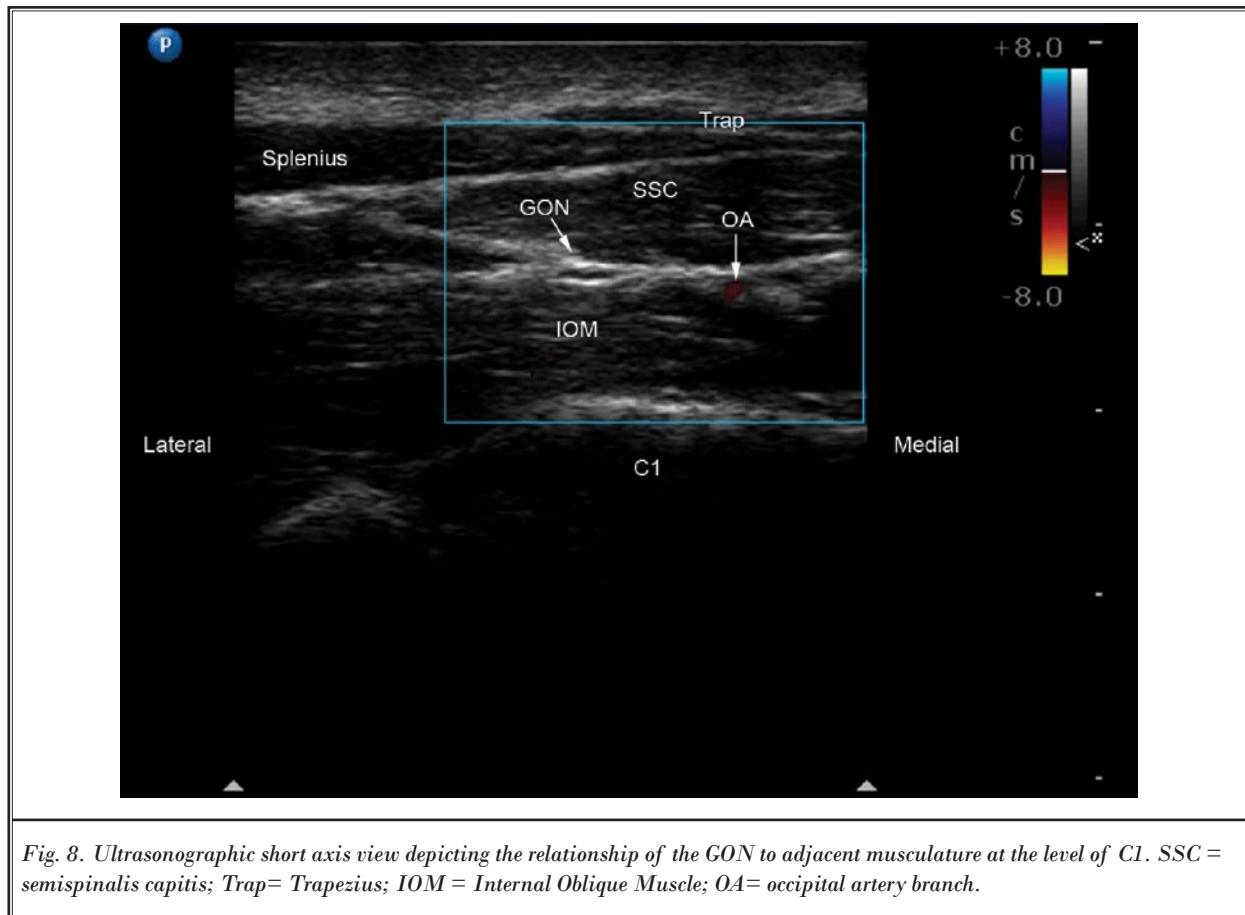


Fig. 8. Ultrasonographic short axis view depicting the relationship of the GON to adjacent musculature at the level of C1. SSC = semispinalis capitis; Trap= Trapezius; IOM = Internal Oblique Muscle; OA= occipital artery branch.

Tendons of these muscles arise caudad from the ridge of the nuchal line, the transverse nuchae; cranial originate the tendons of the occipital muscles. Lead placement adjacent to the nuchal line would be less prone to muscle stimulation. This premise is based on the anatomic precept that the nerve at the nuchal line level is not buffered from the lead current by intervening muscles nor are muscles lying immediately deep to the lead (Figs 9,10) and that stimulation of the aponeurosis is less likely to cause muscle contraction than stimulation over the contractile portion of the muscle. Hence, nerve stimulation is achieved without concomitant muscle activation.

Original reports of the procedure described using quadripolar leads, though recent technical and practice trends favor the use of octapolar leads. There are no comparative studies of quadripolar versus octapolar lead use in ONS. However, the added electrode contacts in the octapolar leads allow for exponentially

more stimulation configuration arrays. Additionally, longer octapolar leads may allow for better coverage of greater and lesser occipital nerve branches.

It is not known whether a paddle-type surgical lead would consistently work using this approach. Paddle-type leads deliver electric current in one direction whereas cylindrical percutaneous leads deliver current circumferentially. Two of the authors (SMH, TRD) have had 5 patients with a paddle-type lead implanted at the nuchal ridge level with excellent pain relief ranging from one to 5 years. Implanting leads at that level forces the clinician to drive the needle or implant the paddle close to the periosteum. However, the nerves appear to run deep at that level. Potential concerns include bleeding from the occipital artery, lead erosion, and the theoretical potential spread of an infection through emissary veins intracranially. Another potential concern with paddle-type leads is difficulty obtaining stimulation with unidirectional current.

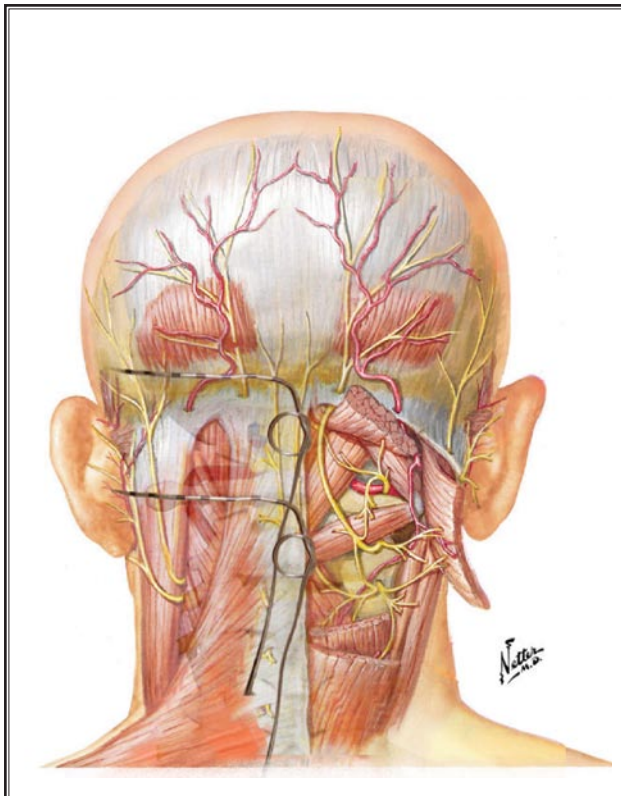


Fig. 9. Schematic depiction of the relationship of percutaneous occipital neurostimulator leads to the greater occipital nerve. The rostral lead is placed over the nuchal ridge and the caudal lead at the level of C1. Netter medical illustration used with permission of Elsevier. All rights reserved.

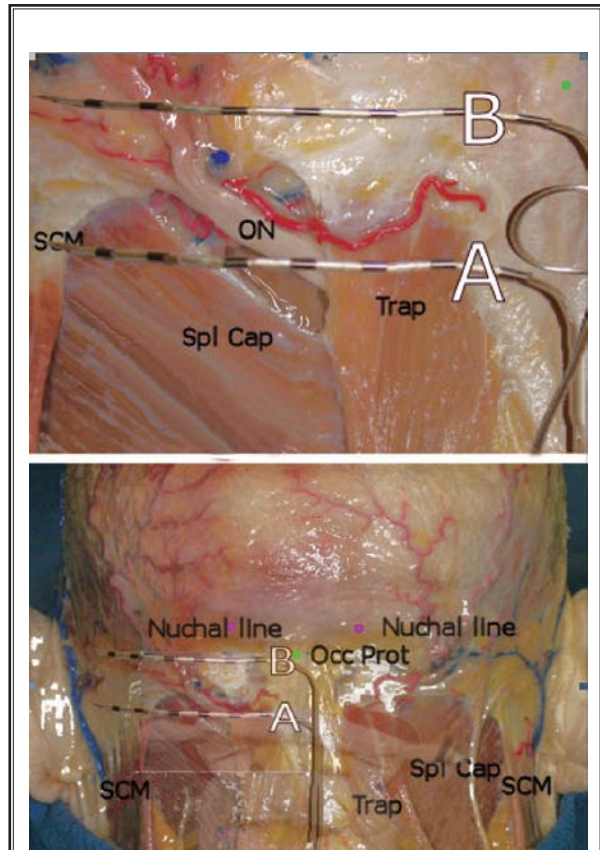


Fig. 10. Depiction of occipital neurostimulator leads obtained by overlaying lead images onto the anatomic dissection discussed in Fig. 5. Shimizu et al (34) medical illustrations used with the permission of Lippincott Williams & Wilkins (LWW).

CONCLUSION

The 5 case reports of ONS revision presented here exemplify an alteration to the approach recommended in the existing literature. Based on anecdotal discussion and lecture presentations, this is now common practice for some practitioners. The 5 cases presented are thus far successful. Long-term follow up is required to evaluate the efficacy and incidence of complications. A study that compares the C1 level to nuchal line level placement of lead arrays would be necessary to make conscionable recommendations. It is the hope of the authors that this article will give implanters of occipital neurostimulators pause in considering placement and treating complications associated with the classic C1 approach.

ACKNOWLEDGMENTS

The authors would like to recognize the efforts of Dr. Elias Veizi, MD, PhD, Case Western Reserve University, in securing permission of copyright material used in this manuscript

REFERENCES

1. Johnstone CSH, Sundaraj R. Occipital nerve stimulation for the treatment of occipital neuralgia-eight case studies. *Neuromodulation* 2006; 9:41-47.
2. Kapural L, Mekhail N, Hayek SM, Stanton-Hicks M, Malak O. Occipital nerve electrical stimulation via the midline approach and subcutaneous surgical leads for treatment of severe occipital neuralgia: A pilot study. *Anesth Analg* 2005; 101:171-174, table of contents.
3. Hammer M, Doleys DM. Perineuromal stimulation in the treatment of occipital neuralgia: A case study. *Neuromodulation* 2001; 4:47-51.
4. Oh MY, Ortega J, Bellotte JB, Whiting DM, Alo K. Peripheral nerve stimulation for the treatment of occipital neuralgia and transformed migraine using a c1-2-3 subcutaneous paddle style electrode: A technical report. *Neuromodulation* 2004; 7:103-112.
5. Weiner RL, Reed KL. Peripheral neurostimulation for control of intractable occipital neuralgia. *Neuromodulation* 1999; 2:217-221.
6. Rodrigo-Royo MD, Azcona JM, Quero J, Lorente MC, Acin P, Azcona J. Peripheral neurostimulation in the management of cervicogenic headache: Four case reports. *Neuromodulation* 2005; 8:241-248.
7. Martelletti P, van Suijlekom H. Cervicogenic headache: Practical approaches to therapy. *CNS Drugs* 2004; 18:793-805.
8. Schwedt TJ, Dodick DW, Hentz J, Trentman TL, Zimmerman RS. Occipital nerve stimulation for chronic headache--long-term safety and efficacy. *Cephalalgia* 2007; 27:153-157.
9. Burns B, Watkins L, Goadsby PJ. Treatment of hemicrania continua by occipital nerve stimulation with a bion device: Long-term follow-up of a crossover study. *Lancet Neurol* 2008; 7:1001-1012.
10. Goadsby PJ. Neurostimulation in primary headache syndromes. *Expert Rev Neurother* 2007; 7:1785-1789.
11. Schwedt TJ, Dodick DW, Trentman TL, Zimmerman RS. Occipital nerve stimulation for chronic cluster headache and hemicrania continua: Pain relief and persistence of autonomic features. *Cephalalgia* 2006; 26:1025-1027.
12. Ambrosini A. Occipital nerve stimulation for intractable cluster headache. *Lancet* 2007; 369:1063-1065.
13. Burns B, Watkins L, Goadsby PJ. Treatment of medically intractable cluster headache by occipital nerve stimulation: Long-term follow-up of eight patients. *Lancet* 2007; 369:1099-1106.
14. Burns B, Watkins L, Goadsby PJ. Treatment of intractable chronic cluster headache by occipital nerve stimulation in 14 patients. *Neurology* 2009; 72:341-345.
15. Leone M, Franzini A, Cecchini AP, Broggi G, Bussone G. Stimulation of occipital nerve for drug-resistant chronic cluster headache. *Lancet Neurol* 2007; 6:289-291.
16. Magis D, Allena M, Bolla M, De Pasqua V, Remacle JM, Schoenen J. Occipital nerve stimulation for drug-resistant chronic cluster headache: A prospective pilot study. *Lancet Neurol* 2007; 6:314-321.
17. Magis D, Schoenen J. Neurostimulation in chronic cluster headache. *Curr Pain Headache Rep* 2008; 12:145-153.
18. Melvin EA, Jr., Jordan FR, Weiner RL, Primm D. Using peripheral stimulation to reduce the pain of C2-mediated occipital headaches: A preliminary report. *Pain Physician* 2007; 10:453-460.
19. Ghaemi K, Capelle HH, Kinfe TM, Krauss JK. Occipital nerve stimulation for refractory occipital pain after occipitocervical fusion: Expanding indications. *Streeotact Funct Neurosurg* 2008; 86:391-393.
20. Le Doare K, Akerman S, Holland PR, Lalsandra MP, Bergerot A, Classey JD, Knight YE, Goadsby PJ. Occipital afferent activation of second order neurons in the trigeminocervical complex in rat. *Neurosci Lett* 2006; 403:73-77.
21. Piovesan EJ, Di Stani F, Kowacs PA, Mulinari RA, Radunz VH, Utiumi M, Muranka EB, Giublin ML, Werneck LC. Massaging over the greater occipital nerve reduces the intensity of migraine attacks: Evidence for inhibitory trigemino-cervical convergence mechanisms. *Arq Neuropsiquiatr* 2007; 65:599-604.
22. Trentman TL, Zimmerman RS. Occipital nerve stimulation: Technical and surgical aspects of implantation. *Headache* 2008; 48:319-327.
23. Slavin KV, Nersesyan H, Wess C. Peripheral neurostimulation for treatment of intractable occipital neuralgia. *Neurosurgery* 2006; 58:112-119; discussion 112-119.
24. Slavin KV, Colpan ME, Munawar N, Wess C, Nersesyan H. Trigeminal and occipital peripheral nerve stimulation for craniofacial pain: A single-institution experience and review of the literature. *Neurosurg Focus* 2006; 21:E5.
25. Popeney CA, Alo KM. Peripheral neurostimulation for the treatment of chronic, disabling transformed migraine. *Headache* 2003; 43:369-375.
26. Schwedt TJ, Dodick DW, Trentman TL, Zimmerman RS. Response to occipital nerve block is not useful in predicting efficacy of occipital nerve stimulation. *Cephalalgia* 2007; 27:271-274.
27. Jones RL. Occipital nerve stimulation using a medtronic resume II electrode array. *Pain Physician* 2003; 6:507-508.
28. Jasper JF, Hayek SM. Implanted occipital nerve stimulators. *Pain Physician* 2008; 11:187-200.
29. Trentman TL, Dodick DW, Zimmerman RS, Birch BD. Percutaneous occipital stimulator lead tip erosion: report of 2 cases. *Pain Physician* 2008; 11:253-256.
30. Bovim G, Bonamico L, Fredriksen TA, Lindboe CF, Stolt-Nielsen A, Sjaastad O. Topographic variations in the peripheral course of the greater occipital nerve. Autopsy study with clinical correlations. *Spine* 1991; 16:475-478.
31. Becser N, Bovim G, Sjaastad O. Extracranial nerves in the posterior part of the head. Anatomic variations and their possible clinical significance. *Spine* 1998; 23:1435-1441.
32. Mosser SW, Guyuron B, Janis JE, Rohrich RJ. The anatomy of the greater occipital nerve: implications for the etiology of migraine headaches. *Plast Reconstr Surg* 2004; 113:693-697; discussion 698-700.
33. Gawel MJ, Rothbart PJ. Occipital nerve block in the management of headache and cervical pain. *Cephalalgia* 1992; 12:9-13.
34. Shimizu S, Oka H, Osawa S, Fukushima Y, Utsuki S, Tanaka R, Fujii K. Can proximity of the occipital artery to the greater occipital nerve act as a cause of idiopathic greater occipital neuralgia? An anatomical and histological evaluation of the artery-nerve relationship. *Plast Reconstr Surg* 2007; 119:2029-2034; discussion 2035-2026.