

# A New Method For Hemorrhoid Surgery: Intrahemorrhoidal Diode Laser, Does It Work?

Hélio Plapler, M.D., Raduan Hage, Vet.M.D., Janaina Duarte, Vet.M.D., Nilza Lopes, M.Sc.,  
Igor Masson, M.Sc., Cláudio Cazarini, M.Sc., and Thiago Fukuda, M.Sc.

## Abstract

**Objective:** This study aimed to describe the clinical results of intrahemorrhoidal application of a diode laser. **Background Data:** Hemorrhoids are a common source of pain, and no surgical technique achieves a painless outcome. Endovascular laser therapy for varicose veins as described in an experimental study is a method that could be used in the treatment of hemorrhoids, but there are few clinical trials described in the literature. **Materials and Methods:** Fifteen patients with second and third degree hemorrhoids underwent intrahemorrhoidal laser therapy. After the piles were identified, a fiber was introduced into each and it was irradiated with laser energy (810 nm, 5 W, frequency of 5 Hz, energy density of 19 J/cm<sup>2</sup>, total energy of 4–10 J). **Results:** The piles were immediately partially reduced, and clinical examination 7, 14, 21, and 28 d after surgery showed complete healing in nine patients (60.4%) and partial resolution in five patients (33%). In one patient (6.6%) the treatment failed. Mean pain intensity throughout the study period, measured by a visual analog scale (0–10), was 0.84 ± 1.13 (mean ± SD). Major complications were burn lesions ( $n = 4$ ) and residual plicoma (skin tag) ( $n = 5$ ). Ten control patients underwent an open “cold scalpel” hemorrhoidectomy. Their pain intensity was 1.78 ± 0.68 (mean ± SD). There was a significant statistical difference ( $p = 0.018$ ) between groups. **Conclusion:** The diode laser energy delivered into small to median hemorrhoidal piles caused little pain and led to a partial to complete resolution within a short time compared to open hemorrhoidectomy. Some adjustments must be made to prevent burning lesions and residual plicoma. Although it is not a good method for big piles, this technique opens new possibilities for surgical treatment of hemorrhoidal disease.

## Introduction

HEMORRHOIDAL VEINS NORMALLY occur in the human body. When these veins become dilated they turn to a morbid condition called hemorrhoidal disease, which affects more than 80% of the world population at least once in a lifetime. Straining promotes the congestion of these veins and speeds the development of the hemorrhoids; heredity also plays an important role and it is common to observe many cases in a same family.<sup>1,2</sup> Pregnancy, weightlifting, and anything that increases intra-abdominal pressure contributes to vein dilation.

Since Milligan and Morgan’s surgical description of open hemorrhoidectomy, many methods have focused on curing hemorrhoids including rubber band ligation,<sup>3,4</sup> cryosurgery,<sup>3,5</sup> photocoagulation,<sup>1,6–9</sup> and stapling,<sup>10,11</sup> depending on the severity of the disease,<sup>12</sup> which is not easily defined.

The use of laser in proctology began in the 1960s, when the Nd:YAG laser was first used for anorectal surgery. After that, new lasers such as the CO<sub>2</sub> laser and new technologies such as the pulsed and the scanned laser resulted in improved outcomes.<sup>13,14</sup> Laser action on biological tissues is not yet a “closed” issue, however, and the use of laser energy on hemorrhoidal tissue remains controversial despite recent improvements in technology.<sup>15</sup>

Plapler et al.<sup>16</sup> studied 350 patients submitted to CO<sub>2</sub> laser open hemorrhoidectomy during the course of a year, in terms of pain and local healing. They concluded that laser has advantages compared to “conventional” surgery, specifically less postoperative pain and a more aesthetic scar.

Zahir et al.<sup>17</sup> published a retrospective study in 2000 comparing 50 patients, half of whom had laser therapy and half who had conventional hemorrhoidectomy. They concluded that laser leads to minor postoperative pain even though it is an open surgical techniques like the “traditional”

surgery, which requires the extraction of the hemorrhoidal tissue, leaving an exposed surface.

A new technique permits surgeons to treat varicose veins of the inferior limbs with a diode laser applied inside the vein.<sup>18</sup> This endovascular technique allows enlarged veins to be treated without requiring several skin cuts, and it can be performed as an ambulatory surgery.

Plapler et al.<sup>19</sup> studied the effect of the diode laser (810 nm wavelength) on interstitial tissue of the anal region of rats and showed that the diode laser leads to minimum alterations, as long as the laser–tissue interaction rules are obeyed. Additionally, Plapler<sup>20</sup> showed that diode laser can be used to treat hemorrhoidal disease in monkeys.

In a clinical trial, Karahaliloglu<sup>21</sup> described the submucosal application of the diode laser (980 nm) to treat first and second degree hemorrhoids in 105 patients and stated that the method is painless and results in total recovery.

We investigated if endovenous ablation of hemorrhoidal veins using an 810 nm diode laser improves the outcome of operated patients.

### Materials and Methods

This project was approved by the Ethics in Research Committee at UNIFESP/HSP, CEP protocol number 001/2007.

Fifteen patients, 25 to 45 years old, with second and third degree hemorrhoids were admitted at Hospital Municipal Vereador José Storopoli of Federal University of São Paulo (UNIFESP). Eight patients had three piles, six patients had two, and one patient showed a circular prolapse after sedation.

Patients received an intravenous injection of Propofol® 2.0 mg/kg (Biosintetica, São Paulo, Brazil) and local injection of 2% xylocaine. Medications were controlled by an anesthesiologist throughout the entire procedure.

Once the piles were identified, they were punctured and the laser energy (diode laser, Synus Laser Inc., São Paulo, Brazil) was delivered through an optic fiber of 600  $\mu\text{m}$  (Fig. 1), emitting a wavelength of 810 nm, with nominal power of 5 W, frequency of 5 Hz, and energy fluence of 19 J/cm<sup>2</sup>, pulling the fiber gradually until the pile shrunk. Total amount of energy was 4 to 10 Joules.

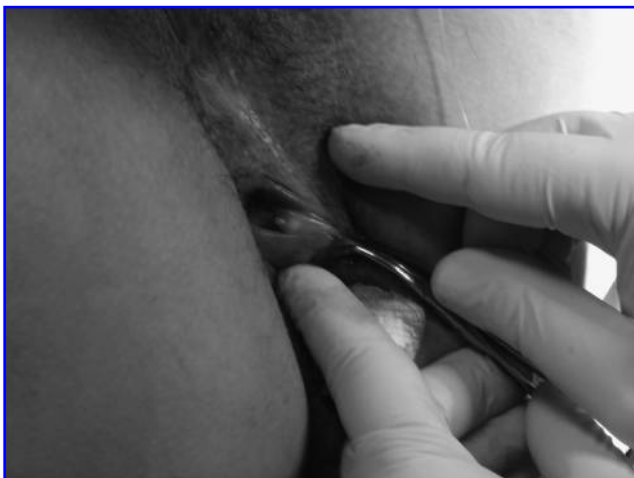

FIG. 1. Laser application inside the hemorrhoid.

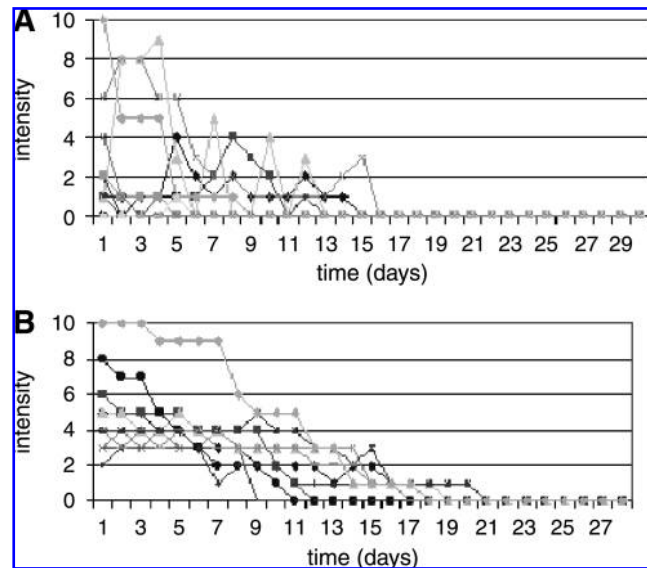


FIG. 2. Intensity of postoperative pain: (A) endolaser group; (B) conventional group.

Ten patients with hemorrhoids of the same degree received treatment by the conventional “cold scalpel” technique (Milligan–Morgan) and served as controls.

All procedures were performed by the same surgeon.

### Results

Patients were discharged 3 h after surgery and followed for 1 month. They were instructed to resume normal activities 1 d after surgery. They were also instructed to take only sodium diclofenac (Voltaren®, Novartis, São Paulo, Brazil) 100 mg twice a day if they felt unbearable pain. No dressing, no antibiotics, and no special diet were prescribed.

#### Follow-up

Patients returned every week. There were no complaints of diarrhea or straining.

#### Pain

Pain scale ranged from 0 (no pain) to 10 (maximum pain) on a visual analog scale (VAS). All patients were instructed

TABLE 1. DESCRIPTIVE STATISTICS FOR PAIN INTENSITY BETWEEN GROUPS DURING THE POSTOPERATIVE PERIOD

	Conventional	Endolaser
Mean pain intensity score <sup>a</sup>	1.78	0.84
IL (95% CI)	1.29	0.20
SL (95% CI)	2.27	1.48
Median	1.64	0.31
MSE	0.22	0.29
SD	0.69	1.06
Minimum	0.86	0.00
Maximum	3.46	3.19
<i>p</i> value <sup>b</sup>	0.018	

<sup>a</sup>Average score over 28 days.

<sup>b</sup>Mann–Whitney test.

IL, inferior limit; SL, superior limit; CI, confidence interval; SD, standard deviation.

TABLE 2. DESCRIPTIVE STATISTICS (MANN-WHITNEY TEST) FOR PAIN INTENSITY BETWEEN GROUPS FOR EACH INTERVAL TIME

	0-3 d		4-11 d		12-28 d	
	Conventional	Endolaser	Conventional	Endolaser	Conventional	Endolaser
Mean score for pain intensity	4.93	1.97	3.45	0.80	0.44	0.06
IL (95% CI)	3.35	0.35	2.41	0.17	0.21	-0.01
SL (95% CI)	6.52	3.60	4.50	1.44	0.68	0.14
Median	4.34	0.67	3.25	0.13	0.56	0.00
MSE	0.70	0.74	0.46	0.29	0.10	0.03
SD	2.22	2.68	1.46	1.05	0.33	0.12
Minimum	3.00	0.00	1.88	0.00	0.00	0.00
Maximum	10.00	7.33	7.13	2.75	0.94	0.39
<i>p</i> value <sup>a</sup>	0.01		<0.0001		0.012	

<sup>a</sup>Mann-Whitney test.

to check how much pain was felt every day on a standard table. For the laser group, the mean score was  $0.84 \pm 1.13$  SD for the entire 28 d period. Two patients experienced intense pain; one at the first postoperative day and one showed an atypical curve pattern (Fig. 2A). Drug intake varied from once or twice a day for the first 3 d. Pain intensity mean for the patients of the conventional surgery group was  $1.78 \pm 0.68$  SD (Fig. 2B) and drug intake varied from two to three tablets a day for at least 5 d. This difference was statistically significant by Mann-Whitney test (Table 1).

Comparing the pain score between three different times (0-3, 4-11, and 12-28 d), the endolaser group showed significantly lower values ( $p = 0.001$ ) compared to the conventional surgery group (Table 2). Both groups showed a reduction of the pain intensity score by the Friedman test (Fig. 3).<sup>22</sup>

**Scars**

Four patients in the laser group had postoperative scars which healed after 1 week (Fig. 4). Patients from the conventional surgery group had no scars (surgical bed was laid open).

**Plicoma (skin tag)**

Plicoma was the most common complication and occurred in five patients (Fig. 5) from the endolaser group. No patient from the conventional group experienced this complication.

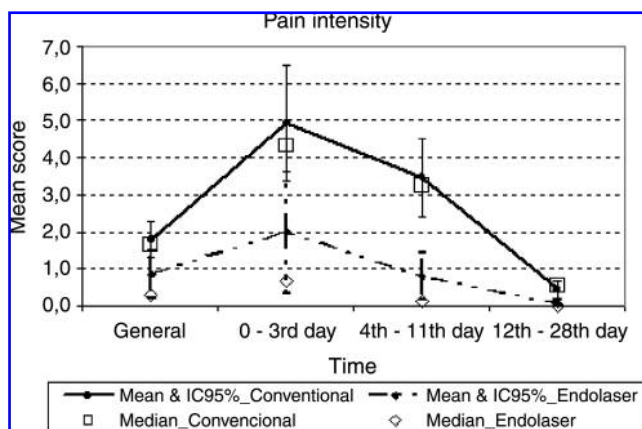


FIG. 3. Median, mean, and 95% confidence interval (95% CI) of the mean score for pain intensity for each time interval (0-3, 4-11, 12-28 d postoperative) and for each group.

**Discussion**

Since Milligan et al.<sup>23</sup> described their open surgical technique, surgeons have disagreed about the best method to treat hemorrhoids. Surgical techniques have included rubber band ligation, stapling, liquid nitrogen, infrared light, ultrasonic scalpel, conventional open or closed surgery, and laser therapy. All aim to decrease pain and to improve healing in the postoperative period.

Endovenous ablation of varicose veins<sup>24</sup> is a new concept in vascular surgery. This technique could be used in all veins and opens up new possibilities for treating lesions such as "port wine" hemangiomas and even hemorrhoids. Navarro et al.<sup>18</sup> and Min et al.<sup>25</sup> achieved 100% and 99% sealing of the *safena magna*, respectively, using this technique. Plapler,<sup>20</sup> in an experimental model, achieved 100% shrinkage of three hemorrhoidal piles in monkeys.

In the present study, the resolution index was 93.4%, although five patients remained with plicoma. No plicoma occurred in the control group, since in the open technique this would happen only weeks after healing. Plapler et al.<sup>12</sup> reported a 20% incidence of plicoma in 350 open hemorrhoidectomies using a CO<sub>2</sub> laser.

Scars occurred because of burn lesions in four patients. No other authors have reported this complication, but it is clear that experience leads to expertise. The more energy is

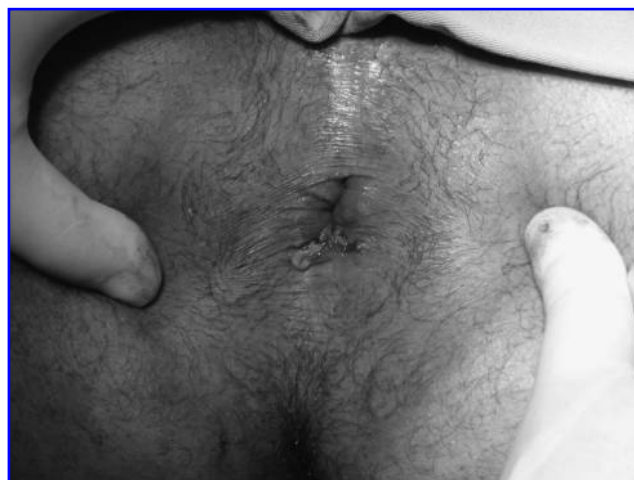

FIG. 4. Postoperative scar.

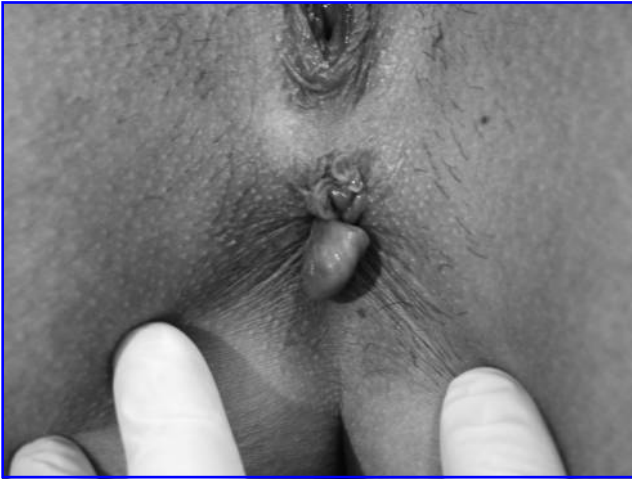

FIG. 5. Postoperative plicoma (skin tag).

applied for too long or too close to the mucosa, the greater the chance of causing damage. However, even these patients felt no unbearable pain during the entire study period.

Pain is the most important symptom after hemorrhoid surgery. All but two patients reported little or no pain, even those left with scars or plicoma. One patient reported intense pain on the first day and another presented an inconsistent pattern of pain. Compared to standard technique, pain was significantly less in the endolaser group, mainly at the first 3 postoperative days. Between the 4th and 11th day pain decreased for both groups, with the endolaser group consistently showing significantly lower scores. After the 12th day, the healing process tended to be equal.

Karahaliloglu<sup>21</sup> suggested submucosal rather than endovascular application of a laser to treat hemorrhoids. In fact, the tortuous dilated veins that form hemorrhoids do not allow laser energy to be delivered inside the vessels; rather, it is delivered into the interstitial tissue.<sup>19,26</sup> Tissue retraction around the vessel immediately after laser application leads to a proper resolution of hemorrhoids.

Nd:YAG laser (wavelength = 1064 nm) is more often used to treat veins, but no author has used it intravenously. This laser energy penetrates up to 4 mm in depth, which could lead to serious damages to the sphincter and to the surrounding structures. Diode laser (wavelength = 810 nm) penetrates up to 2 mm, is better absorbed by hemoglobin, and consequently causes less damage to the surrounding tissues. A new 1470 nm diode laser will be tested soon.

Surgical treatment of hemorrhoids remains an open field and more experimental and clinical studies are needed for better analysis. Endolaser techniques must be improved, and surgeons must become familiar with them. Although another group served as controls, the techniques were not really comparable since they dealt with different healing processes.

## Conclusion

Intrahemorrhoidal laser application enabled a decrease in patient's discomfort with apparently little postoperative pain. It is a good method for small and medium size hemorrhoidal piles, but is not the best choice for big piles.

## Acknowledgments

We are grateful to Prof. Dr. Rita de Cássia Rodrigues, Director of the Hospital Municipal Vereador José Storopoli of Federal University of São Paulo (UNIFESP) and her staff.

## Disclosure Statement

No competing financial interests exist.

## References

1. Abcarian, H., Alexander-Williams, J., Christiansen, J., et al. (1994). Benign anorectal disease: definition, characterization and analysis of treatment. *Am. J. Gastroenterol.* 89, S182–S193.
2. Keighley, M., and Williams, N., eds. (1993). *Surgery of the Anus, Rectum and Colon*, London: Saunders, WB, pp. 2576.
3. Rudd, W. (1989). Ligation and Cryosurgery of All Hemorrhoids. *An Office Procedure. Int. Surg.* 74, 148–151.
4. Tajana, A. (1989). Hemorrhoidectomy according to Milligan-Morgan: ligation and excision technique. *Int. Surg.* 74, 158–161.
5. Tanaka, S. (1989). Cryosurgical treatment of hemorrhoids in Japan. *Int. Surg.* 74, 146–147.
6. Neiger, A. (1989). Infrared-photo-coagulation for hemorrhoids treatment. *Int. Surg.* 74, 142–143.
7. Reis Neto, J., Quilici, F., Cordeiro, F. and Reis, J., Jr. (1992). Ambulatory treatment of hemorrhoids—a prospective random trial. *Colo-Proctology* 14, 342.
8. Newstead, C. (2000). Ambulatory treatment of benign anal diseases, in: *New Trends in Coloproctology*. J. Reis Neto (ed.). São Paulo: Revinter, pp. 97.
9. Sankar, M.Y., and Joffe, S.N. (1988). Laser surgery in colonic and anorectal lesions. *Surg. Clin. North Am.* 68, 1447–1469.
10. Ganio, E., Lus, A., Trompetto, M., and Clerico, C. (2000). Stapled haemorrhoidectomy, in: *New Trends in Coloproctology*. São Paulo: Revinter, pp. 207.
11. Longo, A. (1998). Treatment of haemorrhoids disease by reduction of mucosa and hemorrhoidal prolapse with circular suturing device; a new procedure. *6th World Congress of Endoscopy Surgery, Rome*, pp. 777.
12. Ferguson E., Jr. (1988). Alternatives in the treatment of hemorrhoidal disease. *South. Med. J.* 81, 606–610.
13. Chia, Y.W., Darzi, A., Speakman, C.T., Hill, A.D., Jameson, J.S. and Henry, M.M. (1995). CO<sub>2</sub> haemorrhoidectomy—does it alter anorectal function or decrease pain compared to conventional haemorrhoidectomy? *Int. J. Colorectal Surg.* 10, 22–24.
14. Senagore, A., Mazier, W., Luchtefeld, M., MacKeigan, J., and I, W. (1993). Treatment of advanced hemorrhoidal disease: a prospective, randomized comparison of cold scalpel vs. contact Nd:YAG laser. *Dis. Colon Rectum* 36, 1042–1049.
15. Fleshman, J. (2002). Advanced technology in the management of hemorrhoids: stapling, laser, harmonic scalpel, and ligasure. *J. Gastrointest. Surg.* 6, 299–301.
16. Plapler, H., Faria Netto, A.J., and Pedro, M.d.S. (2000). 350 ambulatory hemorrhoidectomies using a scanner coupled to a CO<sub>2</sub> laser. *J. Clin. Laser Med. Surg.* 18, 259–262.
17. Zahir, K., Edwards, R., Vecchia, A., Dudrick, S. and Tripodi, O. (2000). Use of the Nd:YAG laser improves quality of life and economic factors in the treatment of hemorrhoids. *Conn. Med.* 64, 199–203.
18. Navarro, L., Min, R.J., and Boné, C. (2001). Endovenous laser: a new minimally invasive method of treatment for

- varicose veins—preliminary observations using an 810 nm diode laser. *Dermatol. Surg.* 27, 117–122.
19. Plapler, H., Fino, T.P.M., Artigiani Neto, R., and Ramalho, C.E.B. (2002). Diode laser in the interstitial tissue of the anal region: an experimental study in rats. XIV Panamerican Congress of Anathomy, Rio de Janeiro.
  20. Plapler, H. (2008). A new method for hemorrhoid surgery: experimental model of diode laser application in monkeys. *Photomed. Laser Surg.* 26, 143–146.
  21. Karahaliloglu, A.F. (2007). First results after laser obliteration of first- and second-degree hemorrhoids. *Coloproctology* 29, 327–336.
  22. Siegel, S., and Castellan, N., eds. (1988). *Nonparametric Statistics*. New York: McGraw-Hill, pp. 448.
  23. Milligan, E.T.C., Morgan, C.N., and Jones, L.E. (1937). Surgical anatomy of the anal canal and the operative treatment of hemorrhoids. *Lancet* 2, 1119–1125.
  24. Sadick, N. (2004). Laser treatment of leg veins. *Skin Ther. Lett.* 9, 6–9.
  25. Min, R.J., Zimmet, S.E., Isaacs, M.N., and Forrestal, M.D. (2001). Endovenous laser treatment of the incompetent greater saphenous vein. *J. Vasc. Interv. Radiol.* 12, 1167–1171.
  26. Plapler, H. (2004). Ablação de tumor de canal anal tratado com laser de diodo: seguimento após 17 meses. *Revista do Colégio Brasileiro de Cirurgiões* 31, 271–273.

Address correspondence to:

*Hélio Plapler, M.D.*

*Rua Tomas Carvalhal 884 ap 51*

*CEP: 04006-003 São Paulo*

*Brazil*

*E-mail: helio@plapler.com.br*

