



## Does rituximab increase the incidence of infectious complications? A narrative review<sup>☆</sup>

Theodoros Kelesidis<sup>a,\*</sup>, George Daikos<sup>b</sup>, Dimitrios Boumpas<sup>c</sup>, Sotirios Tsiodras<sup>d</sup>

<sup>a</sup> Department of Medicine, Division of Infectious Diseases, David Geffen School of Medicine at UCLA, 10833 Le Conte Ave., CHS 37-121, Los Angeles, CA 90095, USA

<sup>b</sup> First Department of Propedeutic Medicine, Laikon University Hospital, University of Athens Medical School, Athens, Greece

<sup>c</sup> Department of Internal Medicine, University Hospital, Medical School, University of Crete, Heraklion, Greece

<sup>d</sup> Fourth Department of Internal Medicine, Attikon University Hospital, University of Athens Medical School, Athens, Greece

### ARTICLE INFO

#### Article history:

Received 18 November 2009

Received in revised form 23 March 2010

Accepted 30 March 2010

#### Keywords:

Rituximab

Infection

Immunocompromised

### ABSTRACT

**Background:** Rituximab has increasingly been used for the treatment of hematological malignancies and autoimmune diseases, and its efficacy and safety are well established. Although clinical trials have shown conflicting results regarding the association of rituximab with infections, an increased incidence of infections has recently been reported in patients with lymphomas being treated with rituximab. However, clinical experience regarding the association of rituximab with different types of infection is lacking and this association has not been established in patients with rheumatoid arthritis.

**Methods:** All previous studies included in our literature review were found using a PubMed, EMBASE, and Cochrane database search of the English-language medical literature applying the terms 'rituximab', 'monoclonal antibodies', 'infections', 'infectious complications', and combinations of these terms. In addition, the references cited in these articles were examined to identify additional reports.

**Results:** We performed separate analyses of data regarding the association of rituximab with infection in (1) patients with hematological malignancies, (2) patients with autoimmune disorders, and (3) transplant patients. Recent data show that rituximab maintenance therapy significantly increases the risk of both infection and neutropenia in patients with lymphoma or other hematological malignancies. On the other hand, data available to date do not indicate an increased risk of infections when using rituximab compared with concurrent control treatments in patients with rheumatoid arthritis. However, there is a lack of sufficient long-term data to allow such a statement to be definitively made, and caution regarding infections should continue to be exercised, especially in patients who have received repeated courses of rituximab, are receiving other immunosuppressants concurrently, and in those whose immunoglobulin levels have fallen below the normal range. Few data are available concerning the risk of organ transplant recipients developing infections following rituximab therapy. Data from case reports, case series, and retrospective studies correlate rituximab use with the development of a variety of infections in transplant patients.

**Conclusions:** Further studies are needed to clarify the association of rituximab with infection. Physicians and patients should be educated about the association of rituximab with infectious complications. Monitoring of absolute neutrophil count and immunoglobulin levels and the identification of high-risk groups for the development of infectious complications, with timely vaccination of these groups, are clearly needed.

© 2010 International Society for Infectious Diseases. Published by Elsevier Ltd. All rights reserved.

<sup>☆</sup> **Corresponding Editor:** William Cameron, Ottawa, Canada.

**Abbreviations:** CHOP, cyclophosphamide doxorubicin vincristine and prednisone; CLL, chronic lymphocytic leukemia; CVP, cyclophosphamide, vincristine, and prednisone; CI, confidence intervals; CMV, cytomegalovirus; CNS, central nervous system; DLBCL, diffuse large B-cell lymphoma; dcSSc, diffuse cutaneous systemic sclerosis; DMARD, Disease Modifying Antirheumatic Drug; EBV, Epstein Barr Virus; FDA, Food and Drug Administration; FCM, fludarabine, cyclophosphamide, and mitoxantrone; G-CSF, Granulocyte Colony Stimulating Factor; HIV, Human Immunodeficiency Virus; HBV, Hepatitis B virus; HCV, Hepatitis C virus; HEV, Hepatitis E virus; HbsAg, Hepatitis B surface antigen; HDMP, High dose methylprednisolone; HIV, human immunodeficiency virus; HSV, Herpes Simplex Virus; HSCT, hematological stem cell transplantation; MTX, methotrexate; MCP, mitoxantrone, chlorambucil, and prednisolone; ND, Not determined; NHL, non-Hodgkin lymphoma; NR, not reported; OI, Opportunistic infections; PCP, Pneumocystis Carinii Pneumonia; PML, progressive multifocal leucoencephalopathy (PML); R, rituximab; RA, rheumatoid arthritis; RCT, randomized controlled trial; RR, relative risk; RSV, respiratory syncytial virus; SL, small lymphocytic lymphoma; SIE, serious infection events; SLE, systemic lupus erythematosus; TNF, tumor necrosis factor); VZV, Varicella Zoster Virus.

\* Corresponding author. Tel.: +1 310 825 7225; fax: +1 310 2080140.

E-mail address: [tkelesidis@mednet.ucla.edu](mailto:tkelesidis@mednet.ucla.edu) (T. Kelesidis).

## KEY POINTS

- Clinical trials have shown conflicting results regarding the association of rituximab with infections. However, clinical experience regarding the association of rituximab with different types of infection is lacking.
- An increased incidence of infections in patients with lymphomas and rheumatoid arthritis being treated with rituximab has been recently reported.
- Education of physicians and patients about the association of rituximab with infectious complications, monitoring of absolute neutrophil count and immunoglobulin levels, identification of high risk groups for development of infectious complications and timely vaccination of these groups are needed

## 1. Introduction

Rituximab (Rituxan®) is a chimeric human–mouse monoclonal antibody that has been used extensively in the treatment of hematological malignancies and autoimmune diseases and is US Food and Drug Administration (FDA) approved for CD20-positive B-cell non-Hodgkin's lymphoma (NHL) and for moderate-to-severe rheumatoid arthritis (RA) not responding to other treatments.<sup>1–3</sup> More specifically, rituximab is a human–mouse chimeric monoclonal antibody (IgG1) that reacts specifically with the CD20 antigen expressed on more than 95% of normal and malignant B-cells, inducing complement-mediated and antibody-dependent cellular cytotoxicity (Fig. 1).<sup>4</sup>

Treatment with rituximab causes a rapid depletion of pre-B- and mature B-cells, which remain at low or undetectable levels for 2–6 months before returning to pretreatment levels, generally within 12 months. There is growing evidence, including an increased incidence of certain viral infections with the use of rituximab,<sup>5</sup> supporting the notion that rituximab, in addition to its

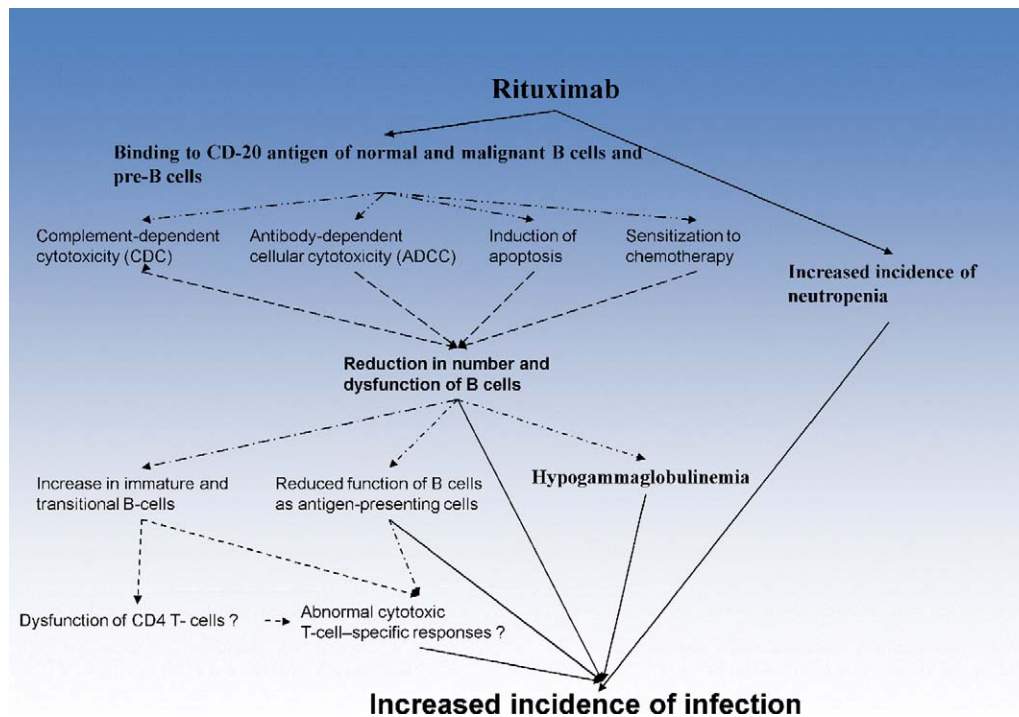
effect on B cells, also influences T-cell immunity and predisposes to opportunistic infections.<sup>6–9</sup> Rituximab may cause immunosuppression through several other mechanisms such as delayed-onset cytopenia, particularly neutropenia<sup>10</sup> and hypogammaglobulinemia, especially when administered for long periods, e.g., in maintenance therapy.<sup>11–13</sup>

Clinical trials have shown conflicting results regarding the association of rituximab with infections.<sup>5,14–22</sup> An increased incidence of infections in patients with lymphomas and RA being treated with rituximab has recently been reported.<sup>23–26</sup> Pooled data from 356 patients who received rituximab monotherapy showed that the incidence rate of infectious events was 30%; 19% of patients had bacterial infections, 10% viral infections, 1% fungal infections, and 6% infections of unknown etiology. Severe infections, including sepsis, occurred in only 1% of patients during the treatment period, and in 2% during the follow-up period.<sup>15</sup> In a recent review<sup>27</sup> involving 389 patients from 25 studies, the incidence of serious infections varied from 2.8% to 45% (mean 12.5%).

Infection in patients treated with rituximab is a multifactorial process and its incidence becomes difficult to analyze. The age of the patient, the presence of other medical problems, and concomitant drug therapies can influence susceptibility to infection. Thus, and for purposes of clarity, in this report we present separate data regarding the association of rituximab with infection in (1) patients with hematological malignancies, (2) patients with autoimmune disorders, and (3) transplant patients.

## 2. Methods

All previous studies included in our literature review were found using a search of PubMed, EMBASE, and the Cochrane database (through August 2009) of the English-language medical literature applying the terms 'rituximab', 'monoclonal antibodies', 'infections', 'infectious complications', and combinations of these terms. In addition, the references cited in these articles were examined to



**Fig. 1.** Mechanism of action of rituximab. Rituximab reacts specifically with the CD20 antigen expressed on more than 95% of normal and malignant B-cells, inducing complement-mediated and antibody-dependent cellular cytotoxicity. There is growing evidence supporting the notion that rituximab, in addition to its effect on B cells, also influences T-cell immunity and this may predispose to opportunistic infections. Rituximab may in addition cause immunosuppression through several other mechanisms such as delayed-onset cytopenia, particularly neutropenia and hypogammaglobulinemia.

identify additional reports. Regarding the association of rituximab with infection, we reviewed evidence from meta-analyses, randomized controlled trials, and retrospective studies. We performed separate analyses of the data regarding the association of rituximab with infection in (1) patients with hematological malignancies, (2) patients with autoimmune disorders, and (3) transplant patients. However, due to the paucity of data regarding the different types of infections associated with the use of rituximab (bacterial, viral, fungal, parasitic), we also reviewed the evidence from case-control studies, case series, and case reports.

### 3. Rituximab and infection in hematological malignancies

Table 1 outlines the most important studies evaluating infection in rituximab-treated patients with hematological malignancies.<sup>19,23,28–45</sup>

In a recent systematic review in patients with lymphoma, Aksoy et al. found significantly increased rates of infections and neutropenia in patients who had received rituximab maintenance therapy compared with those who had not (8.1% vs. 3.9% and 13.4% vs. 6.3%, respectively).<sup>23</sup> In a similar meta-analysis of randomized controlled trials (RCT), patients with follicular lymphoma who underwent rituximab maintenance therapy had more infection-related adverse events than patients in the observation arm (relative risk (RR) 1.99, 95% confidence interval (CI) 1.21–3.27).<sup>28</sup> This effect was more pronounced when only grade 3 or 4 infection-related adverse events were included in the analysis (RR 2.90, 95% CI 1.24–6.76).<sup>28</sup>

Regarding other hematological neoplasias, seven clinical trials tested rituximab added to the combination of cyclophosphamide, doxorubicin, vincristine, and prednisone (CHOP) versus CHOP chemotherapy alone.<sup>26</sup> In six studies comparing rituximab with CHOP (R-CHOP) versus CHOP alone (excluding HIV-1-positive patients), the rate of infection was higher in one study,<sup>35</sup> comparable in three studies,<sup>31,32,36</sup> and smaller in one study,<sup>34</sup> a 1% increase in infection-associated mortality was found in one study.<sup>33</sup>

In HIV patients with lymphoma treated with R-CHOP versus CHOP, a significant 12% increase in the occurrence of opportunistic infections and infection-related deaths was observed.<sup>30</sup> Therefore, it appears that HIV seropositivity influences the incidence of infectious complications in such patients.

Concerning the combination of rituximab with non-CHOP-containing regimens, no significant difference in infection rates compared to the standard regimen was found in three RCTs.<sup>37–39</sup> Nevertheless, such effects depend on the co-administered agent. For example a combined regimen with fludarabine (associated with profound T-cell depletion) may substantially increase the risk of opportunistic infections both in the induction and the maintenance phase.<sup>37,41,46,47</sup>

The duration of rituximab therapy may also be important. In one retrospective study of hematology patients receiving rituximab, duration of rituximab therapy, reduction in IgM after administration of rituximab, and granulocyte colony-stimulating factor (G-CSF) administration were risk factors associated with infection.<sup>48</sup>

Thus, rituximab significantly increases the risk of both infection and neutropenia in patients with lymphoma or other hematological malignancies, and this risk appears also to depend on the co-administered agent.

### 4. Rituximab and infection in autoimmune disorders

Table 2 outlines the most important studies evaluating infection in rituximab-treated patients with autoimmune disorders.<sup>24,25,49–55</sup>

Rituximab is effective in patients with RA with an inadequate response to methotrexate, for whom conventional disease-modifying antirheumatic drugs (DMARDs) have failed or who have received one or more tumor necrosis factor (TNF) inhibitors.

The three pre-approval phase II and phase III RCTs conducted with rituximab in patients with RA reported low rates of infection, serious or not.<sup>53</sup> The rate of infection was higher with rituximab use in one RCT,<sup>52</sup> and slightly higher in placebo-treated patients in another study.<sup>50</sup> The incidence of serious infections was reported in one phase IIA RCT only: during a 48-week follow-up, six serious infections were reported in patients treated with rituximab regimens versus only one serious infection in a patient being treated with methotrexate alone; this difference was not statistically significant.<sup>56</sup>

Further information on the risk of infections associated with rituximab therapy has emerged from open-label extensions to the RCTs. No significant difference in the rates of infection with the use of rituximab and no cases of tuberculosis (TB), opportunistic infections, or viral reactivations have been reported in the open-label RA extension studies to date (Table 2).

A recent study suggested that there were no fatal or opportunistic infections prior to or after another biological DMARD (in patients with RA refractory to treatment) following rituximab treatment.<sup>50</sup> In a separate meta-analysis of the three rituximab clinical trials, the pooled odds ratios (OR) for serious infections at all doses of rituximab versus placebo did not reveal any statistically significant increased risk (OR 1.45, 95% CI 0.56–3.73).<sup>54</sup>

Based on the results presented, treatment with rituximab for up to 3 years appears to be associated with a numerically increased incidence of infections (including serious infections). However no statistical difference regarding an increased risk for infection is evident and the risk appears lower than that associated with the TNF inhibitors. Long-term controlled data are necessary to allow a more precise definition of this risk. Thus, further studies are needed to elucidate the association of rituximab with infection in patients with RA, since current data do not indicate an increased risk of infections when using rituximab compared with concurrent control treatments.

### 5. Rituximab and infection in transplant patients

Rituximab off-label use includes organ transplantation. The use of rituximab has been increasing in the transplant population and an increasing number of infections have been reported. Few data are available concerning the risk of organ transplant recipients developing infections following rituximab therapy. Scemla et al. reported bacterial, viral, and fungal infection rates at 55.3%, 47.4%, and 13.2%, respectively, in kidney transplant patients who received rituximab therapy.<sup>57</sup> In kidney transplant patients who received rituximab therapy at two different doses (375 mg/m<sup>2</sup>/week four times or 1000 mg/m<sup>2</sup>/week two times), Tsapepas et al. reported a bacterial infection rate at 48% and 61.1%, respectively, a viral infection rate at 8.2% and 25.3%, respectively, and a fungal infection rate at 20% and 8.2%, respectively.<sup>58</sup> A recent retrospective study by Grim et al. observed no increased risk of infectious complications following rituximab therapy in renal transplant recipients.<sup>59</sup>

Low-dose rituximab induction therapy in renal transplant recipients appears to have no influence on the incidence of cytomegalovirus (CMV) infection and CMV seroconversion.<sup>60</sup> However, because of the high incidence of CMV infection, especially for CMV-seronegative recipients who received rituximab, anti-CMV prophylaxis therapy needs to be considered.<sup>60</sup>

In one study of 77 kidney transplant patients who received rituximab therapy, the incidence of bacterial infection was similar between these patients and another kidney transplant control

**Table 1**  
Studies regarding infectious complications in patients with lymphoma treated with rituximab

Type of study	Author, year [Ref.]	Patient characteristics	Chemotherapy	Comments	Outcome
Meta-analysis	Aksoy, 2009 [23]	Lymphoma	Rituximab maintenance therapy	Significantly increased rates of infections and neutropenia. Infection rates were 8.1% in patients who had received rituximab maintenance therapy vs. 3.9% in those who had not. Neutropenia rates were 13.4% vs. 6.3%, respectively ( $p < 0.001$ )	Meta-analysis of the RCTs demonstrated that rituximab maintenance therapy significantly increased the RR of both infection and neutropenia in patients with lymphoma
Meta-analysis of RCTs	Vidal, 2009 [28]	Follicular lymphoma	Rituximab	Patients undergoing rituximab maintenance therapy had more infection-related adverse events than patients in the observation arm (RR 1.99, 95% CI 1.21–3.27). When only grade 3 or 4 infection-related adverse events were included in the analysis, this effect was even more pronounced (RR 2.90, 95% CI 1.24–6.76)	
RCT phase II	Eve, 2009 [29]	Previously untreated mantle cell lymphoma	Fludarabine and cyclophosphamide with or without rituximab	Non-hematological toxicity was similar between the two treatment arms	
RCT	Kaplan, 2005 [30]	NHL (HIV patients)	R-CHOP vs. CHOP	99 patients treated with R-CHOP vs. 51 patients treated with CHOP (infection rate NR). Presence of opportunistic infections in the R-CHOP group and absence of these infections in the CHOP group	Infection-related death was 14% with R-CHOP vs. 2% with CHOP ( $p = 0.035$ )
RCT	Lenz, 2005 [31]	NHL Mantle cell	R-CHOP vs. CHOP	33% (grade I–II) and 5% (grade III/IV) of 62 patients treated with R-CHOP developed infections vs. 29% (grade I–II) and 6% (grade III/IV) of 60 patients treated with CHOP	NR
RCT	Hiddemann, 2005 [32]	NHL follicular	R-CHOP vs. CHOP	5% of 223 patients treated with R-CHOP developed infections vs. 7% of 205 patients treated with CHOP	Infection-related death 1.9% with R-CHOP vs. 0.5% with CHOP
RCT	Feugier, 2005 [33], Coiffier, 2002 [34]	DLBCL	R-CHOP vs. CHOP	65% (any grade) and 12% (grade III/IV) of 202 patients treated with R-CHOP developed infections vs. 65% (any grade) and 20% (grade III/IV) of 197 patients treated with CHOP	Infection-related death 1.7% with R-CHOP vs. 1.9% with CHOP
RCT	Habermann, 2006 [35]	DLBCL	R-CHOP vs. CHOP	17% of 318 patients treated with R-CHOP developed infections vs. 16% of 314 patients treated with CHOP	
RCT	Pfreundschuh, 2006 [36]	NHL B-cell	R-CHOP vs. CHOP	7% of 411 patients treated with R-CHOP developed infections vs. 8% of 413 patients treated with CHOP	
RCT	Forstpointner, 2004 [37]	NHL follicular and mantle cell	Rituximab + FCM vs. FCM	1.5% (grade III/IV) of 62 patients treated with R-FCM developed infections vs. 1.5% (grade III/IV) of 66 patients treated with FCM	
RCT	Marcus, 2005 [38]	NHL follicular	Rituximab + CVP vs. CVP	No difference between the two groups (162 patients in R-CVP vs. 159 in CVP)	
RCT	Herold, 2003 [39]	Indolent NHL	Rituximab + MCP vs. MCP	No difference in infection rates between the two groups (55 patients in R-MCP vs. 51 in MCP)	

Table 1 (Continued)

Type of study	Author, year [Ref.]	Patient characteristics	Chemotherapy	Comments	Outcome
Controlled clinical trial	Dungarwalla, 2008 [40]	14 heavily pre-treated CLL patients	HDMP ± rituximab	2 cases of systemic candidiasis, 2 cases of aspergillosis, 1 case of VZV, 1 case of adenovirus, bacteremia. Although HDMP-R causes little or no myelosuppression, the addition of rituximab might have predisposed to opportunistic infections. However, heavily pre-treated CLL patients have an increased susceptibility to infection intrinsic to the disease. Small series of patients/caution about conclusions	All patients died (except for the case with VZV)
RCT phase II	Del Poeta, 2008 [41]	B-CLL	Fludarabine and rituximab	3 dermatomal herpes zoster infections and 4 localized herpes simplex infections	
Retrospective study	Ennishi, 2008 [42]	64 yo M with follicular lymphoma stage IVa (partial response to treatment); 61 yo M with diffuse large B-cell lymphoma stage 1a (complete response to treatment)	R-CHOP	13 of 90 (14%) patients developed interstitial pneumonitis during R-CHOP therapy, compared with none of 105 patients treated with CHOP alone; 2 of these cases were PCP	All patients responded well to treatment, and recovered within 2–3 weeks
Retrospective study	Lee, 2008 [19]	46 patients with relapsed indolent or high-risk aggressive B cell NHL who received rituximab (17 patients) or not (29 patients) before autologous HSCT	Rituximab	Post-transplant infectious complications up to 6 months after transplantation. Seventeen of 46 patients received rituximab before HSCT. Three of them suffered from CMV infection and two of them developed CMV disease. All of the patients with CMV disease recovered after ganciclovir and CMV-specific immunoglobulin therapy. Twenty-nine of 46 patients without rituximab treatment before HSCT did not develop CMV after HSCT. Risk of CMV infection after autologous HSCT higher in rituximab-treated patients (17.6% vs. 0%, $p = 0.045$ ). Risk of CMV disease had higher trend with rituximab therapy than without rituximab therapy (11.7% vs. 0%, $p = 0.131$ )	All 3 cases responded to ganciclovir combined with CMV-specific immunoglobulin
RCT phase III	Van Oers, 2006 [43]	Relapsed/resistant follicular lymphoma	R-CHOP	Upper respiratory tract infections mostly	
RCT phase III	Ghielmini, 2005 [44]	Mantle cell lymphoma	R-CHOP	One patient experienced three episodes of pneumonia, 1 case of hepatitis, 1 case of septic shock	
RCT phase II	Hainsworth, 2003 [45]	CLL/SL		<i>Staphylococcus aureus</i> pneumonia, 1 patient; localized herpes zoster, 1 patient; and gastroenteritis, probably viral, 1 patient	

CHOP, cyclophosphamide, doxorubicin, vincristine, and prednisone; CLL, chronic lymphocytic leukemia; CVP, cyclophosphamide, vincristine, and prednisone; CMV, cytomegalovirus; DLBCL, diffuse large B-cell lymphoma; FCM, fludarabine, cyclophosphamide, and mitoxantrone; HDMP, high-dose methylprednisolone; HIV, human immunodeficiency virus; HSCT, hematological stem cell transplantation; M, male; MCP, mitoxantrone, chlorambucil, and prednisolone; NHL, non-Hodgkin lymphoma; NR, not reported; PCP, *Pneumocystis jirovecii* (*carinii*) pneumonia; R, rituximab; RCT, randomized controlled trial; RR, relative risk; SL, small lymphocytic lymphoma; VZV, varicella zoster virus; yo, year-old.

**Table 2**

Clinical trials and open label studies that report incidence of infections with use of rituximab in patients with rheumatoid arthritis

Type of study	Author, year [Ref.]	Patient characteristics	Immunosuppression	F/u of study duration	Comments	Outcome
Clinical trial	Lafyatis, 2009 [49]	Diffuse cutaneous systemic sclerosis	Rituximab	6 months	No significant infections were noted in this pilot study	Treatment with rituximab appeared to be safe and well tolerated among patients with dcSSc
Clinical trial	Genovese, 2009 [50]	Patients with advanced RA many of whom had previously been treated with multiple RA therapies, including biologicals prior to receiving rituximab, and then withdrew from clinical trials and subsequently received further biological therapy	Biological DMARD after rituximab treatment		In 185 patients who received rituximab plus another biological DMARD 13 SIEs (6.99 events/100 patient-years) occurred following rituximab, but prior to another biological DMARD. 10 SIEs (5.49 events/100 patient-years) occurred following another biological DMARD. SIEs were of typical type and severity for RA patients. No fatal or opportunistic infections	The size of the sample and limited follow-up restricts definitive conclusions about safety in B-cell depleted patients receiving additional biological DMARDs
DANCER RCT (phase IIB)	Emery, 2006 [51]	Patients with RA	MTX +/- rituximab	24 weeks	42/149 (28%) of patients who were treated with MTX developed infections and 2/149 (1%) developed serious infections. 50/142 (35%) of patients who were treated with MTX + rituximab (500 mg) developed infections and 0/142 (0%) developed serious infections. 67/192 (35%) of patients who were treated with MTX + rituximab (1000 mg) developed infections and 4/192 (2%) developed serious infections. Type and severity of infections were similar across all three treatment arms. The most common infections were respiratory tract infections, urinary tract infections, and nasopharyngitis. The overall rate of serious infections (events/100 patient-years) was 3.19 for MTX alone and 4.74 for rituximab 1000 mg	Of the 6 serious infections, 2 occurred in the MTX monotherapy group (1 each of pneumonia and respiratory tract infection) and 4 occurred in the rituximab 1000 mg group (2 cases of pyelonephritis and 1 case each of bronchitis and epiglottitis); all serious infections were reported to have resolved without sequelae
Phase IIA	Edwards, 2004 [52]	Patients with RA	MTX +/- rituximab, cyclophosphamide + rituximab	24 weeks	1/40 (3%) of patients who were treated with MTX developed serious infections. 2/40 (5%) of patients who were treated with rituximab (1000 mg) developed serious infections. 2/41 (5%) of patients who were treated with cyclophosphamide + rituximab (1000 mg) developed serious infections. 0/40 (0%) of patients who were treated with MTX + rituximab (1000 mg) developed serious infections. In total 4 patients who had received rituximab developed serious infections (2 had septic arthritis, 1 of whom also had <i>Staphylococcus aureus</i> -related septicemia; 1 had 2 episodes of <i>Pseudomonas aeruginosa</i> pneumonia; and 1 had bronchopneumonia)	One patient in the rituximab group with serious infection (bronchopneumonia) subsequently died, although death may have been related to concomitant ischemic/vascular heart disease

Table 2 (Continued)

Type of study	Author, year [Ref.]	Patient characteristics	Immunosuppression	F/u of study duration	Comments	Outcome
Phase IIA extension	Edwards, 2004 [52]	Patients with RA	MTX +/- rituximab, cyclophosphamide + rituximab	24 weeks	0/37 (0%) of patients who were treated with MTX developed serious infections. 1/38 (3%) of patients who were treated with rituximab (1000 mg) developed serious infections (1 case of gastroenteritis). 0/37 (0%) of patients who were treated with cyclophosphamide + rituximab (1000 mg) developed serious infections. 1/39 (3%) of patients who were treated with MTX + rituximab (1000 mg) developed serious infections (1 case of pyelonephritis)	NR
REFLEX RCT (phase III)	Cohen, 2006 [53]	Patients with RA	MTX +/- rituximab	24 weeks	79/209 (38%) of patients who were treated with MTX developed infections and 1/209 (3%) developed serious infections. 126/308 (41%) of patients who were treated with MTX + rituximab (1000 mg) developed infections and 7/308 (2%) developed serious infections. The overall infection rate (events/100 patient-years) was slightly higher in placebo-treated patients (154.6) than in rituximab-treated patients (138.2). The most common infections observed in both groups were upper respiratory tract infections, nasopharyngitis, urinary tract infections, bronchitis, and sinusitis. Rates of serious infections were 3.7/100 patient-years for placebo and 5.2/100 patient-years for rituximab; no statistical comparison of this difference was reported	Of 7 serious infections that occurred in the rituximab-treated patients, 6 (1 case each of gastroenteritis, pyelonephritis, cat-bite infection, influenza, fever of unknown etiology, and de novo hepatitis B (HBV)) resolved without sequelae, while the other infection (gangrenous cellulitis) resulted in amputation of a toe
Open label trial	Keystone, 2007 [54]	Ongoing follow-up study of all patients enrolled in the three original clinical trials (2 phase II and 1 phase III) who had an incomplete response to or were intolerant of TNF inhibitors	Rituximab vs. control group		No evidence to date for any increase in the incidence of infections and serious infections, with all patients having received at least 2 courses of rituximab. <sup>25</sup> Rates of infection (events/100 patient-years) were 83, 83, 80, and 88 for patients who had received 1, 2, 3, or 4 courses of rituximab, respectively; the corresponding rates for serious infections were 4.1, 4.6, 5.6, and 8.0 events/100 patient-years. Rates of infections and serious infections appear relatively stable with increasing courses of rituximab, however the extent of observation for patients receiving multiple courses of treatment is inevitably less than that for single-course treatment. Longer follow-up data is necessary. Irrespective of the number of courses of rituximab, serious infections occurred most often during the first 3 months after administration and declined thereafter. Overall, 68 of 1039 patients (7%) in the all-exposure population experienced a total of 78 serious infections following treatment with rituximab. The most common infections reported were upper respiratory tract infection, nasopharyngitis, urinary tract infection, bronchitis, and sinusitis. No incidences of opportunistic infections or tuberculosis were observed. The serious infection rate after course 1 (5.1 per 100 patient-years) remained stable through additional courses. The proportion of patients with circulating IgM and IgG levels below the LLN increased with subsequent courses; however, serious infection rates in these patients (5.6 per 100 patient-years in patients with low IgM levels and 4.8 per 100 patient-years in patients with low IgG levels) were comparable with those in patients with immunoglobulin levels above the LLN (4.7 per 100 patient-years)	Three serious infections were fatal. Two occurred between course 1 and course 2; 1 patient had bronchopneumonia and a second patient had neutropenic sepsis following concomitant treatment with trimethoprim. The third infection-related fatality occurred after course 2, from septic shock in a 54-year-old female diabetic patient with a history of sepsis and recurrent urinary tract infections



Open label trial	Furst, 2007 [24]	Follow-up open label study on patients with RA	Rituximab vs. control group	From a total of 1053 patients who had been exposed to at least 1 course of rituximab (total drug exposure of 2438 patient-years), 702 patients reported at least 1 infection, the most common being upper respiratory infections (32%) and urinary tract infections (11%). Rates of serious infections for patients who had received 1, 2, 3, or 4 courses of rituximab were 5.4, 4.6, 6.3, and 5.4 events/100 patient-years, respectively No significant differences in the rate of infections between the 4 treatment arms (MTX, rituximab, rituximab + cyclophosphamide, and rituximab + MTX)
Open label trial	Furst, 2008 [25]	A 2-year follow-up of patients who participated in the phase IIA trial	Rituximab, MTX, MTX + rituximab, cyclophosphamide + rituximab	Based on a total of 1669 patient-years of follow-up (145 patients had received at least 2 courses of rituximab), there was no evidence of an increase in the rate of infections compared with the data from the original phase II trials
Open label trial	Furst, 2010 [55]	Patients from both phase II studies	Rituximab vs. control group	

DANCER, Dose-ranging Assessment International Clinical Evaluation of Rituximab in RA trial; dSSc, diffuse cutaneous systemic sclerosis; DMARD, disease-modifying antirheumatic drug; F/u, follow-up; HBV, hepatitis B virus; LLN, lower limit of normal; MTX, methotrexate; NR, not reported; RA, rheumatoid arthritis; RCT, randomized controlled trial; REFLEX, Randomized Evaluation of Long-Term Efficacy of Rituximab trial; SIE, serious infection event; TNF, tumor necrosis factor.

group who did not receive rituximab, whereas the viral infection rate was significantly lower, and the rate of fungal infection was significantly higher in the rituximab group.<sup>61</sup> Nine out of 77 patients (11.68%) died after rituximab therapy, of which seven deaths (9.09%) were related to an infectious disease, compared to 1.55% in the controls ( $p = 0.0007$ ).<sup>61</sup>

An increased incidence of JC infection has also been described in transplant patients who receive rituximab.<sup>61</sup> Thus, after kidney transplantation, the use of rituximab is associated with a high risk of infectious disease and death related to infectious disease, and the independent predictive factors for infection-induced death were recipient age, bacterial and fungal infections, the combined use of rituximab, and anti-thymocyte globulin given for induction or anti-rejection therapy.<sup>61</sup>

In conclusion, although few data are available regarding the association of rituximab with infection in organ transplant recipients, data from renal transplant patients suggest an increased risk of infection with the use of rituximab in this population.

## 6. Types of infection

Table 3 outlines the most important types of infection associated with rituximab use.<sup>5,16,19,21,30,36,41,42,44,45,49,50,53,54,59,62–122</sup>

In a systematic review of the literature, Cornely et al.<sup>123</sup> analyzed 992 patients treated with either alemtuzumab, rituximab, or both; 409 patients (41.2%) were treated with alemtuzumab, 535 (53.9%) with rituximab, and 48 (4.9%) with both. The overall number of opportunistic infections (OI) diagnosed was 299 (30.1%). Etiologies were distributed as follows: 109 (36.5%) infections of unknown or unspecified origin, 100 (33.4%) viral reactivations, 44 (14.7%) bacterial infections, 26 (8.7%) fungal infections, 11 (3.7%) protozoal infections, and nine (3.0%) viral infections. Viral reactivations were most frequently due to CMV ( $n = 58$ , 19.4%), herpes simplex virus (HSV;  $n = 30$ , 10.0%), varicella zoster virus (VZV;  $n = 11$ , 3.7%), and Epstein–Barr virus (EBV;  $n = 1$ , 0.3%). Pneumonias accounted for 15.1% ( $n = 45$ ) of observed bacterial infections, and included 11 *Pneumocystis jiroveci* pneumonia (PCP) cases (3.7%) and 37 (12.4%) blood stream infection cases. Death attributable to OI occurred in 20 patients (2%). Optional prophylaxis of viral infections was reported in eight articles ( $n = 404$ , 40.7%), and optional prophylaxis for PCP in nine articles ( $n = 435$ , 43.9%).<sup>123</sup>

From our review of the literature a broad spectrum of infections has been associated with rituximab use in clinical trials, including respiratory tract infections (e.g., bronchopneumonia, nasopharyngitis, bronchitis, and sinusitis),<sup>53</sup> bacteremia,<sup>53</sup> sepsis,<sup>52,53</sup> urinary tract infections (including pyelonephritis),<sup>52,53</sup> gastroenteritis,<sup>52</sup> cellulitis,<sup>53</sup> septic arthritis,<sup>53</sup> cat-bite infection,<sup>53</sup> influenza,<sup>40,41</sup> de novo hepatitis B (hepatitis B virus (HBV)),<sup>41</sup> herpes zoster,<sup>40</sup> HSV infection,<sup>40</sup> adenovirus infection,<sup>40</sup> systemic candidiasis,<sup>56</sup> and aspergillosis.<sup>25</sup> At the time of writing, we could find no published reports of TB in rituximab-treated patients in clinical trials.

Data from case reports, case series, and retrospective studies also correlate rituximab use with the development of a variety of bacterial, viral, fungal, and parasitic infections (Table 3).

## 7. Bacterial infections

Representative bacterial infections attributed to rituximab use are shown in Table 3. A small increase in serious bacterial infections in RA patients receiving rituximab 1000 mg has been reported.<sup>24</sup> In addition, an increase in the rate of serious infections was seen in a cohort of 78 patients with RA who received a TNF- $\alpha$  blocking agent after rituximab treatment.<sup>50</sup> Thus, sinopulmonary



**Table 3**  
Cases in which addition of rituximab was likely associated with the development of infection

Infection	No. of patients	Pathogens (n)	References
Bacterial infections			
Sinopulmonary infection	ND	Pneumonia (7), <i>Staphylococcus aureus</i> pneumonia (1), <i>Streptococcus pneumoniae</i> pneumonia (1), bronchitis (1), upper respiratory tract infections, nasopharyngitis, bronchitis, and sinusitis	30, 36, 50, 53, 54, 59, 62–64
Bacteremia	ND	Septic shock (3), bacteremia (5)	30, 36, 44, 54, 59, 64
Bacterial diarrhea	ND	Shigella (1)	50
Urinary tract infections	ND	No pathogens reported, pyelonephritis	53, 54, 59
Skin infections	ND	Erysipelas, gangrenous cellulitis	50, 53, 59
Bone and joint infections	2	Infection of right hip (1), septic polyarthritis with <i>Ureaplasma urealyticum</i> (1)	50, 65
Dental abscess	1		49
Listeriosis	1		81
Cat scratch disease	1		53
Mycobacterial infections			
Other non-tuberculous mycobacteria	4	Bacteremia caused by <i>Mycobacterium wolinskyi</i> (1), <i>M. avium</i> pleuritis (1), <i>M. avium</i> bacteremia (1), disseminated <i>M. kansasii</i> infection (1)	66, 67
Viral infections			
CMV disease	26	CMV esophagitis (1), pneumonia (6), and enterocolitis (4), disseminated CMV infection (1)	5, 19, 21, 59, 63, 68–71, 101
VZV	13		5, 41, 44, 45, 72–74, 101, 112
HSV	6	Disseminated HSV2 (1)	41, 63, 75
Hepatitis	ND	Not specified (3), de novo hepatitis B (2), HBV reactivation (21 cases in HBsAg-neg patients), HCV (2), HEV infection (1)	5, 44, 45, 53, 76–94, 107, 119, 120, 122
Gastroenteritis	4		50, 53, 95
Parvovirus	2		96, 97
Enterovirus	3	Enteroviral meningoencephalitis	98–100
Echovirus	1		112
JC virus	76	52 patients had lymphoproliferative disorders, two had SLE, one had rheumatoid arthritis (and oropharyngeal cancer that had been treated previously with chemotherapy and radiotherapy), one had idiopathic autoimmune pancytopenia, and one patient with NHL had a concomitant autoimmune hemolytic anemia	101–104
BK virus	1	BK virus CNS infection	105, 106
RSV	2		107, 108
West Nile virus	3		109–111
Influenza A virus	2		53, 112
Fungal infections			
Fungal infections (not specified)		Fungal pneumonia	30
Candida infections	4	esophagitis (1), candidemia (3)	30
<i>Pneumocystis jirovecii</i> (carinii)	13	Pneumonia	30, 42, 63, 113–116
<i>Aspergillus</i> spp	4	Aspergillosis	16, 117–119
arasitic infections			
<i>Babesia microti</i>	8	Babesiosis	121

CMV, cytomegalovirus; CNS, central nervous system; HBV, hepatitis B virus; HCV, hepatitis C virus; HEV, hepatitis E virus; HBsAg, hepatitis B surface antigen; HSV, herpes simplex virus; ND, not determined; NHL, non-Hodgkin lymphoma; RSV, respiratory syncytial virus; SLE, systemic lupus erythematosus; VZV, varicella zoster virus.

infections are the most common bacterial infections that have been described in association with the use of rituximab, but further data from randomized controlled studies are needed to establish this association.

### 8. Mycobacterial infections

Several recent studies suggest that peripheral B cells are important in the host defense against mycobacteria.<sup>30,66,67</sup> Past history suggestive of TB was an exclusion criterion in the clinical trials of rituximab in RA, and in the vast majority of cases, study patients had previously received TNF inhibitors; nevertheless no reactivation of TB occurred. In NHL clinical trials where history of

TB was not an exclusion criterion, no evidence of an increased incidence of TB was noted.<sup>5</sup> Infection with other mycobacteria has rarely been associated with rituximab. More specifically, bacteremia caused by *Mycobacterium wolinskyi* or *Mycobacterium avium*, *M. avium* pleuritis, and disseminated *Mycobacterium kansasii* infections have all been described.<sup>66,67</sup> Since it is not clear whether rituximab or other immunosuppressants that were simultaneously administered promoted disease progression or caused mycobacterial disease, clinicians should remain vigilant for mycobacterial infections in patients selected for these therapies. Thus, there is an open issue regarding TB screening prior to rituximab initiation. The authors believe that such screening should be performed.

## 9. Viral infections

Data on the true incidence of viral infections after rituximab therapy are poor. Co-administration with other cytotoxic chemotherapeutic agents and the intensity and duration of T-cell-mediated immune suppression are significant cofactors increasing the infectious risk.<sup>41</sup> Humoral dysfunction related to rituximab therapy may cause loss of neutralization of free viral particles by specific antibodies and an increase in serious viral infections; this hypothesis needs further investigation.

Reactivation of chronic HBV infection is one of the most frequently reported serious viral infections.<sup>80,82,85–89,107,120</sup> In one RCT, opportunistic viral infections reported included three dermatomal herpes zoster infections and four localized herpes simplex infections.<sup>5</sup> Many isolated cases of other viral infections e.g. CMV, VZV, West Nile virus, influenza A, JC virus, BK virus, parvovirus, and enterovirus have been associated with rituximab use (Table 3).<sup>5</sup>

Upper respiratory tract viral infections were most frequently reported, however in most studies infection sites were not specified. In a review of 64 cases of severe viral infection after rituximab treatment, the most frequently experienced viral infections were HBV (39.1%,  $n = 25$ ), CMV (23.4%,  $n = 15$ ), VZV (9.4%,  $n = 6$ ), and others (28.1%,  $n = 18$ ).<sup>5</sup>

In conclusion, it is still unclear whether rituximab adds to the risk of viral infection above that conferred by chemotherapy alone; this association has been studied mainly with particular viral infections including HBV, hepatitis C virus (HCV), herpes virus, and JC virus infection.

## 10. HBV reactivation

A recent review of the literature revealed that the most frequent viral infection complicating rituximab therapy for lymphoma was hepatitis B infection. HBV reactivation accounted for 39% of the reported cases, resulting in a high mortality of 52% due to hepatic failure.<sup>5,77,124</sup> There are increasing reports of HBV reactivation following rituximab therapy, either when used alone or in combination with chemotherapy.<sup>125</sup> While the addition of rituximab to CHOP chemotherapy may increase the risk of HBV reactivation, the precise magnitude of the increase is not clear with the available data.<sup>80,82,85–89,107,120</sup> The use of rituximab in hepatitis B surface antigen (HBsAg)-positive patients can be continued provided they receive a prophylactic antiviral for a prolonged duration (up to 6 months) after cessation of chemotherapy.<sup>80</sup>

With the recent increase in rituximab use, HBV reactivation has been increasingly reported, even in patients who were thought to have cleared HBV (Table 3).<sup>80,92</sup> In a recent study of lymphoma patients with prior resolved hepatitis B, among HBsAg-negative/anti-hepatitis B core (HBc)-positive diffuse large B-cell lymphoma (DLBCL) patients treated with R-CHOP, 25% developed HBV reactivation.<sup>122</sup>

In addition to the use of rituximab, other potential factors associated with HBV reactivation include the absence of anti-HBs and male sex.<sup>5,77,124</sup> In one report it was shown that R-CHOP therapy for lymphoma can increase the levels of serum HBV DNA and the risk of intrafamilial HBV infection when given to HBV carriers.<sup>126</sup> Therefore, HBV reactivation may occur in the setting of rituximab use, and close monitoring of HBV DNA and liver function testing during rituximab therapy for at least 6 months after the completion of administration is required, with an alternative approach of prophylactic antiviral therapy to prevent this potentially fatal condition.

## 11. HCV reactivation

Rituximab-related liver dysfunction has not been described in HCV-positive patients receiving rituximab combination chemother-

apy.<sup>127</sup> Rituximab was reported to increase HCV viral load and alanine aminotransferase (ALT) levels in patients with HCV-related cryoglobulinemia (ALT was increased 10-fold and HCV viral load was increased 10-fold in one case)<sup>128</sup> and lymphoma (ALT was increased 25-fold in one case and HCV viral load was increased 5–10-fold in five cases).<sup>129</sup> Therefore, combined use of rituximab with chemotherapy poses an additional risk for exacerbation of HCV infection.

The influence of rituximab on HCV replication is not well understood. In one case, rituximab therapy for gastric cancer in a renal transplant recipient with chronic hepatitis C was complicated by cholestatic injury, an active hepatitis C replication with very high HCV RNA levels (increase of 1000-fold in HCV viral load after rituximab), and liver insufficiency.<sup>129</sup> In two patients who underwent ABO-incompatible renal transplantation and who received rituximab and had positive HCV RNA, cholestatic hepatitis C did not occur, but double-filtration plasmapheresis (DFPP) and cyclosporine failed to reduce hepatitis C viremia.<sup>130</sup> Another patient with refractory thrombotic thrombocytopenic purpura and membranoproliferative glomerulonephritis successfully treated with rituximab developed hepatitis C virus reactivation.<sup>93</sup> In another study of five HCV-infected patients with B-cell NHL undergoing treatment with rituximab-combination, all patients showed a significant increase in serum HCV RNA levels (at least 3-fold) with no occurrence of liver dysfunction.<sup>131</sup> Two of these patients received regimens without prednisone, suggesting that increased HCV viremia was associated not only with corticosteroid use, but also with anticancer agents or rituximab.<sup>132</sup> On the other hand, in one study, all seven patients who were HCV RNA-positive at the time of rituximab therapy for the treatment of transplant glomerulopathy, did not have significantly increased HCV RNA viremia or elevated levels of liver enzymes in the follow-up.<sup>63</sup>

In another report, 35 HCV-positive patients with DLBCL received rituximab-containing combination regimens without any hepatotoxicity; considering the short follow-up period of their study such toxicity might have been missed.<sup>132</sup> In another study of 44 HCV-positive patients with DLBCL treated with CHOP/CHOP-like regimens +/- rituximab, high viral load and evidence of active hepatitis or cirrhosis at liver biopsy was associated with more frequent hepatic failure under treatment and reduced survival.<sup>132</sup> Concomitant administration of R-CHOP plus anti-HCV treatment with pegylated interferon and ribavirin in four patients with HCV infection and DLBCL in the same study, resulted in excessive hematological toxicity.<sup>132</sup> On the other hand, sequential treatment with pegylated interferon plus ribavirin 3 months after chemotherapy in three patients was found effective, better tolerated, and resulted in a high rate of complete virus clearance.<sup>133,134</sup>

The lack of correlation between levels of HCV RNA and the extent of liver damage and variability of HCV RNA levels over time, limit strong conclusions regarding the association of rituximab with HCV infection and liver damage.<sup>128,129,132</sup> Kamar et al. found that rituximab therapy was not associated with a flare-up of chronic HCV infection in kidney transplant patients.<sup>61</sup> Finally, although HCV viral load can increase after rituximab treatment,<sup>5</sup> rituximab has been successfully used in HCV-associated cryoglobulinemia.<sup>5,128</sup> This indicates that rituximab may be an effective treatment for immunologic manifestations of HCV infection.

In summary, the association of rituximab with HCV infection remains very complex since rituximab may exacerbate HCV infection, but in other cases it has been used for the treatment of HCV-related autoimmune phenomena. Physicians should monitor HCV viral load during rituximab therapy.

## 12. Herpes infection

Infections with herpes viruses such as CMV, VZV, and HSV have been described in association with rituximab use.<sup>5,19,21,41,44,45,59,63,</sup>

68–74,101,112 The most common herpes virus associated with rituximab is CMV and 26 cases have been described in the literature.<sup>5,19,21,59,63,68–71,101</sup> In cases where CMV infection was specified, CMV enterocolitis, pneumonitis, and esophagitis were described (Table 3).

EBV infection has not been associated with rituximab to date. In one case with disseminated EBV infection, rituximab was ineffective in treating central nervous system infection with EBV.<sup>5</sup> Other data suggest that EBV persists in cell populations not depleted by rituximab, such as EBV-infected oropharyngeal epithelial cells.<sup>135</sup> Finally, 13 cases of infection with VZV<sup>5,41,44,45,72–74,101,112</sup> and five cases of HSV<sup>41,63,75</sup> have been described in association with rituximab therapy (Table 3). However, data from randomized controlled studies are needed to establish the association of rituximab use with the development of infections with herpes viruses.

### 13. Progressive multifocal leukoencephalopathy (PML)—JC virus

As of July 29, 2008, there were 76 reports in the manufacturer's global safety database of confirmed or suspected PML in patients receiving rituximab for any indication (69 in oncology indications, one autoimmune hemolytic anemia, five in other autoimmune disorders, and one in an unknown indication).<sup>136</sup> In one study rituximab was associated with a delay in the development of PML in HIV-negative patients with lymphoproliferative disorders treated with rituximab compared to patients treated with similar chemotherapeutic regimens without rituximab.<sup>137</sup> According to a report by the FDA, a total of 23 cases of PML have been documented in patients on rituximab for hematological malignancies mostly in combination with chemotherapy or stem cell transplantation.<sup>1</sup>

Carson et al. reported 57 rituximab-associated PML cases in HIV-negative patients. Median time from last rituximab dose to PML diagnosis was 5.5 months (range 0.3–66.0) and the overall incidence of fatality was 90%.<sup>104</sup> Kamar et al. showed that the incidence of JC viremia in rituximab-treated solid-organ transplant patients was 5.5%.<sup>61</sup> The exact role of rituximab in the development of PML is unclear, as humoral immunity is thought to be of little importance in the latency of JC virus, although the loss of the B-cell antigen presenting cell function may be critical. The effect of rituximab on T-lymphocyte function as a potential mechanism of JC virus reactivation remains an area of active inquiry.<sup>138</sup> Thus, the causal relationship between PML and rituximab remains unclear.

### 14. Fungal infections

Humoral immune deficiencies increase the risk for opportunistic fungal infection, and a reduction in antigen-specific cellular immunity impairs host protection against fungi. A recent study demonstrated that the addition of rituximab to CHOP increased the risk of fungal infection in a very elderly population.<sup>30</sup> *Pneumocystis jiroveci* (previously known as *Pneumocystis carinii*) pneumonia (PCP) may occur in a variety of hematological diseases.<sup>115</sup>

Although PCP has not been reported in the rituximab treatment arm of large RCTs, based on data from small trials, retrospective studies, and case reports, 13 cases of PCP have been described in the literature in association with rituximab use in patients with hematological malignancies.<sup>30,42,63,113–116</sup> Although these patients were also receiving other immunosuppressive medications, the strong temporal relationship between the rituximab infusions and the onset of the disease suggests that rituximab played a decisive role in the development of the opportunistic infection. Another study showed that the addition of rituximab to CHOP-like regimens, such as CHOP and CHOP-14, with or without etoposide, increased the incidence of PCP (13% in the rituximab arm vs. 4% in

the other arm).<sup>30</sup> No cases of PCP have been reported in patients with autoimmune disorders receiving rituximab as treatment.

Four case reports have been published that describe the occurrence of aspergillosis; one in a patient with autoimmune thrombocytopenic purpura and two in patients with post-transplant lymphoproliferative disorders that were treated with rituximab.<sup>139</sup> Four cases of *Candida* infection have also been described in association with use of rituximab.<sup>16,117–119</sup> As all these patients received extensive additional immunosuppressive treatment, the exact role of rituximab is difficult to define. However, experiments in B-cell deficient mice are in line with a mild impairment in antifungal immunity.<sup>139</sup>

The possibly increased susceptibility to *P. jiroveci* and fungal infection with the use of rituximab may suggest the need to administer prophylactic treatment with antifungals and/or trimethoprim-sulfamethoxazole during R-CHOP therapy. Due to the high incidence of *Aspergillus* and *Candida* infection, it may be more appropriate to use itraconazole or posaconazole rather than fluconazole as primary prophylaxis in these patients.<sup>140</sup>

### 15. Parasitic infections

Parasitic infections have rarely been described in association with rituximab use, although eight cases of babesiosis were described in one study. The authors concluded that rituximab effects on naive B cells that are responsible for antibody production in response to a new babesial infection could be involved.<sup>121</sup> More data are needed to elucidate the possible association of infliximab use with parasitic infections.

### 16. Immunization effects

The response to vaccination after rituximab could be reduced since rituximab causes B-cell depletion;<sup>141</sup> it is recommended that any vaccinations should be given before initiating treatment. A single study found that humoral responses to influenza vaccination were lower among patients treated with rituximab compared to RA patients who had received non-biological DMARDs and healthy controls.<sup>142</sup> Data from a recent RCT suggest that patients with RA treated with rituximab can be effectively and safely vaccinated, but to maximize response, polysaccharide and primary immunizations should be administered prior to rituximab infusions.<sup>143</sup> A recent clinical trial showed that rituximab reduces humoral responses following influenza vaccination in RA patients, with a modestly restored response 6–10 months after rituximab administration.<sup>143</sup> Recent studies suggest that anti-tetanus immune responses are decreased shortly after rituximab treatment, while immune responses to neoantigens and polysaccharides, which are B-cell-dependent, are decreased following rituximab treatment.<sup>142</sup>

Despite the suboptimal response, appropriate vaccination (such as against influenza or pneumococcus) should be administered when indicated.<sup>142,143</sup> Due to the paucity of data on the use of live attenuated vaccines while on rituximab, such vaccines should preferably be administered prior to rituximab use.

### 17. Limitations

We identified certain limitations in the studies that have examined the association of rituximab with infection. Firstly, the true infection rates may be higher than those reported in clinical trials since minor infections (grade 1 and grade 2) are possibly overlooked both by the patients and the doctors, and are under-reported. In certain reports (mostly case reports) authors did not provide adequate data regarding the strength of association of rituximab with infection and thus we could not independently analyze the strength of evidence regarding this association in these

cases. Furthermore, variances in reporting rates of neutropenia, immunoglobulin levels, infections as adverse events by the doctors, and the heterogeneity of the trials, the different patient selection criteria, and the different extent of bone marrow involvement by different subtypes of lymphomas may account for the differences in infection rates in clinical trials.

## 18. Conclusions

In conclusion, recent data show that rituximab maintenance therapy significantly increases the risk of both infection and neutropenia in patients with lymphoma or other hematological malignancies. Novel prophylaxis and/or pre-emptive treatment strategies should be tailored for these patients when treated with rituximab. On the other hand, data available to date do not indicate an increased risk of infection when using rituximab compared with concurrent control treatments in RA. However, there is a lack of sufficient long-term data to allow such a statement to be definitively made and caution regarding infections should continue to be exercised, especially in patients who have received repeated courses of rituximab, are receiving other immunosuppressants concurrently, and in those whose immunoglobulin levels have fallen below the normal range. Further studies are needed to clarify the association of rituximab with infection. Education of physicians and patients about the association of rituximab with infectious complications, monitoring of absolute neutrophil count and immunoglobulin levels, identification of high-risk groups for the development of infectious complications, and timely vaccination of these groups are clearly needed.

## Conflict of interest statement

The authors have no conflict of interest to declare.

## References

- [1] US Food and Drug Administration. FDA alert: rituximab (marketed as Rituxan). Available at: <http://www.fda.gov/Drugs/DrugSafety/Postmarket-DrugSafetyInformationforPatientsandProviders/ucm109106.htm> (accessed August 1, 2009).
- [2] Coiffier B. Treatment of non-Hodgkin's lymphoma: a look over the past decade. *Clin Lymphoma Myeloma* 2006;**7**(Suppl 1):S7–13.
- [3] Czuczman MS, Weaver R, Alkuzweny B, Berlefin J, Grillo-Lopez AJ. Prolonged clinical and molecular remission in patients with low-grade or follicular non-Hodgkin's lymphoma treated with rituximab plus CHOP chemotherapy: 9-year follow-up. *J Clin Oncol* 2004;**22**:4711–6.
- [4] Dass S, Vital EM, Emery P. Rituximab: novel B-cell depletion therapy for the treatment of rheumatoid arthritis. *Expert Opin Pharmacother* 2006;**7**:2559–70.
- [5] Aksoy S, Harputluoglu H, Kilickap S, Dede DS, Dizdar O, Altundag K, Barista I. Rituximab-related viral infections in lymphoma patients. *Leuk Lymphoma* 2007;**48**:1307–12.
- [6] Lund FE, Hollifield M, Schuer K, Lines JL, Randall TD, Garvy BA. B cells are required for generation of protective effector and memory CD4 cells in response to Pneumocystis lung infection. *J Immunol* 2006;**176**:6147–54.
- [7] Sfikakis PP, Boletis JN, Lionaki S, Vigiaklis V, Fragiadaki KG, Iniotaki A, et al. Remission of proliferative lupus nephritis following B cell depletion therapy is preceded by down-regulation of the T cell costimulatory molecule CD40 ligand: an open-label trial. *Arthritis Rheum* 2005;**52**:501–13.
- [8] Sfikakis PP, Souliotis VL, Fragiadaki KG, Moutsopoulos HM, Boletis JN, Theofilopoulos AN. Increased expression of the FoxP3 functional marker of regulatory T cells following B cell depletion with rituximab in patients with lupus nephritis. *Clin Immunol* 2007;**123**:66–73.
- [9] Lazdina U, Alheim M, Nystrom J, Hultgren C, Borisova G, Sominskaya I, et al. Priming of cytotoxic T cell responses to exogenous hepatitis B virus core antigen is B cell dependent. *J Gen Virol* 2003;**84**:139–46.
- [10] Cattaneo C, Spedini P, Casari S, Re A, Tucci A, Borlenghi E, et al. Delayed-onset peripheral blood cytopenia after rituximab: frequency and risk factor assessment in a consecutive series of 77 treatments. *Leuk Lymphoma* 2006;**47**:1013–7.
- [11] Castagnola E, Dallorso S, Faraci M, Morreale G, Di Martino D, Cristina E, et al. Long-lasting hypogammaglobulinemia following rituximab administration for Epstein–Barr virus-related post-transplant lymphoproliferative disease preemptive therapy. *J Hematother Stem Cell Res* 2003;**12**:9–10.
- [12] Lim SH, Esler WV, Zhang Y, Zhang J, Periman PO, Burris C, et al. B-cell depletion for 2 years after autologous stem cell transplant for NHL induces prolonged hypogammaglobulinemia beyond the rituximab maintenance period. *Leuk Lymphoma* 2008;**49**:152–3.
- [13] Lim SH, Zhang Y, Wang Z, Esler WV, Beggs D, Pruitt B, et al. Maintenance rituximab after autologous stem cell transplant for high-risk B-cell lymphoma induces prolonged and severe hypogammaglobulinemia. *Bone Marrow Transplant* 2005;**35**:207–8.
- [14] Tirelli U, Spina M, Jaeger U, Nigra E, Blanc PL, Liberati AM, et al. Infusional CDE with rituximab for the treatment of human immunodeficiency virus-associated non-Hodgkin's lymphoma: preliminary results of a phase I/II study. *Recent Results Cancer Res* 2002;**159**:149–53.
- [15] Kimby E. Tolerability and safety of rituximab (MabThera). *Cancer Treat Rev* 2005;**31**:456–73.
- [16] Verschuuren EA, Stevens SJ, van Imhoff GW, Middeldorp JM, de Boer C, Koeter G, et al. Treatment of posttransplant lymphoproliferative disease with rituximab: the remission, the relapse, and the complication. *Transplantation* 2002;**73**:100–4.
- [17] Saikia TK, Menon H, Advani SH. Prolonged neutropenia following anti CD20 therapy in a patient with relapsed follicular non-Hodgkin's lymphoma and corrected with IVIG. *Ann Oncol* 2001;**12**:1493–4.
- [18] Yokohama A, Tsukamoto N, Uchiiumi H, Handa H, Matsushima T, Karasawa M, et al. Durable remission induced by rituximab-containing chemotherapy in a patient with primary refractory Burkitt's lymphoma. *Ann Hematol* 2004;**83**:120–3.
- [19] Lee MY, Chiou TJ, Hsiao LT, Yang MH, Lin PC, Poh SB, et al. Rituximab therapy increased post-transplant cytomegalovirus complications in Non-Hodgkin's lymphoma patients receiving autologous hematopoietic stem cell transplantation. *Ann Hematol* 2008;**87**:285–9.
- [20] Lin PC, Hsiao LT, Poh SB, Wang WS, Yen CC, Chao TC, et al. Higher fungal infection rate in elderly patients (more than 80 years old) suffering from diffuse large B cell lymphoma and treated with rituximab plus CHOP. *Ann Hematol* 2007;**86**:95–100.
- [21] Unluturk U, Aksoy S, Yonem O, Bayraktar Y, Tekuzman G. Cytomegalovirus gastritis after rituximab treatment in a non-Hodgkin's lymphoma patient. *World J Gastroenterol* 2006;**12**:1978–9.
- [22] Cabanillas F, Liboy I, Pavia O, Rivera A. High incidence of non-neutropenic infections induced by rituximab plus fludarabine and associated with hypogammaglobulinemia: a frequently unrecognized and easily treatable complication. *Ann Oncol* 2006;**17**:1424–7.
- [23] Aksoy S, Dizdar O, Hayran M, Harputluoglu H. Infectious complications of rituximab in patients with lymphoma during maintenance therapy: a systematic review and meta-analysis. *Leuk Lymphoma* 2009;**50**:357–65.
- [24] Furst DE, Breedveld FC, Kalden JR, Smolen JS, Burmester GR, Sieper J, et al. Updated consensus statement on biological agents for the treatment of rheumatic diseases, 2007. *Ann Rheum Dis* 2007;**66**(Suppl 3):iii2–22.
- [25] Furst DE, Keystone EC, Kirkham B, Kavanaugh A, Fleischmann R, Mease P, et al. Updated consensus statement on biological agents for the treatment of rheumatic diseases, 2008. *Ann Rheum Dis* 2008;**67**(Suppl 3):iii2–25.
- [26] Rafailidis PI, Kakisi OK, Vardakas K, Falagas ME. Infectious complications of monoclonal antibodies used in cancer therapy: a systematic review of the evidence from randomized controlled trials. *Cancer* 2007;**109**:2182–9.
- [27] Gurcan HM, Keskin DB, Stern JN, Nitzberg MA, Shekhani H, Ahmed AR. A review of the current use of rituximab in autoimmune diseases. *Int Immunopharmacol* 2009;**9**:10–25.
- [28] Vidal L, Gafter-Gvili A, Leibovici L, Shpilberg O. Rituximab as maintenance therapy for patients with follicular lymphoma. *Cochrane Database Syst Rev* 2009 (2) CD006552.
- [29] Eve HE, Lynch D, Qian W, Ross M, Seymour JF, Smith P, et al. Toxicity of fludarabine and cyclophosphamide with or without rituximab as initial therapy for patients with previously untreated mantle cell lymphoma: results of a randomised phase II study. *Leuk Lymphoma* 2009;**50**:211–5.
- [30] Kaplan LD, Lee JY, Ambinder RF, Sparano JA, Cesarman E, Chadburn A, et al. Rituximab does not improve clinical outcome in a randomized phase 3 trial of CHOP with or without rituximab in patients with HIV-associated non-Hodgkin lymphoma: AIDS-Malignancies Consortium Trial 010. *Blood* 2005;**106**:1538–43.
- [31] Lenz G, Dreyling M, Hoster E, Wormann B, Duhrsen U, Metzner B, et al. Immunochemotherapy with rituximab and cyclophosphamide, doxorubicin, vincristine, and prednisone significantly improves response and time to treatment failure, but not long-term outcome in patients with previously untreated mantle cell lymphoma: results of a prospective randomized trial of the German Low Grade Lymphoma Study Group (GLSG). *J Clin Oncol* 2005;**23**:1984–92.
- [32] Hiddemann W, Kneba M, Dreyling M, Schmitz N, Lengfelder E, Schmits R, et al. Frontline therapy with rituximab added to the combination of cyclophosphamide, doxorubicin, vincristine, and prednisone (CHOP) significantly improves the outcome for patients with advanced-stage follicular lymphoma compared with therapy with CHOP alone: results of a prospective randomized study of the German Low-Grade Lymphoma Study Group. *Blood* 2005;**106**:3725–32.
- [33] Feugier P, Van Hoof A, Sebban C, Solal-Celigny P, Bouabdallah R, Ferme C, et al. Long-term results of the R-CHOP study in the treatment of elderly patients with diffuse large B-cell lymphoma: a study by the Groupe d'Etude des Lymphomes de l'Adulte. *J Clin Oncol* 2005;**23**:4117–26.
- [34] Coiffier B, Lepage E, Briere J, Herbrecht R, Tilly H, Bouabdallah R, et al. CHOP chemotherapy plus rituximab compared with CHOP alone in elderly patients with diffuse large-B-cell lymphoma. *N Engl J Med* 2002;**346**:235–42.

- [35] Habermann TM, Weller EA, Morrison VA, Gascoyne RD, Cassileth PA, Cohn JB, et al. Rituximab-CHOP versus CHOP alone or with maintenance rituximab in older patients with diffuse large B-cell lymphoma. *J Clin Oncol* 2006;**24**:3121–7.
- [36] Pfreundschuh M, Trumper L, Osterborg A, Pettengell R, Trneny M, Imrie K, et al. CHOP-like chemotherapy plus rituximab versus CHOP-like chemotherapy alone in young patients with good-prognosis diffuse large-B-cell lymphoma: a randomised controlled trial by the MabThera International Trial (MInT) Group. *Lancet Oncol* 2006;**7**:379–91.
- [37] Forstpointner R, Dreyling M, Repp R, Hermann S, Hanel A, Metzner B, et al. The addition of rituximab to a combination of fludarabine, cyclophosphamide, mitoxantrone (FCM) significantly increases the response rate and prolongs survival as compared with FCM alone in patients with relapsed and refractory follicular and mantle cell lymphomas: results of a prospective randomized study of the German Low-Grade Lymphoma Study Group. *Blood* 2004;**104**:3064–71.
- [38] Marcus R, Imrie K, Belch A, Cunningham D, Flores E, Catalano J, et al. CVP chemotherapy plus rituximab compared with CVP as first-line treatment for advanced follicular lymphoma. *Blood* 2005;**105**:1417–23.
- [39] Herold M, Dolken G, Fiedler F, Franke A, Freund M, Helbig W, et al. Randomized phase III study for the treatment of advanced indolent non-Hodgkin's lymphomas (NHL) and mantle cell lymphoma: chemotherapy versus chemotherapy plus rituximab. *Ann Hematol* 2003;**82**:77–9.
- [40] Dungarwalla M, Evans SO, Riley U, Catovsky D, Dearden CE, Matutes E. High dose methylprednisolone and rituximab is an effective therapy in advanced refractory chronic lymphocytic leukemia resistant to fludarabine therapy. *Haematologica* 2008;**93**:475–6.
- [41] Del Poeta G, Del Principe MI, Buccisano F, Maurillo L, Capelli G, Luciano F, et al. Consolidation and maintenance immunotherapy with rituximab improve clinical outcome in patients with B-cell chronic lymphocytic leukemia. *Cancer* 2008;**112**:119–28.
- [42] Ennishi D, Terui Y, Yokoyama M, Mishima Y, Takahashi S, Takeuchi K, et al. Increased incidence of interstitial pneumonia by CHOP combined with rituximab. *Int J Hematol* 2008;**87**:393–7.
- [43] van Oers MH, Klasa R, Marcus RE, Wolf M, Kimby E, Gascoyne RD, et al. Rituximab maintenance improves clinical outcome of relapsed/resistant follicular non-Hodgkin lymphoma in patients both with and without rituximab during induction: results of a prospective randomized phase 3 intergroup trial. *Blood* 2006;**108**:3295–301.
- [44] Ghielemi M, Schmitz SF, Cogliatti S, Bertoni F, Waltzer U, Fey MF, et al. Effect of single-agent rituximab given at the standard schedule or as prolonged treatment in patients with mantle cell lymphoma: a study of the Swiss Group for Clinical Cancer Research (SAKK). *J Clin Oncol* 2005;**23**:705–11.
- [45] Hainsworth JD, Litchy S, Barton JH, Houston GA, Hermann RC, Bradof JE, et al. Single-agent rituximab as first-line and maintenance treatment for patients with chronic lymphocytic leukemia or small lymphocytic lymphoma: a phase II trial of the Minnie Pearl Cancer Research Network. *J Clin Oncol* 2003;**21**:1746–51.
- [46] Morrison VA, Rai KR, Peterson BL, Kolitz JE, Elias L, Appelbaum FR, et al. Impact of therapy with chlorambucil, fludarabine, or fludarabine plus chlorambucil on infections in patients with chronic lymphocytic leukemia: Intergroup Study Cancer and Leukemia Group B 9011. *J Clin Oncol* 2001;**19**:3611–21.
- [47] Byrd JC, McGrail LH, Hospenthal DR, Howard RS, Dow NA, Diehl LF. Herpes virus infections occur frequently following treatment with fludarabine: results of a prospective natural history study. *Br J Haematol* 1999;**105**:445–7.
- [48] Kanbayashi Y, Nomura K, Fujimoto Y, Yamashita M, Ohshiro M, Okamoto K, et al. Risk factors for infection in haematology patients treated with rituximab. *Eur J Haematol* 2009;**82**:26–30.
- [49] Lafyatis R, Kissin E, York M, Farina G, Viger K, Fritzler MJ, et al. B cell depletion with rituximab in patients with diffuse cutaneous systemic sclerosis. *Arthritis Rheum* 2009;**60**:578–83.
- [50] Genovese MC, Breedveld FC, Emery P, Cohen S, Keystone E, Matteson EL, et al. Safety of biologic therapies following rituximab treatment in rheumatoid arthritis patients. *Ann Rheum Dis* 2009;**68**:1894–7.
- [51] Emery P, Fleischmann R, Filipowicz-Sosnowska A, Schechtman J, Szczepanski L, Kavanaugh A, et al. The efficacy and safety of rituximab in patients with active rheumatoid arthritis despite methotrexate treatment: results of a phase IIB randomized, double-blind, placebo-controlled, dose-ranging trial. *Arthritis Rheum* 2006;**54**:1390–400.
- [52] Edwards JC, Szczepanski L, Szechinski J, Filipowicz-Sosnowska A, Emery P, Close DR, et al. Efficacy of B-cell-targeted therapy with rituximab in patients with rheumatoid arthritis. *N Engl J Med* 2004;**350**:2572–81.
- [53] Cohen SB, Emery P, Greenwald MW, Dougados M, Furie RA, Genovese MC, et al. Rituximab for rheumatoid arthritis refractory to anti-tumor necrosis factor therapy: results of a multicenter, randomized, double-blind, placebo-controlled, phase III trial evaluating primary efficacy and safety at twenty-four weeks. *Arthritis Rheum* 2006;**54**:2793–806.
- [54] Keystone E, Fleischmann R, Emery P, Furst DE, van Vollenhoven R, Bathon J, et al. Safety and efficacy of additional courses of rituximab in patients with active rheumatoid arthritis: an open-label extension analysis. *Arthritis Rheum* 2007;**56**:3896–908.
- [55] Furst DE. The risk of infections with biologic therapies for rheumatoid arthritis. *Semin Arthritis Rheum* 2010;**39**:327–46.
- [56] Salliot C, Dougados M, Gossec L. Risk of serious infections during rituximab, abatacept and anakinra treatments for rheumatoid arthritis: meta-analyses of randomised placebo-controlled trials. *Ann Rheum Dis* 2009;**68**:25–32.
- [57] Scemla A, Thervet E, Martinez F. Safety of rituximab therapy for prevention or treatment of acute humoral rejection after renal transplantation. *Am J Transplant* 2008;**9**(Suppl 2):558.
- [58] Tsapepas DS, Aull MJ, Dadhnia D, Kapur S. Risk of infection in kidney-transplant recipients treated with rituximab. *Am J Transplant* 2008;**9**(Suppl 2):564.
- [59] Grim SA, Pham T, Thielke J, Sankary H, Oberholzer J, Benedetti E, et al. Infectious complications associated with the use of rituximab for ABO-incompatible and positive cross-match renal transplant recipients. *Clin Transplant* 2007;**21**:628–32.
- [60] Nishida H, Ishida H, Tanaka T, Amano H, Omoto K, Shirakawa H, et al. Cytomegalovirus infection following renal transplantation in patients administered low-dose rituximab induction therapy. *Transpl Int* 2009;**22**:961–9.
- [61] Kamar N, Milioto O, Puissant-Lubrano B, Esposito L, Pierre MC, Mohamed AO, et al. Incidence and predictive factors for infectious disease after rituximab therapy in kidney-transplant patients. *Am J Transplant* 2010;**10**:89–98.
- [62] Lovric S, Erdbruegger U, Kumpers P, Woywodt A, Koenecke C, Wedemeyer H, et al. Rituximab as rescue therapy in anti-neutrophil cytoplasmic antibody-associated vasculitis: a single-centre experience with 15 patients. *Nephrol Dial Transplant* 2009;**24**:179–85.
- [63] Rostaing L, Guilbeau-Frugier C, Fort M, Mekhlali L, Kamar N. Treatment of symptomatic transplant glomerulopathy with rituximab. *Transpl Int* 2009;**22**:906–13.
- [64] Zaja F, Bacigalupo A, Patriarca F, Stanzani M, Van Lint MT, Fili C, et al. Treatment of refractory chronic GVHD with rituximab: a GITMO study. *Bone Marrow Transplant* 2007;**40**:273–7.
- [65] Arber C, Buser A, Heim D, Weissler M, Tyndall A, Tichelli A, et al. Septic polyarthritides with *Ureaplasma urealyticum* in a patient with prolonged agammaglobulinemia and B-cell aplasia after allogeneic HSCT and rituximab pretreatment. *Bone Marrow Transplant* 2007;**40**:597–8.
- [66] Chen YC, Jou R, Huang WL, Huang ST, Liu KC, Lay CJ, et al. Bacteremia caused by *Mycobacterium wolinskyi*. *Emerg Infect Dis* 2008;**14**:1818–9.
- [67] Lutt JR, Pisculli ML, Weinblatt ME, Deodhar A, Winthrop KL. Severe nontuberculous mycobacterial infection in 2 patients receiving rituximab for refractory myositis. *J Rheumatol* 2008;**35**:1683–5.
- [68] Suzan F, Ammor M, Ribrag V. Fatal reactivation of cytomegalovirus infection after use of rituximab for a post-transplantation lymphoproliferative disorder. *N Engl J Med* 2001;**345**:1000.
- [69] Hirokawa M, Kawabata Y, Fujishima N, Yoshioka T, Sawada K. Prolonged reactivation of cytomegalovirus infection following successful rituximab therapy for Epstein-Barr virus-associated posttransplantation lymphoproliferative disorder. *Int J Hematol* 2007;**86**:291–2.
- [70] Lee KC, Chang CY, Chuang YC, Young MS, Huang CM, Yin WH, et al. Heart transplant coronary artery disease in Chinese recipients. *Transplant Proc* 2004;**36**:2380–3.
- [71] Stathis A, La Rosa S, Proserpio I, Micello D, Chini C, Pinotti G. Cytomegalovirus infection of endocrine system in a patient with diffuse large B-cell lymphoma. *Report of a case Tumori* 2009;**95**:119–22.
- [72] Aviles A, Castaneda C, Cleto S, Neri N, Huerta-Guzman J, Gonzalez M, et al. Rituximab and chemotherapy in primary gastric lymphoma. *Cancer Biother Radiopharm* 2009;**24**:25–8.
- [73] Bermudez A, Marco F, Conde E, Mazo E, Recio M, Zubizarreta A. Fatal visceral varicella-zoster infection following rituximab and chemotherapy treatment in a patient with follicular lymphoma. *Haematologica* 2000;**85**:894–5.
- [74] McIlwaine LM, Fitzsimons EJ, Soutar RL. Inappropriate antidiuretic hormone secretion, abdominal pain and disseminated varicella-zoster virus infection: an unusual and fatal triad in a patient 13 months post rituximab and autologous stem cell transplantation. *Clin Lab Haematol* 2001;**23**:253–4.
- [75] Scheinpflug K, Schalk E, Reschke K, Franke A, Mohren M. Diabetes insipidus due to herpes encephalitis in a patient with diffuse large cell lymphoma. *A case report Exp Clin Endocrinol Diabetes* 2006;**114**:31–4.
- [76] Coiffier B, Hepatitis B. B virus reactivation in patients receiving chemotherapy for cancer treatment: role of lamivudine prophylaxis. *Cancer Invest* 2006;**24**:548–52.
- [77] Yang SH, Kuo SH. Reactivation of hepatitis B virus during rituximab treatment of a patient with follicular lymphoma. *Ann Hematol* 2008;**87**:325–7.
- [78] Hui RK, Cheung WW, Zhang HY, Au WY, Yueng YH, Leung AY, et al. Kinetics and risk of de novo hepatitis B infection in HBsAg-negative patients undergoing cytotoxic chemotherapy. *Gastroenterology* 2006;**131**:59–68.
- [79] Ollier L, Tieulie N, Sanderson F, Heudier P, Giordanengo V, Fuzibet JG, et al. Chronic hepatitis after hepatitis E virus infection in a patient with non-Hodgkin lymphoma taking rituximab. *Ann Intern Med* 2009;**150**:430–1.
- [80] Yeo W, Chan TC, Leung NW, Lam WY, Mo FK, Chu MT, et al. Hepatitis B virus reactivation in lymphoma patients with prior resolved hepatitis B undergoing anticancer therapy with or without rituximab. *J Clin Oncol* 2009;**27**:605–11.
- [81] Ng HJ, Lim LC. Fulminant hepatitis B virus reactivation with concomitant listeriosis after fludarabine and rituximab therapy: case report. *Ann Hematol* 2001;**80**:549–52.
- [82] Law JK, Ho JK, Hoskins PJ, Erb SR, Steinbrecher UP, Yoshida EM. Fatal reactivation of hepatitis B post-chemotherapy for lymphoma in a hepatitis B surface antigen-negative, hepatitis B core antibody-positive patient: potential implications for future prophylaxis recommendations. *Leuk Lymphoma* 2005;**46**:1085–9.
- [83] Garcia-Rodriguez MJ, Canales MA, Hernandez-Maraver D, Hernandez-Navarro F. Late reactivation of resolved hepatitis B virus infection: an



- increasing complication post rituximab-based regimens treatment? *Am J Hematol* 2008;**83**:673–5.
- [84] Sarrecchia C, Cappelli A, Aiello P. HBV reactivation with fatal fulminating hepatitis during rituximab treatment in a subject negative for HBsAg and positive for HBsAb and HbCAb. *J Infect Chemother* 2005;**11**:189–91.
- [85] Niscola P, Del Principe MI, Maurillo L, Venditti A, Buccisano F, Piccioni D, et al. Fulminant B hepatitis in a surface antigen-negative patient with B-cell chronic lymphocytic leukaemia after rituximab therapy. *Leukemia* 2005;**19**:1840–1.
- [86] Sera T, Hiasa Y, Michitaka K, Konishi I, Matsuura K, Tokumoto Y, et al. Anti-HBs-positive liver failure due to hepatitis B virus reactivation induced by rituximab. *Intern Med* 2006;**45**:721–4.
- [87] Dervite I, Hober D, Morel P. Acute hepatitis B in a patient with antibodies to hepatitis B surface antigen who was receiving rituximab. *N Engl J Med* 2001;**344**:68–9.
- [88] Westhoff TH, Jochimsen F, Schmittle A, Stoffler-Meilicke M, Schafer JH, Zidek W, et al. Fatal hepatitis B virus reactivation by an escape mutant following rituximab therapy. *Blood* 2003;**102**:1930.
- [89] Yamagata M, Murohisa T, Tsuchida K, Okamoto Y, Tsunoda S, Nakamura M, et al. Fulminant B hepatitis in a surface antigen and hepatitis B DNA-negative patient with diffuse large B-cell lymphoma after CHOP chemotherapy plus rituximab. *Leuk Lymphoma* 2007;**48**:431–3.
- [90] Tsutsumi Y, Kawamura T, Saitoh S, Yamada M, Obara S, Miura T, et al. Hepatitis B virus reactivation in a case of non-Hodgkin's lymphoma treated with chemotherapy and rituximab: necessity of prophylaxis for hepatitis B virus reactivation in rituximab therapy. *Leuk Lymphoma* 2004;**45**:627–9.
- [91] Perceau G, Diris N, Estines O, Derancourt C, Levy S, Bernard P. Late lethal hepatitis B virus reactivation after rituximab treatment of low-grade cutaneous B-cell lymphoma. *Br J Dermatol* 2006;**155**:1053–6.
- [92] Takahashi T, Koike T, Hashimoto S, Miura T, Nakamura J, Yamada S, et al. A case of lamivudine-sensitive de novo acute hepatitis B induced by rituximab with the CHOP regimen for diffuse large B cell lymphoma. *Hepatol Int* 2009;**3**:316–22.
- [93] Mak SK, Lo KY, Lo MW, Chan SF, Lo KC, Wong YY, et al. Refractory thrombotic thrombocytopenic purpura and membranoproliferative glomerulonephritis successfully treated with rituximab: a case associated with hepatitis C virus infection. *Hong Kong Med J* 2009;**15**:201–8.
- [94] Koo YX, Tan DS, Tan IB, Tao M, Lim ST. Hepatitis B virus reactivation in a patient with resolved hepatitis B virus infection receiving maintenance rituximab for malignant B-cell lymphoma. *Ann Intern Med* 2009;**150**:655–6.
- [95] Hainsworth JD, Litchy S, Burris III HA, Scullin Jr DC, Corso SW, Yardley DA, et al. Rituximab as first-line and maintenance therapy for patients with indolent non-Hodgkin's lymphoma. *J Clin Oncol* 2002;**20**:4261–7.
- [96] Sharma VR, Fleming DR, Slone SP. Pure red cell aplasia due to parvovirus B19 in a patient treated with rituximab. *Blood* 2000;**96**:1184–6.
- [97] Isobe Y, Sugimoto K, Shiraki Y, Nishitani M, Koike K, Oshimi K. Successful high-titer immunoglobulin therapy for persistent parvovirus B19 infection in a lymphoma patient treated with rituximab-combined chemotherapy. *Am J Hematol* 2004;**77**:370–3.
- [98] Quartier P, Tournilhac O, Archimbaud C, Lazaro L, Chateleix C, Millet P, et al. Enteroviral meningoencephalitis after anti-CD20 (rituximab) treatment. *Clin Infect Dis* 2003;**36**:e47–9.
- [99] Padate BP, Keidan J. Enteroviral meningoencephalitis in a patient with non-Hodgkin's lymphoma treated previously with rituximab. *Clin Lab Haematol* 2006;**28**:69–71.
- [100] Kiani-Alikhan S, Skoulidis F, Barroso A, Nuovo G, Ushiro-Lumb I, Breuer J, et al. Enterovirus infection of neuronal cells post-rituximab. *Br J Haematol* 2009;**146**:333–5.
- [101] Goldberg SL, Pecora AL, Alter RS, Kroll MS, Rowley SD, Waintraub SE, et al. Unusual viral infections (progressive multifocal leukoencephalopathy and cytomegalovirus disease) after high-dose chemotherapy with autologous blood stem cell rescue and peritransplantation rituximab. *Blood* 2002;**99**:1486–8.
- [102] Harris HE. Progressive multifocal leukoencephalopathy in a patient with systemic lupus erythematosus treated with rituximab. *Rheumatology (Oxford)* 2008;**47**:224–5.
- [103] Freim Wahl SG, Folvik MR, Torp SH. Progressive multifocal leukoencephalopathy in a lymphoma patient with complete remission after treatment with cytostatics and rituximab: case report and review of the literature. *Clin Neuropathol* 2007;**26**:68–73.
- [104] Carson KR, Evens AM, Richey EA, Habermann TM, Focosi D, Seymour JF, et al. Progressive multifocal leukoencephalopathy after rituximab therapy in HIV-negative patients: a report of 57 cases from the Research on Adverse Drug Events and Reports project. *Blood* 2009;**113**:4834–40.
- [105] Ferrari A, Luppi M, Marasca R, Potenza L, Morselli M, Volzone F, et al. BK virus infection and neurologic dysfunctions in a patient with lymphoma treated with chemotherapy and rituximab. *Eur J Haematol* 2008;**81**:244–5.
- [106] Matteucci P, Magni M, Di Nicola M, Carlo-Stella C, Uberti C, Gianni AM. Leukoencephalopathy and papovavirus infection after treatment with chemotherapy and anti-CD20 monoclonal antibody. *Blood* 2002;**100**:1104–5.
- [107] Ozgonenel B, Moonka D, Savasan S. Fulminant hepatitis B following rituximab therapy in a patient with Evans syndrome and large B-cell lymphoma. *Am J Hematol* 2006;**81**:302.
- [108] Thomas DA, Faderl S, O'Brien S, Bueso-Ramos C, Cortes J, Garcia-Manero G, et al. Chemoimmunotherapy with hyper-CVAD plus rituximab for the treatment of adult Burkitt and Burkitt-type lymphoma or acute lymphoblastic leukemia. *Cancer* 2006;**106**:1569–80.
- [109] Mawhorter SD, Sierk A, Staugaits SM, Avery RK, Sobeks R, Prayson RA, et al. Fatal West Nile virus infection after rituximab/fludarabine-induced remission for non-Hodgkin's lymphoma. *Clin Lymphoma Myeloma* 2005;**6**:248–50.
- [110] Huang C, Slater B, Rudd R, Parchuri N, Hull R, Dupuis M, et al. First isolation of West Nile virus from a patient with encephalitis in the United States. *Emerg Infect Dis* 2002;**8**:1367–71.
- [111] Levi ME, Quan D, Ho JT, Kleinschmidt-Demasters BK, Tyler KL, Grazia TJ. Impact of rituximab-associated B-cell defects on West Nile virus meningoencephalitis in solid organ transplant recipients. *Clin Transplant* 2009;**24**:223–8. 2010.
- [112] Byrd JC, Peterson BL, Morrison VA, Park K, Jacobson R, Hoke E, et al. Randomized phase 2 study of fludarabine with concurrent versus sequential treatment with rituximab in symptomatic, untreated patients with B-cell chronic lymphocytic leukemia: results from Cancer and Leukemia Group B 9712 (CALGB 9712). *Blood* 2003;**101**:6–14.
- [113] Chang H, Yeh HC, Su YC, Lee MH. *Pneumocystis jirovecii* pneumonia in patients with non-Hodgkin's lymphoma receiving chemotherapy containing rituximab. *J Chin Med Assoc* 2008;**71**:579–82.
- [114] Brusamolino E, Rusconi C, Montalbetti L, Gargantini L, Uziel L, Pinotti G, et al. Dose-dense R-CHOP-14 supported by pegfilgrastim in patients with diffuse large B-cell lymphoma: a phase II study of feasibility and toxicity. *Haematologica* 2006;**91**:496–502.
- [115] Kolstad A, Holte H, Fossa A, Lauritzen GF, Gaustad P, Torfoss D. *Pneumocystis jirovecii* pneumonia in B-cell lymphoma patients treated with the rituximab-CHOP-14 regimen. *Haematologica* 2007;**92**:139–40.
- [116] Sem M, Molberg O, Lund MB, Gran JT. Rituximab treatment of the anti-synthetase syndrome: a retrospective case series. *Rheumatology (Oxford)* 2009;**48**:968–71.
- [117] Fianchi L, Rossi E, Murri R, De Stefano V, Pagano L, Leone G. Severe infectious complications in a patient treated with rituximab for idiopathic thrombocytopenic purpura. *Ann Hematol* 2007;**86**:225–6.
- [118] van der Velden WJ, Blijlevens NM, Klont RR, Donnelly JP, Verweij PE. Primary hepatic invasive aspergillosis with progression after rituximab therapy for a post transplantation lymphoproliferative disorder. *Ann Hematol* 2006;**85**:621–3.
- [119] Streif W, Escuriola EC, Linde R, Kropshofer G, Zimmerhackl LB, Kreuz W. Inhibitor treatment by rituximab in congenital haemophilia A—two case reports. *Hamostaseologie* 2009;**29**:151–4.
- [120] Tsutsumi Y, Tanaka J, Kawamura T, Miura T, Kanamori H, Obara S, et al. Possible efficacy of lamivudine treatment to prevent hepatitis B virus reactivation due to rituximab therapy in a patient with non-Hodgkin's lymphoma. *Ann Hematol* 2004;**83**:58–60.
- [121] Krause PJ, Gewurz BE, Hill D, Marty FM, Vannier E, Foppa IM, et al. Persistent and relapsing babesiosis in immunocompromised patients. *Clin Infect Dis* 2008;**46**:370–6.
- [122] Fukushima N, Mizuta T, Tanaka M, Yokoo M, Ide M, Hisatomi T, et al. Retrospective and prospective studies of hepatitis B virus reactivation in malignant lymphoma with occult HBV carrier. *Ann Oncol* 2009;**20**:2013–7.
- [123] Cornely O, Ullmann A, Heidecke C, Karthaus M. Opportunistic infections (OI) following monoclonal antibody treatment Proceedings of the ASCO Annual Meeting 2005. *J Clin Oncol* 2005;**23**(Suppl):2562.
- [124] Wang F, Xu RH, Luo HY, Zhang DS, Jiang WQ, Huang HQ, et al. Clinical and prognostic analysis of hepatitis B virus infection in diffuse large B-cell lymphoma. *BMC Cancer* 2008;**8**:115.
- [125] Lok AS, McMahon BJ. Chronic hepatitis B. *Hepatology* 2007;**45**:507–39.
- [126] Aomatsu T, Komatsu H, Yoden A, Hosomi A, Miyazaki H, Sogo T, et al. Fulminant hepatitis B and acute hepatitis B due to intrafamilial transmission of HBV after chemotherapy for non-Hodgkin's lymphoma in an HBV carrier. *Eur J Pediatr* 2010;**169**:167–71.
- [127] Aksoy S, Abali H, Kilickap S, Erman M, Kars A. Accelerated hepatitis C virus replication with rituximab treatment in a non-Hodgkin's lymphoma patient. *Clin Lab Haematol* 2006;**28**:211–4.
- [128] Fabrizi F, Martin P, Elli A, Montagnino G, Banfi G, Passerini P, et al. Hepatitis C virus infection and rituximab therapy after renal transplantation. *Int J Artif Organs* 2007;**30**:445–9.
- [129] Ennishi D, Terui Y, Yokoyama M, Mishima Y, Takahashi S, Takeuchi K, et al. Monitoring serum hepatitis C virus (HCV) RNA in patients with HCV-infected CD20-positive B-cell lymphoma undergoing rituximab combination chemotherapy. *Am J Hematol* 2008;**83**:59–62.
- [130] Tsai MK, Yang CY, Wu MS, Lee PH. Application of rituximab to hepatitis C-positive ABO-incompatible renal transplantation. *Int J Artif Organs* 2009;**32**:308–9.
- [131] Visco C, Arcaini L, Brusamolino E, Burcheri S, Ambrosetti A, Merli M, et al. Distinctive natural history in hepatitis C virus positive diffuse large B-cell lymphoma: analysis of 156 patients from northern Italy. *Ann Oncol* 2006;**17**:1434–40.
- [132] Musto P, Dell'Olio M, La Sata A, Mantuano S, Cascavilla N. Diffuse B-large cell lymphomas (DLCL) with hepatitis-C virus (HCV) infection: clinical outcome and preliminary results of a pilot study combining R-CHOP with antiviral therapy. *Blood* 2005;**106**:2447.
- [133] Sansonno D, De Re V, Lauletta G, Tucci FA, Boiocchi M, Dammacco F. Monoclonal antibody treatment of mixed cryoglobulinemia resistant to interferon alpha with an anti-CD20. *Blood* 2003;**101**:3818–26.



- [134] Roccatello D, Baldovino S, Rossi D, Mansouri M, Naretto C, Gennaro M, et al. Long-term effects of anti-CD20 monoclonal antibody treatment of cryoglobulinaemic glomerulonephritis. *Nephrol Dial Transplant* 2004;**19**:3054–61.
- [135] Hoover SE, Kawada J, Wilson W, Cohen JL. Oropharyngeal shedding of Epstein–Barr virus in the absence of circulating B cells. *J Infect Dis* 2008;**198**:318–23.
- [136] Medicines and Healthcare Products Regulatory Agency (UK). Information sent to healthcare professionals in November 2008 about the safety of medicines. Available at: <http://www.mhra.gov.uk/Safetyinformation/Safetywarningsalertsandrecalls/Safetywarningsandmessagesformedicines/Monthlylistsofinformationforhealthcareprofessionalsonthesafetyofmedicines/CON031203> (accessed August 30, 2009).
- [137] Calabrese LH, Molloy ES, Huang D, Ransohoff RM. Progressive multifocal leukoencephalopathy in rheumatic diseases: evolving clinical and pathologic patterns of disease. *Arthritis Rheum* 2007;**56**:2116–28.
- [138] van der Kolk LE, Baars JW, Prins MH, van Oers MH. Rituximab treatment results in impaired secondary humoral immune responsiveness. *Blood* 2002;**100**:2257–9.
- [139] Montagnoli C, Bozza S, Bacci A, Gaziano R, Mosci P, Morschhauser J, et al. A role for antibodies in the generation of memory antifungal immunity. *Eur J Immunol* 2003;**33**:1193–204.
- [140] Glasmacher A, Prentice A, Gorschluter M, Engelhart S, Hahn C, Djulbegovic B, et al. Itraconazole prevents invasive fungal infections in neutropenic patients treated for hematologic malignancies: evidence from a meta-analysis of 3,597 patients. *J Clin Oncol* 2003;**21**:4615–26.
- [141] Looney RJ, Srinivasan R, Calabrese LH. The effects of rituximab on immunocompetency in patients with autoimmune disease. *Arthritis Rheum* 2008;**58**:5–14.
- [142] van Assen S, Holvast A, Benne CA, Posthumus MD, van Leeuwen MA, Voskuyl AE, et al. Humoral responses after influenza vaccination are severely reduced in patients with rheumatoid arthritis treated with rituximab. *Arthritis Rheum* 2010;**62**:75–81.
- [143] Bingham III CO, Looney RJ, Deodhar A, Halsey N, Greenwald M, Coddling C, et al. Immunization responses in rheumatoid arthritis patients treated with rituximab: results from a controlled clinical trial. *Arthritis Rheum* 2010;**62**:64–74.