

# *Mycoplasma pneumoniae*-associated Acute Hepatitis in an Adult Patient without Lung Infection

Shou-Wu Lee\*, Sheng-Shun Yang, Chi-Sen Chang, Hong-Jeh Yeh, Wai-Keung Chow

Division of Gastroenterology, Department of Internal Medicine, Taichung Veterans General Hospital, Taichung, Taiwan, R.O.C.

*Mycoplasma pneumoniae* is a major cause of respiratory infections in school-aged children. Most *M. pneumoniae* infections in adults involve the respiratory tract. Extrapulmonary manifestations of *M. pneumoniae* infection may be found in the skin, cardiovascular, neurologic and hematologic systems. Concomitant liver disease is rare in adults. Here, we report an unusual case of a patient who presented with fever and abdominal pain, but without pulmonary manifestations. The laboratory work-up demonstrated a hepatocellular pattern of acute hepatitis caused by *M. pneumoniae* infection. Symptoms subsided and laboratory parameters improved with antibiotics treatment. Thus, this case can help raise clinicians' awareness of the possibility of *M. pneumoniae* infection, with or without lung involvement, as a part of the evaluation of undetermined hepatitis. [J Chin Med Assoc 2009;72(4):204–206]

**Key Words:** acute hepatitis, adult, *Mycoplasma pneumoniae*

## Introduction

Viral hepatitis accounts for most cases of acute hepatitis. Some bacterial infections are often associated with acute hepatitis, such as *Salmonella*, *Rickettsia*, *Brucella* or *Mycoplasma pneumoniae*. *M. pneumoniae* is a major cause of respiratory infections in school-aged children and young adults.<sup>1</sup> Extrapulmonary manifestations of *M. pneumoniae* include the skin, neurologic involvement, hematologic complications, myocarditis, pericarditis and cholestatic hepatitis in children.<sup>2</sup> *M. pneumoniae* infection in adults usually occurs without liver involvement except in some rare cases.<sup>3</sup> Here, we present a case of acute hepatitis caused by *M. pneumoniae* without lung involvement. Reports of *M. pneumoniae*-associated acute hepatitis retrieved from MEDLINE are also reviewed.

## Case Report

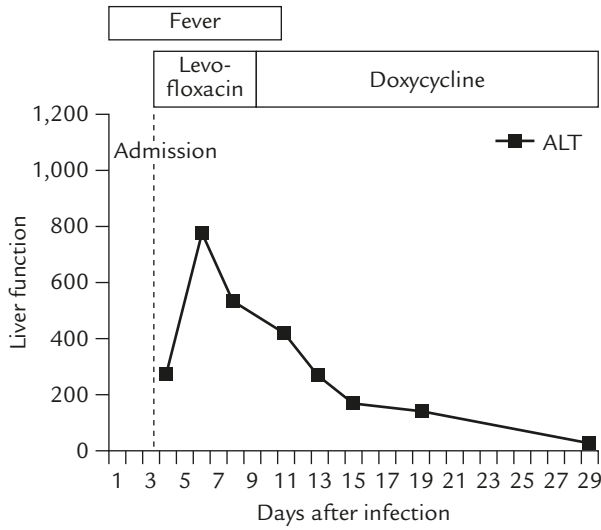
A 25-year-old woman who worked in an office, and who had no specific underlying illness, was admitted to our hospital with persistent fever, chills and abdominal pain in the right upper quadrant, all of which had

began 3 days before admission. She had no history of nausea, vomiting, diarrhea, cough, dysuria, arthralgia, night sweating or body weight loss. Other medical history, travel history and family history were unremarkable. She denied history of exposure to animals. She had been brought to the hospital for treatment of the abovementioned symptoms.

On physical examination, the patient was in distress. She had a body temperature of 37.6°C, heart rate of 70 beats/min, blood pressure of 130/90 mmHg, respiratory rate of 20 breaths/min and oxygen saturation of 99% under room air. There was no significant icteric sclera or yellowish skin. Neither rhonchi nor rales were heard over bilateral lung fields. Mild abdominal tenderness was found in the right upper quadrant, and the edge of the liver was felt 2–3 cm below the right costal margin. No lymphadenopathy or splenomegaly was found. Laboratory work-up demonstrated a white cell count of  $4.5 \times 10^3/\mu\text{L}$  (normal,  $4\text{--}11 \times 10^3/\mu\text{L}$ ), hemoglobin of 12 g/dL (normal, 11.3–15.3 g/dL), platelet count of  $140 \times 10^3/\mu\text{L}$  (normal,  $120\text{--}320 \times 10^3/\mu\text{L}$ ), blood urea nitrogen of 10 mg/dL (normal, 8–20 mg/dL), creatine of 0.8 mg/dL (normal, 0.6–1.2 mg/dL), aspartate aminotransferase (AST) of 380 U/L (normal, 4–44 U/L), alanine



\*Correspondence to: Dr Shou-Wu Lee, Division of Gastroenterology, Department of Internal Medicine, Taichung Veterans General Hospital, 160, Section 3, Chung-Kang Road, Taichung 407, Taiwan, R.O.C.  
E-mail: ericest@vghtc.gov.tw • Received: July 18, 2008 • Accepted: December 15, 2008



**Figure 1.** Time course of liver function parameters during the disease course. Note the rapid regression of fever within a week after the initiation of antibiotics. However, elevation of liver enzymes persisted for a month.

aminotransferase (ALT) of 273 U/L (normal, 8–38 U/L), alkaline phosphatase (ALP) of 79 U/L (normal, 50–190 U/L), total bilirubin of 0.5 (normal, 0.1–1.2 mg/dL), and C-reactive protein of 0.9 mg/dL (normal, <0.5 mg/dL). Prothrombin time was within normal limits (10.3 seconds). Chest X-ray showed no active lesion, and abdominal ultrasound did not reveal any specific findings. Abdominal computed tomography (CT) detected no hepatosplenomegaly. Other examinations were negative for HBsAg, HBeAg, anti-HBc IgM, anti-hepatitis C IgG, anti-hepatitis A IgM, antinuclear antibodies (ANA), anti-mitochondrial antibodies and anti-smooth muscle antibodies (ASMA). IgM antibodies against *Salmonella*, *Proteus*, Epstein-Barr virus (EBV) and cytomegalovirus (CMV) were negative. Anti-*M. pneumoniae* IgM antibodies (1:320) and cold agglutinin test (1:512) were positive. Liver biopsy was not performed because of the patient’s refusal.

Medication with intravenous levofloxacin was adapted initially to cover broadspectrum organisms, followed by oral doxycycline 5 days later after the diagnosis of *M. pneumoniae* infection was confirmed, and symptomatic recovery occurred on the 7<sup>th</sup> day of hospitalization. Liver function parameters showed that AST and ALT reached peak levels on the 2<sup>nd</sup> day of hospitalization (584 U/L and 777 U/L, respectively), and gradually returned to normal 1 month after the onset of symptoms (Figure 1). There was no hyperbilirubinemia, but anti-*M. pneumoniae* IgM was positive during hospitalization. No anti-*M. pneumoniae* IgG was detected during the admission period.

**Table 1.** Clinical features of patients with *Mycoplasma pneumoniae*-related acute hepatitis without lung involvement

Reference	Gender	Age (yr)	Symptoms	Liver function at admission (AST/ALT/ALP/BIL)	Treatment	Outcome
Narita et al <sup>7</sup>	Male	5	Fever, lymphadenopathy, polymorphous exanthema	2,375/1,488/ND/ND	IV clarithromycin	Fever regressed 5 d later; ALT normalized 1 mo later
Narita et al <sup>7</sup>	Male	10	Fever, lymphadenopathy	129/240/ND/ND	Oral minocycline	ALT normalized 3 wk later
Arav-Boger et al <sup>2</sup>	Male	10	Fever, maculopapular rash	674/524/310/2.8	Oral erythromycin	Fever regressed 2 wk later; ALT normalized 1 mo later; anti-IgM disappeared 3 mo later
Romero-Gomez et al <sup>3</sup>	Male	22	Fever, back pain	217/355/150/1.56	IV levofloxacin	Fever regressed 1 wk later; ALT normalized 1 mo later; anti-IgM disappeared 2 mo later
Romero-Gomez et al <sup>3</sup>	Female	22	Fever, asthenia	236/402/ND/ND	IV levofloxacin	Fever regressed 2 wk later; ALT normalized 1 mo later; anti-IgM disappeared 2 mo later
This case	Female	25	Fever, abdominal pain	584/777/79/0.5	IV levofloxacin, oral doxycycline	Fever regressed 1 wk later; ALT normalized 1 mo later

AST = aspartate aminotransferase; ALT = alanine aminotransferase; ALP = alkaline phosphatase; BIL = total bilirubin; ND = non-determined; IV = intravenous; anti-IgM = anti-*M. pneumoniae* antibodies.

The patient was later discharged from hospital and received clinical follow-up.

## Discussion

Most *M. pneumoniae* infections in adults involve the respiratory tract, and symptoms range from nonproductive cough to severe pneumonia.<sup>4</sup> Extrapulmonary manifestations of *M. pneumoniae* infection may be found in the skin, and cardiovascular, neurologic and hematologic systems.<sup>5</sup> Skin lesions include maculopapular rashes, erythema multiforme minor, and Stevens-Johnson syndrome. Cardiovascular involvement includes myocarditis, pericarditis and rheumatic fever-like syndrome. Neurologic complications include meningoencephalitis, aseptic meningitis, cerebellar ataxia and Guillain-Barre syndrome. Hematologic involvement includes hemolysis with positive Coombs' test and reticulocytosis. The immune-mediated damage by cross-reactive anti-*M. pneumoniae* antibodies is thought to be responsible for most of the extrapulmonary manifestations.<sup>2</sup>

Liver disease is rare and not considered as an extrapulmonary manifestation of infection with *M. pneumoniae* in adults.<sup>3</sup> The characteristic findings of patients with *M. pneumoniae*-associated acute hepatitis without lung infection are fever, elevated liver function test, positive IgM serology against *M. pneumoniae* followed by IgG seroconversion, with resolution by antibiotics and exclusion of other possible etiologies. Liver biopsy in these patients is usually nonspecific,<sup>6</sup> and it might not be necessary to confirm diagnosis.

A few cases of *M. pneumoniae*-associated acute hepatitis from MEDLINE are summarized in Table 1.<sup>2,3,7</sup> Acute hepatitis due to *M. pneumoniae* without lung infection has been largely documented in children with cholestatic pattern. However, although this fact remains controversial, adults with *M. pneumoniae* infection have demonstrated a hepatocellular pattern of liver enzymes without jaundice. The liver function parameters of our patient had similar characteristics,

suggesting differences among adults and children infected with *M. pneumoniae*.<sup>3</sup>

Consistent with the findings in previous studies,<sup>2,3,7</sup> our patient's fever subsided 1 week after institution of antibiotics. However, the persistent liver enzyme elevation may have been mediated by immunologic mechanisms such as cross-reactive antibodies induced by *M. pneumoniae* interacting with sialo-oligosaccharides on hepatic cells.<sup>4</sup> There is little evidence to indicate direct invasion of *M. pneumoniae*.<sup>3</sup>

In conclusion, we have reported an unusual case of a patient who presented with fever and abdominal pain. Laboratory work-up demonstrated a hepatocellular pattern of acute hepatitis caused by *M. pneumoniae* infection. Symptoms subsided and laboratory parameters improved under antibiotics administration. Thus, this case can help raise clinicians' awareness of the possibility of *M. pneumoniae* infection, with or without lung involvement, as a part of the evaluation of undetermined hepatitis.

## References

1. Feigin ED, Cherry JD, eds. *Textbook of Pediatric Infectious Disease*, 3<sup>rd</sup> edition. Philadelphia: WB Saunders, 1992:1866–76.
2. Arav-Boger R, Assia A, Spierer Z, Bujanover Y, Reif S. Cholestatic hepatitis as a main manifestation of *Mycoplasma pneumoniae* infection. *J Pediatr Gastroenterol Nutr* 1995;21:459–60.
3. Romero-Gomez M, Otero MA, Sanchez-Munoz D, Ramirez-Aros M, Larraona JL, Suarez-Garcia E, Vargas-Romero J. Acute hepatitis due to *Mycoplasma pneumoniae* infection without lung involvement in adult patients. *J Hepatol* 2006;44:827–8.
4. Grulich C, Baumert TF, Blum H. Acute *Mycoplasma pneumoniae* infection presenting as cholestatic hepatitis. *J Clin Microbiol* 2003;41:514–5.
5. Chen CJ, Juan CJ, Hsu ML, Lai YS, Lin SP, Cheng SN. *Mycoplasma pneumoniae* infection presenting as neutropenia, thrombocytopenia, and acute hepatitis in a child. *J Microbiol Immunol Infect* 2004;37:128–30.
6. Murray HW, Masur H, Senterfit LB, Roberts RB. The protean manifestations of *Mycoplasma pneumoniae* infection in adults. *Am J Med* 1975;58:229–42.
7. Narita M, Yamada S, Nakayama T, Sawada H, Nakajima M, Sageshima S. Two cases of lymphadenopathy with liver dysfunction due to *Mycoplasma pneumoniae* infection with mycoplasmal bacteraemia without pneumonia. *J Infect* 2001;42:154–6.