OBSERVATION

Familial Dementia With Lewy Bodies

A Clinical and Neuropathological Study of 2 Families

Debby W. Tsuang, MD, MSc; Aaron M. Dalan, BS; Charisma J. Eugenio, BS; Parvonah Poorkaj, PhD; Pornprot Limprasert, MD, PhD; Albert R. La Spada, MD, PhD; Ellen J. Steinbart, RN, MA; Thomas D. Bird, MD; James B. Leverenz, MD

Background: Dementia with Lewy bodies (DLB) is characterized by early dementia and associated visual hallucinations, parkinsonism, and fluctuations in cognition. Few families with DLB have been described with detailed clinical, pathological, and genetic assessments.

Objective: To investigate the clinical, neuropathological, and genetic characteristics of families with 2 or more autopsy-proven cases of DLB.

Design: Consecutive cases with the neuropathological diagnosis of DLB were reviewed as part of a case series. Families included in this study have 2 or more autopsy-proven cases of DLB available and a positive family history of dementia. We obtained clinical and neuropathological data on all first-degree relatives. Neuropathological evaluations included α-synuclein immunostaining for Lewy body detection. We conducted apolipoprotein E genotyping and sequenced the α-, β-, γ-synuclein, and parkin genes.

Setting: Subjects were selected from the neuropathology core of the University of Washington's Alzheimer's Disease Research Center.

Patients: The study investigated 2 families. Clinical information was obtained from 10 individuals in family 1 and 7 individuals in family 2. Neuropathological examinations were conducted in 3 individuals in family 1 and 2 individuals in family 2.

Main Outcome Measures: Each subject was examined for the presence of clinical symptoms and neuropathological findings consistent with DLB.

Results: While all affected individuals presented with dementia in both families, only individuals in family 1 developed visual hallucinations and delusions. Parkinsonism, if present, occurred later in the course of illness. Neuropathological examination revealed Lewy bodies in all patients, while 1 patient from each family also met the neuropathological criteria for Alzheimer disease. All affected individuals carried at least 1 *APOE* (apolipoprotein E) ϵ4 allele, while there were no nucleotide alterations in the synuclein or parkin genes.

Conclusions: Familial DLB exists, although there is substantial clinical and neuropathological heterogeneity within and between families. Additional clinicopathologic and genetic studies are necessary to further our understanding of DLB.

Arch Neurol. 2002;59:1622-1630

Author affiliations are listed at the end of this article.

DEMENTIA WITH Lewy bodies (DLB) is characterized clinically by dementia, visual hallucinations, parkinsonism, and fluctuations in cognition and attention.[1] Recent evidence[1] suggests that Lewy body (LB)–associated dementias may constitute the second largest neuropathological subgroup associated with dementing disorders, after Alzheimer disease (AD). There is substantial clinical and neuropathological overlap between DLB and AD and between DLB and Parkinson disease (PD). Patients with DLB are frequently misdiagnosed as having AD, although they are more likely to exhibit hallucinations and/or delusions earlier in the course of illness than patients with AD.[2] Similarly, motor signs and symptoms observed in patients with PD are frequently found in patients with DLB. However, parkinsonism (if present in patients with DLB) is often less severe than in patients with PD. If DLB is a pathophysiologically distinct entity, our ability to distinguish DLB from AD and PD has important clinical and research implications.

The Consortium on Dementia With Lewy Bodies[1] has developed guidelines for the clinical and neuropathological diagnosis of DLB. The guidelines for the clinical diagnosis of DLB require the presence of progressive cognitive decline and the presence of at least 2 of the following core features: (1) spontaneous parkinsonian signs and symptoms, (2) visual halluci-

©2002 American Medical Association. All rights reserved.

nations, and (3) fluctuations in consciousness early in the course of illness.[1] In addition, the DLB criteria stipulate that if parkinsonism precedes dementia by more than 1 year, the disorder is classified as PD with dementia. Although the specificity (correctly not diagnosing DLB) of these diagnostic criteria is high, the sensitivity (correctly diagnosing DLB) is modest.[3-5] One of the reasons for this finding may be the clinical variability observed among patients with DLB. While all patients exhibit cognitive decline, the presence of the other core features is less consistent. In particular, it is unclear why some individuals develop hallucinations and/or delusions while others do not.[6] One way to address these questions is to identify kindreds with familial DLB to investigate whether core clinical symptoms aggregate within these families.

Several studies have described families with inherited parkinsonism and dementia. However, most of those families are characterized by parkinsonism preceding dementia by many years.[7,8] A few described families have included some individuals who presented with dementia, some of whom develop comorbid parkinsonism while others never do.[8-10] These families may be examples of familial DLB. Unfortunately, there is a paucity of neuropathological description in these families, with LB pathological features confirmed at most in only 1 family member.[8] Therefore, it is difficult to assess whether all affected individuals had the same disorder.

Molecular genetic studies have identified multiple genetic risk factors in patients with AD[11] and PD.[12] However, few studies have investigated genetic risk factors in patients with DLB. The association between the *APOE* (apolipoprotein E) ϵ4 allele and DLB has been inconsistent.[13-16] In addition, other studies[17,18] have reported that genetic risk factors associated with PD (eg, *CYP2D6* and α-synuclein) are not present in patients with DLB. Additional linkage analysis and candidate gene studies in patients with DLB are necessary. Eventual identification of susceptibility genes in patients with DLB will improve the classification of this disorder and our understanding of the underlying pathophysiological features.

To investigate clinical and neuropathological variability and the genetic risk factors in patients with DLB, we identified several families with multiple affected individuals who presented with dementia and later developed parkinsonism. Instead of relying on the clinical diagnosis of DLB, we selected families based on the neuropathological diagnosis of DLB in 2 or more family members. Herein, we describe the clinical, neuropathological, and genetic characteristics of 2 families.

METHODS

Eight families at the University of Washington's Alzheimer's Disease Research Center with at least 1 autopsy-proven case of DLB and multiple other family members with dementia were initially eligible for this study. Two families had 2 or more autopsy-proven cases of DLB (according to the neuropathological criteria of McKeith et al[1]) and were included in the present study.

As approved by the University of Washington's Institutional Review Board, we obtained informed consent from family members who were willing to participate. Medical records were obtained and systematically reviewed for the presence of parkinsonian signs and symptoms, behavioral disturbances, and cognitive decline. Detailed clinical histories were obtained from the next of kin using a semistructured dementia questionnaire.[19] Medical records were obtained for 10 individuals in family 1 and 7 individuals in family 2. Because of inconsistent documentation and report of fluctuations in attention and cognition, we could not reliably assess these symptoms. Two of us (D.W.T. and J.B.L.) conducted in-person detailed neurological and behavioral assessments with 4 individuals in family 2.

Neuropathological examinations were performed in 3 individuals in family 1 and 2 individuals in family 2. All patients underwent a standard neuropathological workup, including hematoxylin-eosin (H&E), modified Bielschowsky, and thioflavine S staining. Of 5 autopsy cases, 4 had postmortem tissue available for additional immunohistological studies. In these cases, we performed α-synuclein immunostaining (antibody LB509, dilution, 1:400; Zymol, San Francisco, Calif) and extranigral sampling to fully characterize LB pathological features.[20-22] A neuropathological review for the presence of LBs in the substantia nigra (SN), hippocampus, parahippocampal gyrus, amygdala, and cingulate gyrus was conducted. We defined an LB "positive" case as one having either H&E-positive LB inclusions in the SN or greater than 5 α-synuclein–positive LB inclusions in an extra brainstem region. In addition, in the absence of LB inclusions in the SN, cases with 6 or more α-synuclein–positive cytoplasmic inclusions in the amygdala would also be considered as positive for LB pathological features. These latter cases would be classified as "amygdala predominant" DLB cases consistent with previous reports.[22,23]

Genomic DNA was extracted from lymphocytes or skin fibroblast culture. DNA from 11 individuals were available for *APOE* genotyping using the restriction digest methods of Hixson and Vernier.[24] Genomic DNA from 1 affected individual (randomly selected) in each family was screened for α-, β-, and γ-synuclein and parkin mutations. Polymerase chain reaction (PCR), with the use of primers flanking each exon, was performed. Primer sequences (including 3 new primers: A5R, A7-2F, and A7-1R), expected product sizes, and annealing temperature are described in detail elsewhere.[25] The complete genomic sequence encompassing the α-synuclein gene is available through GenBank (accession numbers AF163864 and NT_006204; NCBI, Bethesda, Md). The α-synuclein complementary DNA (accession number XM_003494) is encoded by 6 exons and 1 alternatively spliced (1′) exon that span a genomic distance of greater than 116 kb. Polymerase chain reaction products were purified using the QIA-quick purification kit (QIAGEN, Valencia, Calif) before ABI PRISM BigDye Terminator (ABI, Foster City, Calif) cycle sequencing on an ABI 377 sequencer. Both strands were sequenced. The β-synuclein gene, encoded by 5 exons, encompasses a genomic distance of approximately 12.8 kb (accession numbers AF053134-AF053136 and NT_006725). Previously published primer sets will be used for PCR amplification from genomic DNA.[26] The γ-synuclein gene is similarly encoded by 5 exons and spans 46 kb (excluding promoter sequences) (accession number AF044311). Primer pairs for genomic sequencing have been published previously.[27]

The parkin gene is encoded by 12 exons. Mutation screening methods used primer sets published by Kitada et al,[28] as well as nested primers for sequencing and new primer pairs designed to amplify genomic fragments containing a minimum of 150 nucleotides of flanking intronic sequence for each exon. The complete human genomic sequence for parkin is available through GenBank (http://www.ncbi.nlm.nih.gov), accession number NT_007122.[29,30] Exons and flanking intronic splice junctions were PCR-amplified, agarose gel–purified (Geneclean III; Bio101, Luton, Bedfordshire, England), and directly sequenced by dye-terminator cycle sequencing (BigDye) us-

©2002 American Medical Association. All rights reserved.

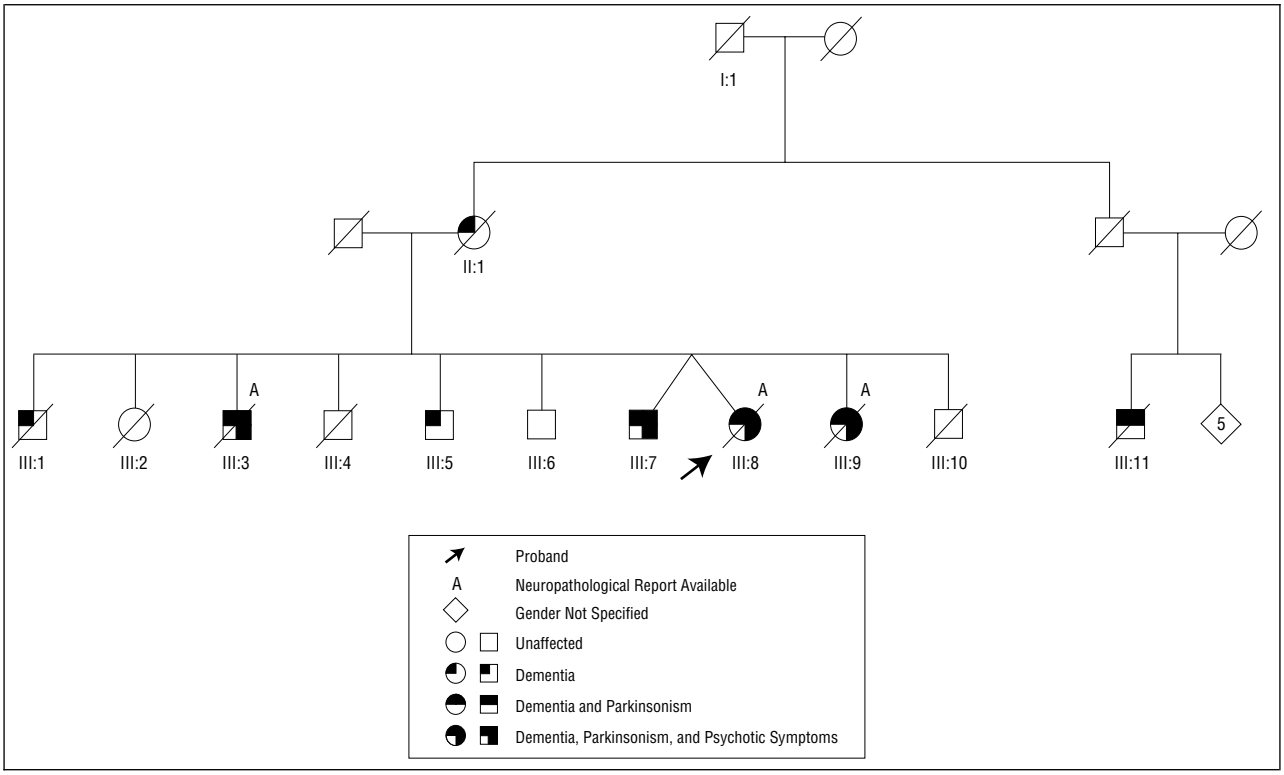

Figure 1. Pedigree from family 1. Circles indicate females; squares, males; and a slash through a symbol, deceased individuals.

ing an ABI 377 sequencer. Both strands were sequenced. Gene dosage analysis using real-time fluorescence-based PCR quantitation (ABI 7700 Sequence Detector) was performed to determine parkin exon copy number. Parkin exons were amplified with 5′ FAM/3′TAMRA (ABI) dual-labeled probes and multiplexed with the amplification of an 84 base pair fragment of a single copy human β-actin gene (chromosome 7; 5′-VIC/TAMRA-3′ [ABI] dual label probe) as an internal copy number control. Standard curves were generated for each parkin exon and for β-actin using control human genomic DNA. The number of PCR cycles required before the ABI 7700 detects the parkin exon product was plotted against the parkin standard curve, thus calculating a relative copy number for each exon. Parkin exon copy number was then normalized to the single copy actin gene within each multiplexed reaction and to a normal reference individual, thus determining the number of copies per genome. All experiments were performed in triplicate.

REPORT OF CASES

FAMILY 1

In this family, there were 8 affected individuals in 2 generations (**Figure 1**). Their mean age of onset was 70.9 (SD, 5.4) years, with a mean age at death of 77.2 (SD, 3.9) years. All 8 affected individuals exhibited cognitive decline as their first neuropsychiatric symptom. In addition, of the 8 individuals with dementia, 5 developed subsequent parkinsonism (resting tremor, cogwheel rigidity, and/or bradykinesia) and 4 exhibited psychotic symptoms (2 of these 4 had visual hallucinations) (**Table 1**). Brief descriptions of individuals in this family follow.

I:1

This subject read daily and worked in his garden until his death. There was no evidence of cognitive impairment or parkinsonism.

II:1

This subject developed dementia at the age of 72 years. She was unable to live on her own because of her forgetfulness. Her judgment was impaired, and she inadvertently started several stove fires. She did not have resting tremor, bradykinesia, or gait disturbance.

III:1

This subject had cognitive decline beginning around the age of 67 years. He could not manage his own finances. A review of medical records indicates that he was unable to comprehend directions during a physical examination. No formal cognitive testing was conducted. He did not have resting tremor, bradykinesia, or gait disturbances.

III:3

This subject was diagnosed as having AD with PD features at the age of 81 years. He initially had difficulty keeping track of his finances (at the age of 73 years) and had poor executive function and judgment. Later, he developed bradykinesia, stooped posture, axial rigidity, and cogwheel rigidity. He did not have resting tremor. He also developed paranoid ideation and called the police on at least 1 occasion. When the police came to investigate, he stated

©2002 American Medical Association. All rights reserved.

Table 1. Clinical Characteristics, Source of Information, and *APOE* Genotypes in Families 1 and 2*

Subject No.	Age of Onset, y	Dementia	Parkinsonism	Psychosis	Source of Information	*APOE* Genotype
			Family 1			
I:1	. . .	–	–	–	Hx	NA
II:1	72	+	–	–	Hx	NA
III:1	67	+	–	–	Hx and Med Rec	NA
III:3	73	+	+	+	Hx and Med Rec	ϵ3/ϵ4
III:5	79	+	–	–	Hx	ϵ3/ϵ4
III:6	. . .	–	–	–	Hx	ϵ3/ϵ4
III:7	77	+	+	+	Hx	ϵ3/ϵ4
III:8	67	+	+	+	Hx and Med Rec	ϵ3/ϵ4
III:9	63	+	+	+	Hx and Med Rec	ϵ3/ϵ4
III:11	69	+	+	–	Hx and Med Rec	ϵ4/ϵ4
			Family 2			
I:1	83	+	+	–	Hx, Med Rec, and PE	ϵ3/ϵ4
I:2	76	+	+	–	Hx, Med Rec, and PE	ϵ4/ϵ4
I:3	80	+	+	–	Hx and Med Rec	ϵ4/ϵ4
I:4	63	+	+	–	Hx, Med Rec, and PE	ϵ4/ϵ4
I:5	58	+	–	–	Hx and Med Rec	NA
I:7	59	+	–	–	Hx and Med Rec	NA

*APOE indicates apolipoprotein E; –, absent; Hx, clinical history; +, present; Med Rec, medical records; PE, face-to-face physical examination; NA, data not available; and ellipses, data not applicable.

Table 2. Clinical and Neuropathological Characteristics in 2 Families With DLB*

					Neuropathological Findings				
					Braak Staging† (AD Changes)		LBs		
		Clinical Features					SN		
Subject No.	Age of Onset, y	Dementia	PD	Psychosis	NFTs	SPs	H&E Staining	AS Staining	Amygdala (AS Staining)
				Family 1					
III:3	73	+	+	+	III	B	+	+	+
III:8	67	+	+	+	V	C	–	–	+
III:9	63	+	+	+	III	C	+	NA	NA
				Family 2					
I:5	58	+	–	–	III	C	+	+	+
I:7	59	+	–	–	VI	C	–	–	+

*DLB indicates dementia with Lewy bodies; PD, parkinsonism; AD, Alzheimer disease; LB, Lewy body; NFT, neurofibrillary tangle; SP, senile plaque; SN, substantia nigra; H&E, hematoxylin-eosin; AS, α-synuclein; +, present (in "Clinical Features" column) or positive (in "Neuropathological Findings" column); –, absent (in "Clinical Features" column) or negative (in "Neuropathological Findings" column); and NA, data not available.

†For Braak staging, see Braak and Braak.[31]

that a neighbor had actually made the telephone call. The neuropathological report and additional tissue specimens were available for this subject (**Table 2**).

III:5

This subject developed cognitive impairment at the age of 79 years. He was unable to organize his home or complete multistep tasks. The family reported an increase in irritability and agitation. He has accused his family of "trying to make me think I'm crazy." He did not have resting tremor, bradykinesia, or gait disturbances.

III:6

This subject does not have any evidence of cognitive decline. He continues to be physically and mentally active. He reads regularly and hikes 4.8 km at least once a week. He does not have resting tremor, bradykinesia, or gait disturbances.

III:7

This subject developed cognitive decline around the age of 77 years. He had difficulty remembering words and got lost while driving in his hometown. He developed gait instability and fell on several occasions. He also developed a stooped posture and bradykinesia, but did not have resting tremor. The patient had visual hallucinations, reported as seeing his deceased relatives. He believed that they lived with him and routinely conversed with them.

III:8

This subject first showed signs of cognitive decline at the age of 67 years. She became lost in her hometown and was unable to balance her checkbook. On physical examination, there was evidence of increased muscle tone, mild bradykinesia, and masked facies. She did not have resting tremor but was diagnosed as having PD at the age of 74

©2002 American Medical Association. All rights reserved.

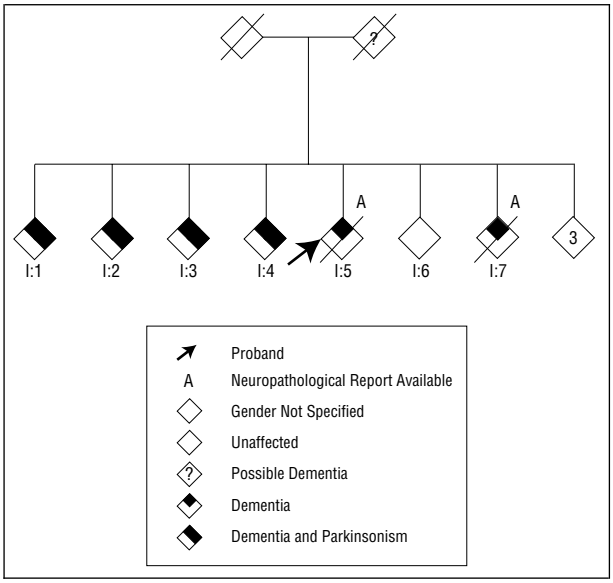

Figure 2. Pedigree from family 2. The pedigree has been altered to ensure confidentiality. A slash through a symbol indicates deceased individuals.

years. She also developed emotionally intense visual hallucinations, reported as seeing chickens pecking at her eyes. The neuropathological report and additional tissue specimens were available for this subject (Table 2).

III:9

This subject presented with cognitive deficits at the age of 63 years and was diagnosed as having AD at the age of 69 years. She was unable to maintain her home and developed problems with word finding. Physical examination findings were significant for mild cogwheel rigidity. However, there was no evidence of resting tremor or bradykinesia. She also developed paranoid ideations that the neighbors across the street were spying on her. She spent an extensive amount of time sitting by the window, making sure her neighbors would not bother her. The neuropathological report was available for this patient, but additional tissue specimens were unavailable for immunohistochemical staining (Table 2).

III:11

This subject developed cognitive impairment at the age of 69 years and was diagnosed as having AD at the age of 75 years. He was unable to handle his finances and got lost while driving in familiar neighborhoods. His wife reported that he had progressive bradykinesia and developed a stooped posture. No resting tremor or cogwheel rigidity was reported.

FAMILY 2

This family had 6 affected individuals in 1 generation (**Figure 2**). Their mean age of onset was 69.8 (SD, 11.1) years. All affected individuals presented initially with cognitive decline. In addition, 4 of the 6 individuals had parkinsonism that either presented concurrently with dementia or developed later in the disease. None of the affected individuals developed hallucinations or delusions (Table 1). Brief descriptions of individuals in this family follow.

I:1

This subject had evidence of mild cognitive impairment on neurological examination, with word recall difficulty at the age of 83 years. On physical examination, there was evidence of a mildly stooped posture, bradykinesia, and difficulty performing rapid alternating movements. S/he did not have resting tremor or cogwheel rigidity.

I:2

This subject developed problems managing his/her finances at the age of 76 years. S/he subsequently became lost in his/her own neighborhood. On physical examination, s/he had mild bradykinesia, stooped posture, mild postural instability, masked facies, and hypophonia. S/he did not have resting tremor or cogwheel rigidity.

I:3

This subject had mild cognitive impairment on neurological examination at the age of 80 years, difficulty with word recall, and difficulty with sentence completion. There was also evidence of gait instability, bradykinesia, and slowing of rapid alternating movements. There was no resting tremor or cogwheel rigidity.

I:4

This subject developed cognitive disturbances at the age of 63 years and was diagnosed as having AD at the age of 70 years. Initially, there was difficulty with word finding, short-term memory, and managing his finances. On physical examination, there was bradykinesia, a slightly stooped posture, and loss of facial expression. There was no resting tremor or cogwheel rigidity.

I:5

This subject first developed cognitive disturbance at the age of 58 years with problems managing finances. S/he was diagnosed as having AD at the age of 65 years and died at a care facility. There was a long history of alcohol dependence, including withdrawal symptoms such as delirium tremens. There was no evidence of resting tremor, bradykinesia, or cogwheel rigidity. The neuropathological report and additional tissue specimens were available for this subject (Table 2).

I:6

This subject had no evidence of cognitive impairment or functional decline at the age of 74 years. There was no evidence of resting tremor, bradykinesia, or cogwheel rigidity.

I:7

This subject had short-term memory loss at the age of 59 years. S/he subsequently became apraxic, exempli-

©2002 American Medical Association. All rights reserved.

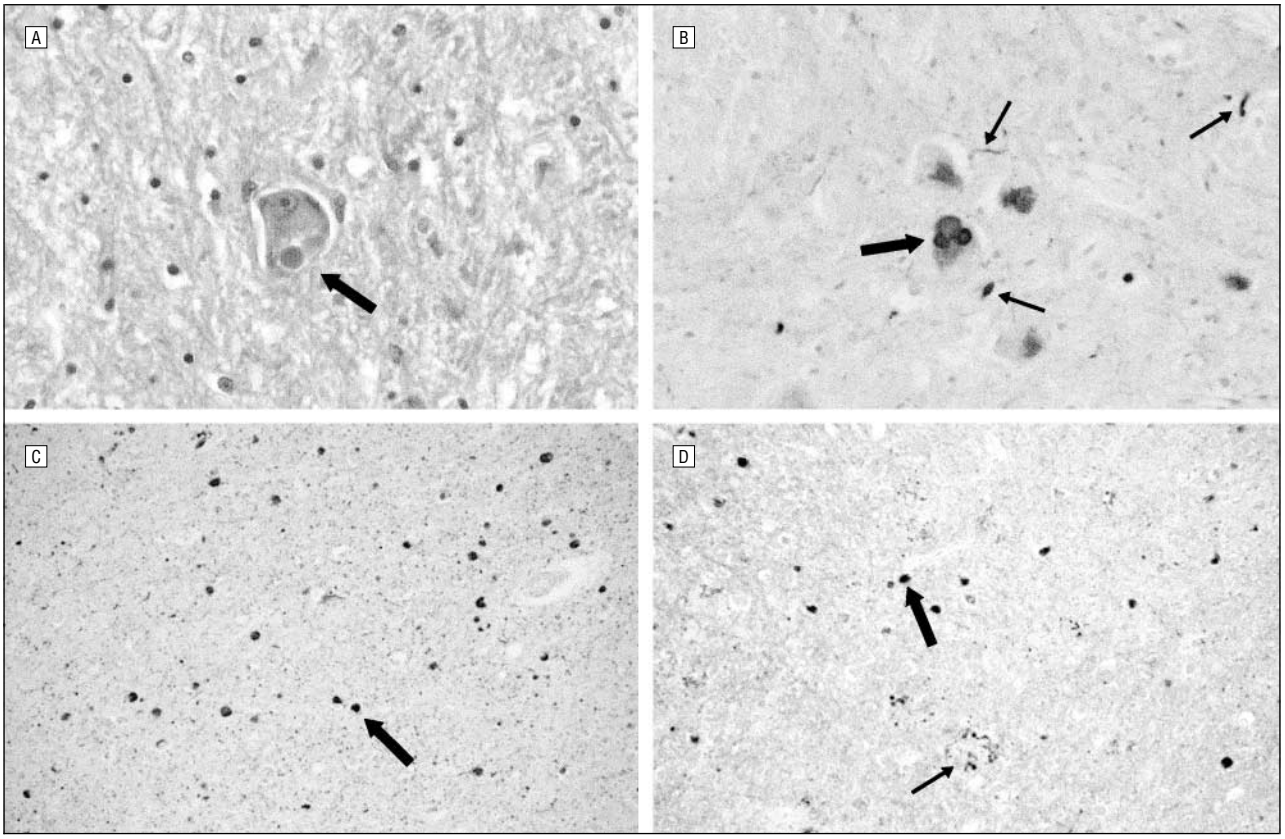

Figure 3. A, Lewy body (arrow) in a substantia nigra neuron of a patient with dementia with Lewy bodies (hematoxylin-eosin, original magnification, ×500). B, α-Synuclein immunostaining of Lewy bodies (large arrow) and Lewy neurites (small arrows) in the substantia nigra (original magnification, ×500). C, α-Synuclein–immunopositive inclusions (arrow) in the amygdala of a patient with additional brainstem Lewy bodies (original magnification, ×250). D, α-Synuclein–immunopositive inclusions (large arrow) and neuritic plaques (small arrow) in a patient without brainstem Lewy bodies (original magnification, ×250). Parts A, B, and C are from subject III:3 in family 1; part D, subject I:7 in family 2.

fied by his/her inability to use tools or utensils. The patient had a long history of alcohol abuse. S/he was admitted for alcohol detoxification several times. The medical history was significant for delirium tremens, with reports of visual hallucinations of bugs and snakes. These symptoms resolved once s/he was treated for alcohol withdrawal. There was mild bradykinesia, but no resting tremor or cogwheel rigidity. The neuropathological report and additional tissue specimens were available for this subject (Table 2).

NEUROPATHOLOGICAL FEATURES

Autopsies were performed on 3 affected individuals in family 1 and 2 affected individuals in family 2. Neuropathological findings are summarized in Table 2. Brain tissue from 1 individual (subject III:9 in family 1) was not available for α-synuclein immunohistochemistry. However, this patient had definite LB pathological features in the SN on H&E staining and was, therefore, classified as positive for LB pathological features. Two patients from each family had postmortem tissue available for additional α-synuclein immunohistochemical studies.

Overall, 2 individuals in family 1 (subjects III:3 and III:9) and 1 in family 2 (subject I:5) had typical LB inclusions in the SN on H&E staining (Table 2 and **Figure 3**A). Two patients with additional tissue available (subject III:3 in family 1 and subject I:5 in family 2) also had LB pathological features detected by α-synuclein immunohistochemistry in the SN and amygdala (Table 2 and Figure 3B and C). One subject from each family (subject III:8 in family 1 and subject I:7 in family 2) did not have SN LBs detected with either H&E or α-synuclein immunostaining. However, both had 6 or more α-synuclein–positive cytoplasmic inclusions in the amygdala (Table 2 and Figure 3D). These latter 2 patients are similar to the amygdala-predominant patients described by other investigators.[22,23,32]

Modified Bielschowsky silver staining for AD pathological features showed that 1 individual from each family (subject III:8 in family 1 and subject I:7 in family 2) had sufficient senile plaque and neurofibrillary tangle pathological features (Braak stage V-C and VI-C, respectively) to meet the neuropathological criteria for high likelihood of AD (per Reagan Institute Working Group on Diagnostic Criteria for the Neuropathological Assessment of Alzheimer's Disease/National Institute on Aging criteria).[33] The remaining 3 patients (subjects III:3 and III:9 in family 1 and subject I:5 in family 2) had moderate to frequent senile plaques in limbic and cortical regions, but only mild to moderate neurofibrillary tangle pathological features that were limited to limbic structures (Braak stage III for all 3). These latter patients would fulfill National Institute on Aging/Reagan Institute Working Group on Diagnostic Criteria for the Neuropathological Assessment of Alzheimer's Disease criteria for intermediate likelihood of AD.

©2002 American Medical Association. All rights reserved.

MOLECULAR GENETICS

Seven individuals in family 1 (6 affected and 1 at risk) and 4 individuals (all affected) in family 2 had DNA available. In family 1, 5 affected individuals carried the *APOE* ϵ3/ϵ4 genotype, while the other affected individual had an *APOE* ϵ4/ϵ4 genotype. One at-risk individual also had the *APOE* ϵ3/ϵ4 genotype (Table 1). In family 2, 3 affected individuals had the *APOE* ϵ4/ϵ4 genotype, while 1 affected individual had the *APOE* ϵ3/ϵ4 genotype (Table 1).

Genetic analyses showed that there were no nucleotide alterations in the α-, β-, or γ-synuclein or parkin genes in 1 affected individual selected from each family. There was no deletion or duplication in the parkin gene in the individuals examined.

COMMENT

To our knowledge, most previously published studies[7,8,34,35] of families with parkinsonism and dementia have included individuals who presented with parkinsonism. Only 2 published reports[8,9] included families with individuals who presented with dementia. However, in one family, only 1 autopsy was reported,[8] while in the other family, none of the individuals who presented with dementia underwent an autopsy.[9] Therefore, we are unable to determine whether affected individuals had clinical and neuropathological DLB.

The present study describes the clinical, neuropathological, and genetic characteristics of persons with dementia in 2 families that included 2 or more autopsy-proven cases of DLB. We found that substantial clinical and neuropathological variability exists within each family. All affected individuals exhibited cognitive decline that either preceded or occurred concurrently with parkinsonism. However, not all affected individuals exhibited hallucinations, delusions, or parkinsonism.

We observed the aggregation of hallucinations and/or delusions in one family, but not in the other. These observations are consistent with previous findings that some families with hereditary neurodegenerative disorders are more susceptible to develop hallucinations and/or delusions than other families with the same disorder. Several reports suggest that some families with Huntington disease,[36,37] frontotemporal dementia,[38] and AD[39,40] have a higher susceptibility to developing hallucinations and/or delusions. Even though visual hallucinations and systematized delusions are part of the clinical criteria for the diagnosis of DLB,[1] to our knowledge, there are no reports that hallucinations and/or delusions are more likely to aggregate in some families with DLB. The present case study provides preliminary evidence that some families with DLB have an increased susceptibility to developing hallucinations and/or delusions.

The mechanisms underlying the development of hallucinations and delusions in patients with dementia are not well understood. One previous study[41] showed no clear LB regional distribution associated with psychosis. Others[42] have suggested that selective loss of different neuronal or neurotransmitter populations may be associated with prominent hallucinations and delusions. Meanwhile, others postulate that differences in genetic background may be associated with the development of hallucinations and delusions. Several reports found an association between a 5-hydroxytryptamine 2A receptor polymorphism,[43,44] dopamine D1 and D3 receptor polymorphisms,[45] a serotonin transporter polymorphism, and psychotic symptoms in patients with AD. Interestingly, a different polymorphism close to the dopamine D2 receptor gene was associated with hallucinations in patients with PD.[46] Additional genetic studies are necessary to confirm these associations.

The *APOE* ϵ4 allele is associated with familial and sporadic late-onset AD[47,48] but not as clearly with PD.[49,50] However, one recent study[51] showed that the *APOE* ϵ4 allele may play a role in dementia associated with PD. The *APOE* ϵ4 allele is associated with an increase in the number of neocortical LBs and amyloid plaques in patients with PD, thus, possibly predisposing to the development of dementia.[52] Investigations[14-16,53,54] of the *APOE* ϵ4 allele as a genetic risk factor for DLB have led to conflicting results. Some investigations[55] have attributed the association between the *APOE* ϵ4 allele and DLB to the presence of concomitant AD pathological features in patients with DLB. However, in a large sample of autopsy-proven cases of DLB without substantial neurofibrillary tangle pathological features, Harrington and colleagues[13] still found that the *APOE* ϵ4 allele frequency was higher (37%) compared with that of normal control subjects (15%). An earlier case report[56] described an *APOE* ϵ4 homozygous individual with widespread cortical and subcortical LB pathological features in the absence of severe neuritic plaque and neurofibrillary tangle pathological features. In the present study, all 10 affected individuals with DNA available carried an *APOE* ϵ4 allele. Our findings support the hypothesis that the *APOE* ϵ4 allele may be an independent risk factor in the development of LB pathological features. However, further delineation of the molecular genetics of families with DLB is necessary.

The discovery of mutations in the α-synuclein gene in familial PD[57] led to the development of highly specific antibodies to this synaptic protein; these antibodies are highly sensitive for detecting LB pathological features in familial and sporadic PD.[58] Investigations[20,59] using α-synuclein antibodies and extranigral sampling (specifically in the amygdala) have found a high frequency of LB pathological features in familial and sporadic AD. These results suggest that the use of α-synuclein immunostaining in brainstem and extrabrainstem regions, along with traditional H&E staining of the SN, is necessary to fully evaluate whether LB pathological features exist.

In our study, the degree of AD pathological features varied within both families, with some individuals having sufficient pathological features for a diagnosis of AD and others having only modest AD-related changes. Although all affected individuals with autopsy results available had LB inclusions, several had classic LBs in the SN and amygdala while others had LB pathological features only in the amygdala. The LB pathological features were detected only with α-synuclein immunostaining in the amygdala. By using less sensitive detection methods, these patients would be classified as not having LB pathological features. Interestingly, these patients with amygdala-predominant LB pathological fea-

©2002 American Medical Association. All rights reserved.

tures had severe AD pathological features. The clinical and pathological significance of these patients with amygdala-predominant DLB remains unclear. Further clinical and neuropathological examinations in patients with familial and sporadic DLB are necessary to investigate the significance of this pattern of LB pathological features.

We identified 2 families who presented with dementia and had evidence of LB pathological features in all affected members with autopsy results. These families may represent examples of familial DLB. Additional clinical, neuropathological, and genetic studies in these and other families are necessary to further clarify the etiology of familial DLB. Studies in families with autopsy-proven DLB can provide important insights into the pathophysiological features of this increasingly recognized disease. In particular, identification of the susceptibility genes in patients with DLB could increase our understanding of the pathophysiological features of this disorder. This knowledge will help to differentiate DLB from AD and PD.

Accepted for publication May 14, 2002.

From the Department of Veterans Affairs Northwest Network Mental Illness Research, Education, and Clinical Center (Drs Tsuang and Leverenz and Ms Eugenio) and the Geriatric Research, Education, and Clinical Center, VA Puget Sound Health Care System (Drs Poorkaj and Bird and Ms Steinbart); the Departments of Psychiatry and Behavioral Sciences (Drs Tsuang and Leverenz), Neurology (Drs La Spada, Bird, and Leverenz and Ms Steinbart), Laboratory Medicine (Drs Limprasert and La Spada), and Internal Medicine (Drs Poorkaj and La Spada), and the School of Medicine (Mr Dalan), University of Washington; and the Parkinson's Disease Research, Education, and Clinical Center (Dr Leverenz), Seattle, Wash.

Author contributions: *Study concept and design* (Drs Tsuang, Bird, and Leverenz and Mr Dalan); *acquisition of data* (Drs Tsuang and Poorkaj, Mr Dalan, and Mss Eugenio and Steinbart); *analysis and interpretation of data* (Drs Tsuang, Poorkaj, Limprasert, and La Spada); *drafting of the manuscript* (Dr Tsuang, Mr Dalan, and Mss Eugenio and Steinbart); *critical revision of the manuscript for important intellectual content* (Drs Tsuang, Poorkaj, Limprasert, La Spada, Bird, and Leverenz); *statistical expertise* (Dr Tsuang); *obtained funding* (Dr Tsuang); *administrative, technical, and material support* (Drs Tsuang, Poorkaj, Limprasert, and Leverenz, Mr Dalan, and Mss Eugenio and Steinbart); *study supervision* (Drs Tsuang, La Spada, Bird, and Leverenz).

This study was supported by a pilot proposal (1999-2000) from the Alzheimer's Disease Research Center, University of Washington; and by Veterans Integrated Service Network 20 from the Veterans Affairs Northwest Network Mental Illness Research, Education, and Clinical Center.

We thank Gerard Schellenberg, PhD, for APOE *genotyping, and Lynne Greenup for technical assistance.*

Corresponding author and reprints: Debby W. Tsuang, MD, MSc, Department of Veterans Affairs Northwest Network Mental Illness Research, Education, and Clinical Center, VA Puget Sound Health Care System, 1660 S Columbian Way, Mailstop 116MIRECC, Seattle, WA 98108 (e-mail: dwt1@u.washington.edu).

REFERENCES

1. McKeith IG, Galasko D, Kosaka K, et al. Consensus guidelines for the clinical and pathologic diagnosis of dementia with Lewy bodies (DLB): report of the Consortium on DLB international workshop. *Neurology.* 1996;47:1113-1124.
2. Galasko D, Salmon D, Thal L. The nosological status of Lewy body dementia. In: Perry R, McKeith I, Perry E, eds. *Dementia With Lewy Bodies.* Cambridge, England: Cambridge University Press; 1996:21-32.
3. Holmes C, Cairns N, Lantos P, Mann A. Validity of current clinical criteria for Alzheimer's disease, vascular dementia and dementia with Lewy bodies. *Br J Psychiatry.* 1999;174:45-50.
4. Lopez OL, Becker JT, Kaufer DI, et al. Research evaluation and prospective diagnosis of dementia with Lewy bodies. *Arch Neurol.* 2002;59:43-46.
5. Hohl U, Tiraboschi P, Hansen LA, Thal LJ, Corey-Bloom J. Diagnostic accuracy of dementia with Lewy bodies. *Arch Neurol.* 2000;57:347-351.
6. Ballard C, Holmes C, McKeith I, et al. Psychiatric morbidity in dementia with Lewy bodies: a prospective clinical and neuropathological comparative study with Alzheimer's disease. *Am J Psychiatry.* 1999;156:1039-1045.
7. Denson M, Wszolek E. Familial parkinsonism: our experience and review. *Parkinsonism Related Disord.* 1995;1:35-46.
8. Denson MA, Wszolek ZK, Pfeiffer RF, Wszolek EK, Paschall TM, McComb RD. Familial parkinsonism, dementia, and Lewy body disease: study of family G. *Ann Neurol.* 1997;42:638-643.
9. Gimenez-Roldan S, Mateo D, Escalona-Zapata J. Familial Alzheimer's disease presenting as levodopa-responsive parkinsonism. *Adv Neurol.* 1987;45:431-436.
10. Ohara K, Takauchi S, Kokai M, Morimura Y, Nakajima T, Morita Y. Familial dementia with Lewy bodies (DLB). *Clin Neuropathol.* 1999;18:232-239.
11. Levy-Lahad E, Tsuang D, Bird TD. Recent advances in the genetics of Alzheimer's disease. *J Geriatr Psychiatry Neurol.* 1998;11:42-54.
12. Payami H, Zareparsi S. Genetic epidemiology of Parkinson's disease. *J Geriatr Psychiatry Neurol.* 1998;11:98-106.
13. Harrington CR, Louwagie J, Rossau R, et al. Influence of apolipoprotein E genotype on senile dementia of the Alzheimer and Lewy body types: significance for etiological theories of Alzheimer's disease. *Am J Pathol.* 1994;145:1472-1484.
14. Galasko D, Saitoh T, Xia Y, et al. The apolipoprotein E allele epsilon 4 is overrepresented in patients with the Lewy body variant of Alzheimer's disease. *Neurology.* 1994;44:1950-1951.
15. Hansen L. The Lewy body variant of Alzheimer's disease. *J Neural Transm.* 1997; 51:83-93.
16. Hardy J, Crook R, Prihar G, Roberts G, Raghavan R, Perry R. Senile dementia of the Lewy body type has an apolipoprotein E $\epsilon 4$ allele frequency intermediate between controls and Alzheimer's disease. *Neurosci Lett.* 1994;182:1-2.
17. Atkinson A, Singleton AB, Steward A, et al. *CYP2D6* is associated with Parkinson's disease but not with dementia with Lewy bodies or Alzheimer's disease. *Pharmacogenetics.* 1999;9:31-35.
18. El-Agnaf OM, Curran MD, Wallace A, et al. Mutation screening in exons 3 and 4 of α-synuclein in sporadic Parkinson's and sporadic and familial dementia with Lewy bodies cases. *Neuroreport.* 1998;9:3925-3927.
19. Silverman JM, Keefe RS, Mohs RC, Davis KL. A study of the reliability of the family history method in genetic studies of Alzheimer disease. *Alzheimer Dis Assoc Disord.* 1989;3:218-223.
20. Lippa CF, Fujiwara H, Mann DM, et al. Lewy bodies contain altered α-synuclein in brains of many familial Alzheimer's disease patients with mutations in presenilin and amyloid precursor protein genes. *Am J Pathol.* 1998;153:1365-1370.
21. Lippa CF, Schmidt ML, Lee VM, Trojanowski JQ. Antibodies to α-synuclein detect Lewy bodies in many Down's syndrome brains with Alzheimer's disease. *Ann Neurol.* 1999;45:353-357.
22. Hamilton RL. Lewy bodies in Alzheimer's disease: a neuropathological review of 145 cases using α-synuclein immunohistochemistry. *Brain Pathol.* 2000;10: 378-384.
23. Dickson D, Corra A, Lin W, et al. Alzheimer's disease (AD) with amygdaloid Lewy bodies (AD/ALB): a form of Lewy body disease distinct from AD and diffuse Lewy body disease (DLBD) [abstract]. *Neurology.* 2000;54:A451.
24. Hixson JE, Vernier DT. Restriction isotyping of human apolipoprotein E by gene amplification and cleavage with *Hha*I. *J Lipid Res.* 1990;31:545-548.
25. Limprasert P, Taylor J, Leverenz J, et al. Beta-synuclein gene alteration in dementia with Lewy bodies (DLB) [abstract]. *Am J Hum Genet.* 2001;69:196.
26. Lavedan C, Leroy E, Torres R, et al. Genomic organization and expression of the human β-synuclein gene (SNCB). *Genomics.* 1998;54:173-175.
27. Lavedan C, Leroy E, Dehejia A, et al. Identification, localization and characterization of the human γ-synuclein gene. *Hum Genet.* 1998;103:106-112.
28. Kitada T, Asakawa S, Hattori N, et al. Mutations in the parkin gene cause autosomal recessive juvenile parkinsonism. *Nature.* 1998;392:605-608.
29. Asakawa S, Tsunematsu K, Takayanagi A, et al. The genomic structure and pro-

©2002 American Medical Association. All rights reserved.

moter region of the human parkin gene. *Biochem Biophys Res Commun.* 2001; 286:863-868.
30. West A, Farrer M, Petrucelli L, Cookson M, Lockhart P, Hardy J. Identification and characterization of the human parkin gene promoter. *J Neurochem.* 2001; 78:1146-1152.
31. Braak H, Braak E. Neuropathological stageing of Alzheimer-related changes. *Acta Neuropathol (Berl).* 1991;82:239-259.
32. McKee A, Boyer P, Wells J, Kowall N. Lewy bodies in the amygdala: a common feature of severe Alzheimer's disease. *J Neuropathol Exp Neurol.* 2000;59:167.
33. Consensus recommendations for the postmortem diagnosis of Alzheimer's disease: the National Institute on Aging, and Reagan Institute Working Group on Diagnostic Criteria for the Neuropathological Assessment of Alzheimer's Disease. *Neurobiol Aging.* 1997;18(suppl):S1-S2.
34. Muenter MD, Forno LS, Hornykiewicz O, et al. Hereditary form of parkinsonism: dementia. *Ann Neurol.* 1998;43:768-781.
35. Golbe LI, Di Iorio G, Bonavita V, Miller DC, Duvoisin RC. A large kindred with autosomal dominant Parkinson's disease. *Ann Neurol.* 1990;27:276-282.
36. Tsuang D, Almqvist EW, Lipe H, et al. Familial aggregation of psychotic symptoms in Huntington's disease. *Am J Psychiatry.* 2000;157:1955-1959.
37. Lovestone S, Hodgson S, Sham P, Differ AM, Levy R. Familial psychiatric presentation of Huntington's disease. *J Med Genet.* 1996;33:128-131.
38. Sumi SM, Bird TD, Nochlin D, Raskind MA. Familial presenile dementia with psychosis associated with cortical neurofibrillary tangles and degeneration of the amygdala. *Neurology.* 1992;42:120-127.
39. Harvey RJ, Ellison D, Hardy J, et al. Chromosome 14 familial Alzheimer's disease: the clinical and neuropathological characteristics of a family with a leucine→serine (L250S) substitution at codon 250 of the presenilin 1 gene. *J Neurol Neurosurg Psychiatry.* 1998;64:44-49.
40. Sweet RA, Nimgaonkar VL, Devlin B, Lopez OL, DeKosky ST. Increased familial risk of the psychotic phenotype of Alzheimer disease. *Neurology.* 2002;58:907-911.
41. Gomez-Tortosa E, Newell K, Irizarry MC, Albert M, Growdon JH, Hyman BT. Clinical and quantitative pathologic correlates of dementia with Lewy bodies. *Neurology.* 1999;53:1284-1291.
42. Forstl H, Burns A, Levy R, Cairns N. Neuropathological correlates of psychotic phenomena in confirmed Alzheimer's disease. *Br J Psychiatry.* 1994;165:53-59.
43. Nacmias B, Tedde A, Forleo P, et al. Association between 5-HT(2A) receptor polymorphism and psychotic symptoms in Alzheimer's disease. *Biol Psychiatry.* 2001; 50:472-475.
44. Holmes C, Arranz MJ, Powell JF, Collier DA, Lovestone S. 5-HT2A and 5-HT2C receptor polymorphisms and psychopathology in late onset Alzheimer's disease. *Hum Mol Genet.* 1998;7:1507-1509.
45. Holmes C, Smith H, Ganderton R, et al. Psychosis and aggression in Alzheimer's disease: the effect of dopamine receptor gene variation. *J Neurol Neurosurg Psychiatry.* 2001;71:777-779.
46. Makoff AJ, Graham JM, Arranz MJ, et al. Association study of dopamine receptor gene polymorphisms with drug-induced hallucinations in patients with idiopathic Parkinson's disease. *Pharmacogenetics.* 2000;10:43-48.
47. Corder EH, Saunders AM, Risch NJ, et al. Protective effect of apolipoprotein E type 2 allele for late onset Alzheimer disease. *Nat Genet.* 1994;7:180-184.
48. Saunders AM, Strittmatter WJ, Schmechel D, et al. Association of apolipoprotein E allele ϵ4 with late-onset familial and sporadic Alzheimer's disease. *Neurology.* 1993;43:1467-1472.
49. Egensperger R, Bancher C, Kosel S, Jellinger K, Mehraein P, Graeber MB. The apolipoprotein E ϵ4 allele in Parkinson's disease with Alzheimer lesions. *Biochem Biophys Res Commun.* 1996;224:484-486.
50. Maraganore DM, Farrer MJ, Hardy JA, McDonnell SK, Schaid DJ, Rocca WA. Case-control study of debrisoquine 4-hydroxylase, *N*-acetyltransferase 2, and apolipoprotein E gene polymorphisms in Parkinson's disease. *Mov Disord.* 2000;15: 714-719.
51. Parsian A, Racette B, Goldsmith LJ, Perlmutter JS. Parkinson's disease and apolipoprotein E: possible association with dementia but not age at onset. *Genomics.* 2002;79:458-461.
52. Wakabayashi K, Kakita A, Hayashi S, et al. Apolipoprotein E ϵ4 allele and progression of cortical Lewy body pathology in Parkinson's disease. *Acta Neuropathol (Berl).* 1998;95:450-454.
53. St Clair D. Apolipoprotein E gene in Parkinson's disease, Lewy body dementia and Alzheimer's disease. *J Neural Transm Suppl.* 1997;51:161-165.
54. Arai H, Higuchi S, Muramatsu T, Iwatsubo T, Sasaki H, Trojanowski JQ. Apolipoprotein E gene in diffuse Lewy body disease with or without co-existing Alzheimer's disease. *Lancet.* 1994;344:1307.
55. Olichney JM, Hansen LA, Galasko D, et al. The apolipoprotein E ϵ4 allele is associated with increased neuritic plaques and cerebral amyloid angiopathy in Alzheimer's disease and Lewy body variant. *Neurology.* 1996;47:190-196.
56. Seltzer B, Fratkin J, Clejan S. Diffuse Lewy body disease without amyloid plaques in a patient homozygous for apolipoprotein E allele epsilon 4: a case report. *J Geriatr Psychiatry Neurol.* 1996;9:181-184.
57. Polymeropoulos MH, Lavedan C, Leroy E, et al. Mutation in the α-synuclein gene identified in families with Parkinson's disease. *Science.* 1997;276:2045-2047.
58. Spillantini MG, Schmidt ML, Lee VM, Trojanowski JQ, Jakes R, Goedert M. α-Synuclein in Lewy bodies. *Nature.* 1997;388:839-840.
59. Fishel M, Tsuang D, Raskind M, et al. Lewy body pathology in familial (presenilin-2) Alzheimer's disease. *Neurobiol Aging.* 2000;21(suppl):S66.

©2002 American Medical Association. All rights reserved.