

# **Primary Diffuse Large B-cell Lymphoma of Bone**



# **Primary Diffuse Large B-cell Lymphoma of Bone**

## **Proefschrift**

ter verkrijging van de graad van Doctor aan de Universiteit Leiden,  
op gezag van Rector Magnificus prof. mr. P.F. van der Heijden,  
volgens besluit van het College voor Promoties  
te verdedigen op donderdag 1 december 2011  
klokke 15.00 uur

door

**Fenna Henriette Heyning**

geboren te Leiden in 1970

Promotiecommissie:

Promotor: Prof. dr. P.C.W. Hogendoorn

Copromotor: dr. P.M. Jansen

Overige leden: Prof. dr. J.H. Veelken  
dr. K. Szuhai  
Prof. dr. A.H.M. Taminiau  
Prof. dr. Ph.M. Kluin (Universiteit Groningen)  
Prof. dr. M.H.H. Kramer (Vrije Universiteit Amsterdam)

*"I have never let my schooling interfere with my education"*

*Mark Twain, 1835-1910*

*Aan mijn familie*

ISBN 978-94-90588-00-7

© 2011 Fenna Heyning

Manuscript layout: Digit@l Xpression, Bennekom, The Netherlands

Cover layout: Digit@l Xpression, Bennekom, The Netherlands

Printed by: GVO drukkers & vormgevers BV | Ponsen & Looijen, Ede,  
The Netherlands

Publication of this thesis was financially supported by Medisch Centrum Haaglanden, Novartis  
Oncology, Celgene, Roche.

## Contents


<b>Chapter 1</b>	Introduction	1
<b>Chapter 2</b>	Primary non-Hodgkin's lymphoma of bone, a clinicopathological investigation of 60 cases. <i>Leukemia, 1999; 13: 2094-8.</i>	15
<b>Chapter 3</b>	MR imaging characteristics in primary lymphoma of bone with emphasis on non-aggressive appearance. <i>Skeletal Radiology, 2007; 937-944.</i>	29
<b>Chapter 4</b>	Primary lymphoma of bone: extranodal lymphoma with favourable survival independent of germinal centre, post-germinal centre or indeterminate phenotype. <i>J.Clin. Pathol, 2009; 62: 820-824.</i>	43
<b>Chapter 5</b>	Array-based comparative genomic hybridization analysis reveals recurrent chromosomal alterations in primary diffuse large B-cell lymphoma of bone. <i>J. Clin Pathol, 2010; 63: 1095-1100.</i>	55
<b>Chapter 6</b>	Nuclear factor- $\kappa$ B activation in primary lymphoma of bone <i>Submitted for publication.</i>	69
<b>Chapter 7</b>	Summary, general discussion and future perspectives	81
	Nederlandse Samenvatting	87
	Curriculum Vitae	93
	Acknowledgements	97





# Chapter 1

## General introduction





## History

Primary lymphoma of bone is a rare disease, first described by Oberling in 1928 as reticulum cell sarcoma of bone.<sup>1</sup> He accomplished a reliable and consistent separation of reticulum cell sarcoma of bone from Ewing's sarcoma, a histomorphological mimic. Reticulin fibers surrounding individual tumor cells are a characteristic finding in primary lymphoma of bone, hence the original terminology of reticulum cell sarcoma. It was not until 1939 that Parker and Jackson described 17 cases of so-called 'primary reticulum cell sarcoma of bone' and established this disease as a distinct and accepted clinical entity.<sup>2</sup> In 1963 Ivins and later in 1974 Boston et al. recognized the lymphoid origin of the tumor and named it malignant lymphoma of bone.<sup>3,4</sup> In 1987 Vassallo introduced the use of immunohistochemistry to characterize the true cellular origin of these tumors.<sup>5</sup> Even today the histopathological diagnosis of primary lymphoma of bone can be challenging, it is often only with the help of lymphoma cell specific immunohistochemical markers that difficult cases can be diagnosed in a reliable manner. The subtype of lymphoma that is most often diagnosed in these cases is diffuse large B cell lymphoma. In this thesis we focus on primary diffuse large B cell lymphoma of bone. Other subtypes, such as primary follicular lymphoma of bone, primary Hodgkin lymphoma of bone, primary T cell lymphoma of bone or acute anaplastic large cell lymphoma in children do occur on rare occasions, but these subtypes were excluded in our studies.

Since 1974, when Boston gave primary lymphoma of bone its current name, multiple different systems of classification of non-Hodgkin lymphoma have been used. This has complicated research, as consensus on definitions and terminology is essential for both clinical practice and investigation. Poor reproducibility of morphologic criteria have helped to switch from the Kiel and Lukes-Collins classification via the Working Formulation system in 1982 to the REAL classification in 1994. From the REAL classification, in 2001 the World Health Organization (WHO) classification system was established. This classification system is used internationally nowadays. The diagnosis and classification of non-Hodgkin lymphoma has moved from a purely morphologically driven classification system then, into one in which a wide range of information, including immunophenotype and molecular genetic features, are part of the disease definitions today. In the WHO classification, primary diffuse large B cell lymphoma of bone is defined as a mono-ostotic disease with or without involvement of regional lymph nodes, or as a poly-ostotic disease affecting multiple skeletal sites without visceral- or lymph node involvement.<sup>6</sup> The percentage of primary diffuse large B cell lymphoma of bone is only 5% of all extranodal non-Hodgkin lymphomas and is less than 1% of all non-Hodgkin lymphomas.<sup>6-8</sup> As a consequence of this low incidence, scientific studies on this subject are uncommon.

In 1953, the Netherlands Committee on Bone Tumors was founded in Leiden. This Commission keeps a large national registry of bone tumors in the Netherlands containing more than 25.000 cases, including clinical data at presentation, histological slides of the tumor and complete radiographic documentation. This registry gave us the unique opportunity to assemble a large cohort of patients with primary diffuse large B cell lymphoma of bone, one of the largest

worldwide. Starting with this cohort, we initiated our research project on primary diffuse large B cell lymphoma of bone to increase the knowledge of this rare and poorly understood subtype of non-Hodgkin lymphoma.

## **Clinico-pathological characteristics**

Primary diffuse large B cell lymphoma of bone often presents with pain or a palpable mass, most frequently in the long bones, especially the distal femur or the distal humerus. The median age at presentation is in the fifth decade, with male patients affected more often than female patients with a ratio of 1.8 : 1. Morphologically, almost all tumors are composed of large centroblast-like cells, often with multilobated nuclear features, but accurate morphological subclassification can be problematic due to mechanical crush, decalcification procedures or small sample size.<sup>8,9</sup> In many cases the pathologic features of the tumor, often including intralesional fibrosis and prominent tumor cell spindling, make the histopathologic diagnosis even more complicated. In inexperienced hands misdiagnoses do occur, often classifying the tumor as a primary bone sarcoma.

Since 1971, the Ann Arbor system is used internationally for the staging of all Hodgkin and non-Hodgkin lymphomas (see table 1).<sup>10</sup> Although originally developed for staging patients with Hodgkin lymphoma, the Ann Arbor staging system provides the basis for anatomic staging in non-Hodgkin lymphomas as well. However, in non-Hodgkin lymphoma the Ann Arbor staging system has less prognostic value than in Hodgkin lymphoma.<sup>11</sup> The Ann Arbor staging system was not designed to take into account the different pattern of disease seen in the non-Hodgkin lymphomas, for example the often extranodal presentation.<sup>12</sup> It neither takes into account the grade of the tumor, which is prognostically relevant in non-Hodgkin lymphoma. Primary diffuse large B cell lymphoma of bone most often presents at one bone localization, which is classified as stage I. The stages II and III are rarely applicable in primary diffuse large B cell lymphoma of bone. In our studies, all stage IV cases had multiple bone localizations, none had bone marrow involvement. To avoid these staging problems for extranodal lymphoma, several authors choose to include only stage I patients in their bone lymphoma studies, which may lead to an imperfect representation of patients in literature.

Historically, a wide variety of therapies for primary diffuse large B cell lymphoma of bone has been used, including radiotherapy, surgery (amputation) and chemotherapy. For about twenty-five years most primary diffuse large B cell lymphoma of bone patients have been treated with a combination of radiotherapy and CHOP or CHOP-like chemotherapy. Probably the most important improvement for lymphoma patients in the last decade has been the addition of rituximab, a monoclonal antibody that specifically targets the CD20 positive B-cell, to the standard multiagent therapy regimen.<sup>13</sup> However, data on primary diffuse large B cell lymphoma of bone patients treated with this regimen are still scarce.<sup>14</sup> The five-year overall survival rate for primary diffuse large B cell lymphoma of bone is generally favorable compared to other intermediate grade, extranodal diffuse large B cell lymphoma, with a 5-years overall survival of 75% for the whole cohort in our studies

**Table 1.** Ann Arbor Staging Classification.

---

Stage I:	Involvement of a single lymph node region (I) or of a single extralymphatic organ or site. (IE)
Stage II:	Involvement of two or more lymph node regions on the same side of the diaphragm (II) or localized involvement of an extralymphatic organ or site and one or more lymph node regions on the same side of the diaphragm. (IIE)
Stage III:	Involvement of lymph node regions on both sides of the diaphragm (III), which may be accompanied by involvement of the spleen (IIIS) or by localized involvement of an extralymphatic organ or site (IIIE), or both. (IIISE)
Stage IV:	Diffuse or disseminated involvement of one or more extralymphatic organs or tissues with or without associated lymph node involvement.

The absence or presence of fever, night sweats, or unexplained loss of 10% or more of body weight in the 6 months preceding admission are to be denoted in all cases by the suffix letters A or B, respectively.

---

(see table 2).<sup>9, 15 16-18</sup> Despite the improvement in diffuse large B cell lymphoma treatment with the addition of rituximab to CHOP, one quarter to one third of patients still die of their disease. The development of novel treatment regimens such as new anti-CD20 antibodies, proteasome inhibitors or lenalidomide are promising, but will require further study.<sup>19-21</sup>

## Risk stratification in diffuse large B cell lymphoma

Diffuse large B cell lymphoma, including its extranodal subtype primary diffuse large B cell lymphoma of bone, represents a heterogeneous group of B-cell neoplasms, both clinically and morphologically. Paradoxically, the chemotherapy treatment regime for all of these patients is almost always the same: CHOP or CHOP-like chemotherapy, since 2001 in combination with rituximab. Strategies to intensify chemotherapy regimes, including autologous stem cell transplantation, have showed mixed results.<sup>22, 23</sup> Intensive chemotherapy plus autologous stem cell transplantation might be beneficial for a selected group of high risk young patients, but which subgroup will benefit the most is unclear. Clinicians have difficulties defining the optimal treatment regimen for their diffuse large B cell lymphoma patients, because it is impossible to accurately predict response to standard treatment regimens. Patients present with apparently similar diagnoses, but have markedly different clinical outcomes, with a five year overall survival ranging from about 20% to 80% (see table 2). To identify patients who will show progressive disease despite standard chemotherapy and who will benefit from more intensive or different treatment modalities, numerous studies have been undertaken to design risk stratifications and to define meaningful prognostic markers.

### Clinical prognostic factors:

For risk stratification purposes lymphomas are traditionally divided into a group with primary tumor location in the lymph nodes and a group with primary extranodal presentation, which can occur at any site. It has long been held that overall survival for extranodal lymphomas as

a whole compares unfavorably with survival for nodal cases. Diffuse large B cell lymphoma of the testis and central nervous system for example - both lymphomas of immune-privileged sites - have been reported to have an unfavorable survival, with a 5-year overall survival below 50 %. In recent years, the survival of patients with lymphoma of immune-privileged sites has much improved, probably due to better diagnostic procedures and more tailored chemotherapy, including rituximab.<sup>24-26</sup> Primary diffuse large B cell lymphoma of bone has shown a much better survival, even in studies from more than ten years ago. It is therefore questionable whether this distinction between nodal lymphoma and extranodal lymphoma still holds its clinical relevance<sup>27, 28 29, 30</sup> (**see table 2**).

The recognition that the Ann Arbor anatomical staging system does not subdivide some types of non-Hodgkin lymphomas in a clinically useful way, and the recognition that other factors are important in predicting treatment outcome, has led to the development of the International Prognostic Index (IPI) in 1993. The IPI is based on a limited set of clinical and laboratory variables, which makes it a useful and affordable index in daily practice (**see table 3**).<sup>43 44</sup> Since one parameter of the index is the number of extranodal sites and another parameter is the Ann Arbor stage, this index is not directly intended for indexing primary extranodal lymphomas. However, some studies indicate that the IPI is nonetheless applicable for staging primary extranodal lymphomas.<sup>45</sup>

### **Molecular genetic prognostic factors:**

In the last decade, several molecular techniques, e.g. using DNA and RNA derived from tumor cells, have been developed to study the pathogenesis of diffuse large B cell lymphoma in more detail. However, it is important to realize that most studies using these new techniques concern nodal diffuse large B cell lymphoma, as those tissue samples are more abundantly available than tissue samples from extranodal lymphomas. Moreover, in contrast to extranodal lymphomas, cell lines of nodal diffuse large B-cell lymphoma are generally available, allowing for functional testing. These new techniques are also increasingly being used in extranodal lymphomas and future studies will be necessary to investigate to what extent the results of nodal diffuse large B-cell lymphoma can be extrapolated to extranodal lymphoma.

**Table 2.** Overall 5 years survival (OS) in diffuse large B cell lymphoma

Primary location	Reference	5 year OS %
nodal	Sehn <sup>32</sup> , Gutierrez <sup>33</sup>	69-70
nodal (elderly patients)	Feugier <sup>34</sup> , Coiffier <sup>35</sup>	58-60
testis	Al-Abbadi <sup>36</sup> , Vitolo <sup>25</sup> , Mazloom <sup>26</sup>	60-86
central nervous system	Shenkier <sup>37</sup> , Hattab <sup>38</sup> , Yamanaka <sup>39</sup> , Gavrilovic <sup>27</sup>	18-46
bone	Heyning <sup>10</sup> , Beal <sup>18</sup> , Ramadan <sup>19</sup>	62-88
stomach	Leopardo <sup>40</sup> , Hung <sup>41</sup> , Zhang <sup>42</sup>	50-100
skin (primary cutaneous large B-cell lymphoma, leg type)	Dijkman <sup>28</sup> , Grange <sup>43</sup>	25-41

**Table 3.** International Prognostic Index

One point is assigned for each of the following risk factors:

- Age greater than 60 years
- Stage III or IV disease
- Elevated serum LDH
- WHO performance status of 2 or more
- More than 1 extranodal site

The sum of the points allotted correlates with a median three-year survival ranging from 91% to 59%.

Gene expression profiling can divide diffuse large B cell lymphoma into two histological indistinguishable molecular subtypes: a prognostically favorable group of germinal center B-cell (GCB) phenotype and a prognostically unfavorable group of activated B-cell (ABC or non-GC) phenotype.<sup>46</sup> The GCB subtype has a significantly better outcome, 80% five year overall survival versus 45% five year overall survival for the ABC subtype, independent from IPI classification.<sup>47, 48</sup> These two subtypes apparently arise from B-cells that are at separate stages of differentiation. Each subtype has a different process of malignant transformation and acquires distinct oncogenic abnormalities. In GCB phenotype lymphoma the germinal center B cells of the malignant clone continue to undergo somatic hypermutation. They avoid cell death by oncogenic translocations such as the t(14;18) translocation or TP53 mutations.<sup>49</sup> Anti-apoptotic pathways are activated by the overexpression of bcl-2 as a result of a t(14;18) resulting in a fusion of IgH promoter to BCL-2. However, the presence of this specific translocation does not have an inverse impact on prognosis.<sup>50, 51</sup> Secondary changes, such as TP53 mutations may occur in a subset of these patients. The overall survival is significantly worse for patients with TP53 mutations than for patients with wild type TP53 in GCB-type diffuse large B-cell lymphoma.<sup>49, 52</sup>

Few studies exist on BCL-2 gene rearrangement in primary diffuse large B cell lymphoma of bone. Gianelli et al. found BCL-2/IgH rearrangement in 5% of cases, Bhagavathi in 4 of 21 cases.<sup>53, 54</sup> No prognostic effect could be detected in these small cohorts (**see table 4**).

As germinal-center B cells begin to differentiate into plasma cells, they upregulate interferon regulatory factor 4 (IRF4). This is the stage of differentiation where the malignant clone of ABC-type diffuse large B-cell lymphoma likely arises. The ABC subtype often carries a

**Table 4.** Gene rearrangements in primary diffuse large B cell lymphoma of bone patients

Gene(s)	Reference	Technique	Rearrangements
IgH	Bhagavathi <sup>55</sup>	PCR	10/17
IgH/BCL-2	Bhagavathi, Gianelli <sup>54</sup>	PCR	4/17, 2/41
	Bhagavathi	FISH	4/21
BCL-2	Lima <sup>56</sup>	FISH	9/32
BCL-6	Bhagavathi	FISH	3/21
C-MYC	Bhagavathi, Lima	FISH	2/21, 3/32

homozygous deletion of the CDKN2A (INK4A-ARF) locus, which encodes p16, an inhibitor of senescence and p14-ARF, an inhibitor of p53 activation.<sup>49, 56</sup> This deletion has a negative impact on prognosis.<sup>57</sup>

While in GCB type diffuse large B-cell lymphoma, BCL-2 is commonly deregulated by translocations, alternative mechanisms of BCL-2 up-regulation, such as gain or amplification of 18q21, are more frequently seen in the ABC subgroup. BCL-2 is a target gene for nuclear factor (NF)- $\kappa$ B, and in ABC type diffuse large cell B cell lymphoma, BCL-2 up-regulation may be mediated through the NF- $\kappa$ B pathway. In the ABC subgroup, bcl-2 expression is associated with poor survival.<sup>58</sup> BCL-2 may act as an anti-apoptotic factor in this subgroup, but it may also serve as a marker for events that are responsible for poor prognosis, such as NF- $\kappa$ B activation.<sup>59, 60</sup>

The NF- $\kappa$ B comprises a family of transcription factors that control genes implicated in B-cell activation, proliferation and resistance to apoptosis. The NF- $\kappa$ B family has five members: p65 (RelA), p50 (NF- $\kappa$ B1), p52 (NF- $\kappa$ B2), RelB and REL. Two signaling pathways account for the activation of NF- $\kappa$ B. The classical pathway activation is normally triggered in response to inflammatory stimuli. Signal transduction events lead to activation of the I $\kappa$ B kinase (IKK) complex resulting in phosphorylation and proteasomal degradation of I $\kappa$ B. Heterodimers and homodimers of p50 and p65 can then be translocated to the nucleus to regulate gene transcription. The alternative pathway is triggered, amongst others, by certain members of the tumor-necrosis factor (TNF) cytokine family, eventually leading to processing of the p52 precursor subunit into active p52 translocating to the nucleus and forming a heterodimeric complex with RelB.<sup>61</sup> Constitutive activation of NF- $\kappa$ B has been implicated to play a role in the pathogenesis of different types of haematological malignancies.<sup>62, 63</sup> It seems generally involved in ABC type diffuse large B cell lymphoma and is required for survival of ABC type diffuse large B cell lymphoma cells *in vitro*.<sup>64</sup> The role of constitutive NF- $\kappa$ B pathway activation in lymphomagenesis has raised interest in its potential as a target for therapeutic interventions,<sup>65 66 61</sup> specifically in ABC-type diffuse large B-cell lymphoma, as inhibition of the NF- $\kappa$ B pathway *in vitro* was shown to be selectively toxic to ABC type diffuse large B cell lymphoma cell lines and not to GCB type cell lines.<sup>64</sup>

Recent studies, including ours, have focused on the use of immunohistochemistry to identify risk groups. In 2004 Hans et al. developed an algorithm applying immunohistochemical parameters, the expression of CD10, BCL-6 and MUM1/IRF4, to define the two prognostic groups of germinal center B cell phenotype and activated B-cell phenotype of nodal diffuse large B-cell lymphoma, thus avoiding the limitations of fresh tissue and costly technology of gene expression profiling.<sup>67</sup> BCL-6 and CD10 proteins are considered germinal center (GC) markers, and MUM1/IRF4 denotes the final step of intra-GC B-cell differentiation and activation. More recently, a consortium of hematopathologists improved on the Hans method by employing a different combination of immunostains, i.e. GCET1, CD10, BCL-6, MUM1/IRF4 and FOXP1 and derived a new algorithm with 93% concordance with gene expression profiling.<sup>68</sup>



## Concluding remarks

It is clear that diffuse large B cell lymphoma is a heterogeneous disease group. Even within the group of extranodal diffuse large B cell lymphoma, clinical outcome between the specific sites is quite variable. The scientific development in diffuse large B cell lymphoma research during the course of our project illustrates the ongoing evolution in risk stratification for lymphomas. The prognostic impact of grouping activated B cell type versus germinal center B-cell type diffuse large B-cell lymphoma has been described extensively in literature now, with usually a poorer prognosis for the ABC subtype. However, clinical evidence in the form of a large, prospective trial is still lacking. The knowledge on the role of BCL-2 up-regulation and its influence on prognosis depending on the lymphoma phenotype is increasing. Constitutive NF- $\kappa$ B pathway activation plays a major role in lymphomagenesis, but the exact mechanisms are still poorly understood. Moreover, many of the techniques necessary for subtyping diffuse large B cell lymphoma according to the various risk stratification models, such as cDNA microarray and array-comparative genomic hybridization (array-CGH), are not available in routine patient care yet. It is also still unclear whether pathogenetic models discovered in nodal diffuse large B-cell lymphoma are applicable to the different extranodal lymphoma subtypes, such as primary diffuse large B cell lymphoma of bone. The expanding knowledge on lymphoma-associated biologic processes can help identify targets for the development of new therapeutic agents. At this moment, however, the novel treatment regimes are still experimental. The progress in risk stratification has not yet changed the standard R-CHOP treatment regimen for the individual patient.

With this thesis, we hope to define the entity of primary diffuse large B cell lymphoma of bone more clearly by increasing the understanding of this very specific and rare subtype of diffuse large B cell lymphoma. Ultimately, ongoing lymphoma research will provide insights that lead to an improved, tailored treatment regimen for all diffuse large B cell lymphoma patients.

## Scope and outline of the thesis

This thesis focuses on the clinico-pathological aspects of primary diffuse large B cell lymphoma of bone, a rare subtype of extranodal diffuse large B cell lymphoma. Improved insight of the pathophysiology of this bone tumor can be employed to acquire a better understanding of the wide range of different diseases grouped together under the name of diffuse large B cell lymphoma.

In **chapter two**, we investigated the clinical course of a large cohort of 60 primary diffuse large B cell lymphoma of bone patients, which we selected from the files of the Netherlands Committee on Bone Tumors. We completed follow-up data until time of death or date of last follow-up. At the time of our research, no uniform directives for classification, treatment and prognosis were available yet. The objective of the study was to document patient and tumor characteristics of this cohort, with emphasis on histological subtype, substantiated by

immunohistochemistry, and to define factors affecting prognosis, including the parameters of the IPI risk index.

In **chapter three**, we studied the MRI characteristics of 29 primary diffuse large B cell lymphoma of bone patients. Literature on the presentation of MR imaging features of primary diffuse large B cell lymphoma of bone is relatively scarce and contradictory. There is an ongoing debate as to whether there is a uniform imaging pattern in primary lymphoma of bone. We aimed to assess the imaging characteristics of primary lymphoma of bone and to assess the rate of a non-aggressive MR imaging appearance, by evaluating various features known from literature, with emphasis on cortical bone manifestation and marrow and soft-tissue signal characteristics.

In **chapter four**, we studied multiple immunohistochemical markers and their possible prognostic influence in primary diffuse large B cell lymphoma of bone. Immunohistochemical studies on primary diffuse large B cell lymphoma of bone are rare, probably because of the limited availability of tissue specimens of this disorder and technological difficulties in handling osseous tumor material. In nodal diffuse large B-cell lymphoma, individual markers have been shown to have a prognostic influence on survival. We determined the prognostic significance of BCL-6, CD10, MUM1, BCL-2, p53, CD30 and CD44. With the help of these markers we investigated the possible germinal center derivation in primary diffuse large B cell lymphoma of bone.

In **chapter five**, we described the first array-CGH study of primary diffuse large B cell lymphoma of bone. Recent studies report that this technique can be used to classify lymphomas into the clinically and biologically relevant phenotypes: GC-like and ABC/non-GC-like, and possibly this technique can reveal differences in oncogenic mechanisms. We investigated genomic alterations in 9 cases of primary diffuse large B cell lymphoma of bone using this technique and analysed the results in the context of data available from literature on studies of other distinct subtypes of extranodal diffuse large B cell lymphoma such as skin, central nervous system and testis.

In **chapter six**, we described the first study on the nuclear factor (NF)- $\kappa$ B signaling pathway in primary diffuse large B cell lymphoma of bone. The NF- $\kappa$ B comprises a family of transcription factors that control genes implicated in B-cell activation and proliferation. Constitutive activation of this pathway can contribute to tumorigenesis and chemotherapy resistance and is shown to be involved in tumor cell survival in several types of lymphomas, including nodal diffuse large B cell lymphoma. Two major pathways account for the activation of NF- $\kappa$ B, the classical pathway and the alternative pathway. We investigated both pathways of NF- $\kappa$ B activation by immunohistochemistry and evaluated its clinical parameters in a large cohort of 50 primary diffuse large B cell lymphoma of bone patients.

Finally the findings are summarized in **chapter seven**.

## Reference List

1. Oberling C. Les réticulosarcomes et les réticulo-endothéliosarcomes de la moelle osseuse (sarcomes d'Ewing). *Bull Assoc Fr Etud Cancer* 1928;17(5):259-296.
2. Parker F, Jr., Jackson H, Jr. Primary reticulum cell sarcoma of bone. *Surg Gynecol Obstet* 1939;68:45-53.
3. Boston HC, Jr., Dahlin DC, Ivins JC, Cupps RE. Malignant lymphoma (so-called reticulum cell sarcoma) of bone. *Cancer* 1974;34(4):1131-1137.
4. Ivins JC, Dahlin DC. Malignant Lymphoma (Reticulum Cell Sarcoma) of Bone. *Mayo Clinic Proceedings* 1963;38(18):375-&.
5. Vassallo J, Roessner A, Vollmer E, Grundmann E. Malignant lymphomas with primary bone manifestation. *Pathol Res Pract* 1987;182(3):381-389.
6. k.k.Unni, P.C.W.Hogendoorn. World health organization classification of tumours.pathology and genetics of tumours of soft tissue and bone. Lyon: IARC Press . 2002.
7. Desai S, Jambhekar NA, Soman CS, Advani SH. Primary lymphoma of bone: a clinicopathologic study of 25 cases reported over 10 years. *J Surg Oncol* 1991;46(4):265-269.
8. de Leval L, Braaten KM, Ancukiewicz M et al. Diffuse large B-cell lymphoma of bone: an analysis of differentiation-associated antigens with clinical correlation. *Am J Surg Pathol* 2003;27(9):1269-1277.
9. Heyning FH, Hogendoorn PC, Kramer MH et al. Primary non-Hodgkin's lymphoma of bone: a clinicopathological investigation of 60 cases. *Leukemia* 1999;13(12):2094-2098.
10. Carbone PP, Kaplan HS, Musshoff K, Smithers DW, Tubiana M. Report of the Committee on Hodgkin's Disease Staging Classification. *Cancer Res* 1971;31(11):1860-1861.
11. Rosenberg SA. Validity of the Ann Arbor staging classification for the non-Hodgkin's lymphomas. *Cancer Treat Rep* 1977;61(6):1023-1027.
12. Armitage JO. Staging non-Hodgkin lymphoma. *CA Cancer J Clin* 2005;55(6):368-376.
13. Vose JM, Link BK, Grossbard ML et al. Phase II study of rituximab in combination with chop chemotherapy in patients with previously untreated, aggressive non-Hodgkin's lymphoma. *J Clin Oncol* 2001;19(2):389-397.
14. Pellegrini C, Gandolfi L, Quirini F et al. Primary bone lymphoma: evaluation of chemoimmunotherapy as front-line treatment in 21 patients. *Clin Lymphoma Myeloma Leuk* 2011;11(4):321-325.
15. Alencar A, Pitcher D, Byrne G, Lossos IS. Primary bone lymphoma--the University of Miami experience. *Leuk Lymphoma* 2010;51(1):39-49.
16. Adams H, Tzankov A, d'Hondt S, Jundt G, Dirnhofer S, Went P. Primary diffuse large B-cell lymphomas of the bone: prognostic relevance of protein expression and clinical factors. *Hum Pathol* 2008;39(9):1323-1330.
17. Beal K, Allen L, Yahalom J. Primary bone lymphoma: treatment results and prognostic factors with long-term follow-up of 82 patients. *Cancer* 2006;106(12):2652-2656.
18. Ramadan KM, Shenkier T, Sehn LH, Gascoyne RD, Connors JM. A clinicopathological retrospective study of 131 patients with primary bone lymphoma: a population-based study of successively treated cohorts from the British Columbia Cancer Agency. *Ann Oncol* 2007;18(1):129-135.
19. Morschhauser F, Leonard JP, Fayad L et al. Humanized anti-CD20 antibody, veltuzumab, in refractory/recurrent non-Hodgkin's lymphoma: phase I/II results. *J Clin Oncol* 2009;27(20):3346-3353.
20. Dunleavy K, Pittaluga S, Czuczman MS et al. Differential efficacy of bortezomib plus chemotherapy within molecular subtypes of diffuse large B-cell lymphoma. *Blood* 2009;113(24):6069-6076.
21. Wiernik PH, Lossos IS, Tuscano JM et al. Lenalidomide monotherapy in relapsed or refractory aggressive non-Hodgkin's lymphoma. *J Clin Oncol* 2008;26(30):4952-4957.
22. Martelli M, Gherlinzoni F, De RA et al. Early autologous stem-cell transplantation versus conventio-

- nal chemotherapy as front-line therapy in high-risk, aggressive non-Hodgkin's lymphoma: an Italian multicenter randomized trial. *J Clin Oncol* 2003;21(7):1255-1262.
23. Intragumtornchai T, Bunworasate U, Nakorn TN, Rojnuckarin P. Rituximab-CHOP-ESHAP vs CHOP-ESHAP-high-dose therapy vs conventional CHOP chemotherapy in high-intermediate and high-risk aggressive non-Hodgkin's lymphoma. *Leuk Lymphoma* 2006;47(7):1306-1314.
  24. Vitolo U, Chiappella A, Ferreri AJ et al. First-line treatment for primary testicular diffuse large B-cell lymphoma with rituximab-CHOP, CNS prophylaxis, and contralateral testis irradiation: final results of an international phase II trial. *J Clin Oncol* 2011;29(20):2766-2772.
  25. Mazloom A, Fowler N, Medeiros LJ, Iyengar P, Horace P, Dabaja BS. Outcome of patients with diffuse large B-cell lymphoma of the testis by era of treatment: the M. D. Anderson Cancer Center experience. *Leuk Lymphoma* 2010;51(7):1217-1224.
  26. Gavrilovic IT, Hormigo A, Yahalom J, DeAngelis LM, Abrey LE. Long-term follow-up of high-dose methotrexate-based therapy with and without whole brain irradiation for newly diagnosed primary CNS lymphoma. *J Clin Oncol* 2006;24(28):4570-4574.
  27. Dijkman R, Tensen CP, Jordanova ES et al. Array-based comparative genomic hybridization analysis reveals recurrent chromosomal alterations and prognostic parameters in primary cutaneous large B-cell lymphoma. *J Clin Oncol* 2006;24(2):296-305.
  28. Booman M, Szuhai K, Rosenwald A et al. Genomic alterations and gene expression in primary diffuse large B-cell lymphomas of immune-privileged sites: the importance of apoptosis and immunomodulatory pathways. *J Pathol* 2008;216(2):209-217.
  29. Zucca E, Roggero E, Bertoni F, Conconi A, Cavalli F. Primary extranodal non-Hodgkin's lymphomas. Part 2: Head and neck, central nervous system and other less common sites. *Ann Oncol* 1999;10(9):1023-1033.
  30. Zucca E, Roggero E, Bertoni F, Cavalli F. Primary extranodal non-Hodgkin's lymphomas. Part 1: Gastrointestinal, cutaneous and genitourinary lymphomas. *Ann Oncol* 1997;8(8):727-737.
  31. Sehn LH, Berry B, Chhanabhai M et al. The revised International Prognostic Index (R-IPI) is a better predictor of outcome than the standard IPI for patients with diffuse large B-cell lymphoma treated with R-CHOP. *Blood* 2007;109(5):1857-1861.
  32. Gutierrez-Garcia G, Colomo L, Villamor N et al. Clinico-biological characterization and outcome of primary nodal and extranodal diffuse large B-cell lymphoma in the rituximab era. *Leuk Lymphoma* 2010;51(7):1225-1232.
  33. Feugier P, Van HA, Sebban C et al. Long-term results of the R-CHOP study in the treatment of elderly patients with diffuse large B-cell lymphoma: a study by the Groupe d'Etude des Lymphomes de l'Adulte. *J Clin Oncol* 2005;23(18):4117-4126.
  34. Coiffier B, Thieblemont C, Van Den Neste E et al. Long-term outcome of patients in the LNH-98.5 trial, the first randomized study comparing rituximab-CHOP to standard CHOP chemotherapy in DLBCL patients: a study by the Groupe d'Etudes des Lymphomes de l'Adulte. *Blood* 2010;116(12):2040-2045.
  35. Al-Abbadi MA, Hattab EM, Tarawneh M, Orazi A, Ulbright TM. Primary testicular and paratesticular lymphoma: a retrospective clinicopathologic study of 34 cases with emphasis on differential diagnosis. *Arch Pathol Lab Med* 2007;131(7):1040-1046.
  36. Shenkier TN, Voss N, Chhanabhai M et al. The treatment of primary central nervous system lymphoma in 122 immunocompetent patients: a population-based study of successively treated cohorts from the British Columbia Cancer Agency. *Cancer* 2005;103(5):1008-1017.
  37. Hattab EM, Martin SE, Al-Khatib SM et al. Most primary central nervous system diffuse large B-cell lymphomas occurring in immunocompetent individuals belong to the nongerminal center subtype: a retrospective analysis of 31 cases. *Mod Pathol* 2010;23(2):235-243.

38. Yamanaka R, Morii K, Shinbo Y et al. Results of treatment of 112 cases of primary CNS lymphoma. *Jpn J Clin Oncol* 2008;38(5):373-380.
39. Leopardo D, Di LG, De RA et al. Efficacy of rituximab in gastric diffuse large B cell lymphoma patients. *World J Gastroenterol* 2010;16(20):2526-2530.
40. Hung YS, Lin TL, Kuo MC et al. Primary gastric diffuse large B-cell lymphoma. *Chang Gung Med J* 2008;31(2):159-166.
41. Zhang J, Wang MY, Xu LC et al. [Clinical analysis of primary gastric diffuse large B-cell lymphoma]. *Zhonghua Zhong Liu Za Zhi* 2010;32(8):614-618.
42. Grange F, Beylot-Barry M, Courville P et al. Primary cutaneous diffuse large B-cell lymphoma, leg type: clinicopathologic features and prognostic analysis in 60 cases. *Arch Dermatol* 2007;143(9):1144-1150.
43. Ziepert M, Hasenclever D, Kuhnt E et al. Standard International prognostic index remains a valid predictor of outcome for patients with aggressive CD20+ B-cell lymphoma in the rituximab era. *J Clin Oncol* 2010;28(14):2373-2380.
44. A predictive model for aggressive non-Hodgkin's lymphoma. The International Non-Hodgkin's Lymphoma Prognostic Factors Project. *N Engl J Med* 1993;329(14):987-994.
45. Mok TS, Steinberg J, Chan AT et al. Application of the international prognostic index in a study of Chinese patients with non-Hodgkin's lymphoma and a high incidence of primary extranodal lymphoma. *Cancer* 1998;82(12):2439-2448.
46. Alizadeh AA, Eisen MB, Davis RE et al. Distinct types of diffuse large B-cell lymphoma identified by gene expression profiling. *Nature* 2000;403(6769):503-511.
47. Gutierrez-Garcia G, Cardesa-Salzman T, Climent F et al. Gene-expression profiling and not immunophenotypic algorithms predicts prognosis in patients with diffuse large B-cell lymphoma treated with immunochemotherapy. *Blood* 2011;117(18):4836-4843.
48. Fu K, Weisenburger DD, Choi WW et al. Addition of rituximab to standard chemotherapy improves the survival of both the germinal center B-cell-like and non-germinal center B-cell-like subtypes of diffuse large B-cell lymphoma. *J Clin Oncol* 2008;26(28):4587-4594.
49. Lenz G, Staudt LM. Aggressive lymphomas. *N Engl J Med* 2010;362(15):1417-1429.
50. Huang JZ, Sanger WG, Greiner TC et al. The t(14;18) defines a unique subset of diffuse large B-cell lymphoma with a germinal center B-cell gene expression profile. *Blood* 2002;99(7):2285-2290.
51. Abdel-Ghaffar H, El-Aziz SA, Shahin D et al. Prognostic value of the t(14;18)(q32;q21) in patients with diffuse large B-cell lymphoma. *Cancer Invest* 2010;28(4):376-380.
52. Young KH, Leroy K, Moller MB et al. Structural profiles of TP53 gene mutations predict clinical outcome in diffuse large B-cell lymphoma: an international collaborative study. *Blood* 2008;112(8):3088-3098.
53. Gianelli U, Patriarca C, Moro A et al. Lymphomas of the bone: a pathological and clinical study of 54 cases. *Int J Surg Pathol* 2002;10(4):257-266.
54. Bhagavathi S, Micale MA, Les K, Wilson JD, Wiggins ML, Fu K. Primary bone diffuse large B-cell lymphoma: clinicopathologic study of 21 cases and review of literature. *Am J Surg Pathol* 2009;33(10):1463-1469.
55. Lima FP, Bousquet M, Gomez-Brouchet A et al. Primary diffuse large B-cell lymphoma of bone displays preferential rearrangements of the c-MYC or BCL2 gene. *Am J Clin Pathol* 2008;129(5):723-726.
56. Tagawa H, Suguro M, Tsuzuki S et al. Comparison of genome profiles for identification of distinct subgroups of diffuse large B-cell lymphoma. *Blood* 2005;106(5):1770-1777.
57. Jardin F, Jais JP, Molina TJ et al. Diffuse large B-cell lymphomas with CDKN2A deletion have a distinct gene expression signature and a poor prognosis under R-CHOP treatment: a GELA study. *Blood* 2010;116(7):1092-1104.

58. Iqbal J, Neppalli VT, Wright G et al. BCL2 expression is a prognostic marker for the activated B-cell-like type of diffuse large B-cell lymphoma. *J Clin Oncol* 2006;24(6):961-968.
59. Wilson KS, Sehn LH, Berry B et al. CHOP-R therapy overcomes the adverse prognostic influence of BCL-2 expression in diffuse large B-cell lymphoma. *Leuk Lymphoma* 2007;48(6):1102-1109.
60. Dunleavy K, Staudt LM, Wilson WH. The BCL-2 biomarker in the era of molecular diagnosis of diffuse large B-cell lymphoma. *Leuk Lymphoma* 2007;48(6):1061-1063.
61. Pavan A, Spina M, Canzonieri V, Sansonno S, Toffoli G, De R, V. Recent prognostic factors in diffuse large B-cell lymphoma indicate NF-kappaB pathway as a target for new therapeutic strategies. *Leuk Lymphoma* 2008;49(11):2048-2058.
62. Rayet B, Gelinas C. Aberrant rel/nfkb genes and activity in human cancer. *Oncogene* 1999;18(49):6938-6947.
63. Courtois G, Gilmore TD. Mutations in the NF-kappaB signaling pathway: implications for human disease. *Oncogene* 2006;25(51):6831-6843.
64. Davis RE, Brown KD, Siebenlist U, Staudt LM. Constitutive nuclear factor kappaB activity is required for survival of activated B cell-like diffuse large B cell lymphoma cells. *J Exp Med* 2001;194(12):1861-1874.
65. Espinosa I, Briones J, Bordes R et al. Activation of the NF-kappaB signalling pathway in diffuse large B-cell lymphoma: clinical implications. *Histopathology* 2008;53(4):441-449.
66. Liu X, Wang B, Ma X, Guo Y. NF-kappaB activation through the alternative pathway correlates with chemoresistance and poor survival in extranodal NK/T-cell lymphoma, nasal type. *Jpn J Clin Oncol* 2009;39(7):418-424.
67. Hans CP, Weisenburger DD, Greiner TC et al. Confirmation of the molecular classification of diffuse large B-cell lymphoma by immunohistochemistry using a tissue microarray. *Blood* 2004;103(1):275-282.
68. Choi WW, Weisenburger DD, Greiner TC et al. A new immunostain algorithm classifies diffuse large B-cell lymphoma into molecular subtypes with high accuracy. *Clin Cancer Res* 2009;15(17):5494-5502.

# Chapter 2

## Primary non-Hodgkin's lymphoma of bone: a clinicopathological investigation of 60 cases

E.H. Heyning<sup>1</sup>, P.C.W. Hogendoorn<sup>1,5</sup>, M.H.H. Kramer<sup>1</sup>, J. Hermans<sup>3</sup>, J.C. Kluin-Nelemans<sup>4</sup>, E.M. Noordijk<sup>2,5</sup> and Ph.M. Kluin<sup>1</sup>

*Departments of <sup>1</sup>Pathology, <sup>4</sup>Haematology, <sup>2</sup>Radiation Oncology and <sup>3</sup>Medical Statistics, Leiden University Medical Centre and <sup>5</sup>Netherlands Committee on Bone Tumours, Leiden, The Netherlands*

*Leukemia, 1999; 13; 2094-8*

## Abstract

A retrospective analysis of patients presenting with primary lymphoma of bone (PLB) was performed to determine clinical factors affecting prognosis in relation to histological subtype and treatment outcome. Data from 106 patients, presenting with a PLB between 1943 and 1996, were retrieved from the files of the Netherlands Committee on Bone Tumours and Leiden University Medical Centre. The lymphomas were reclassified according to the REAL and updated Kiel classification. The clinical presentation, survival and prognostic factors were investigated. Sixty patients had sufficient clinical information and adequate follow-up to be included in the study. All 33 PLB that could be immunophenotyped were of B cell origin. According to the REAL classification, most PLB were large (B) cell lymphomas (92%) and according to the Kiel classification 45% of the tumours were centroblastic multilobated. PLB presented most often in the long bones (48%), with Ann Arbor stage I (46%), II (16%), IV (16%) and unknown (20%). Stage IV disease was exclusively caused by the presence of multiple bone lesions. Notwithstanding the heterogeneous treatment, the 5 year overall survival was 61%; 46% of patients were progression free at 5 years. Patients at presentation older than 60 had a worse overall survival (76% vs 37%,  $P = 0.0002$ ) and a worse progression free period (58% vs 28%,  $P = 0.0073$ ). Patients with the immunoblastic subtype had a worse survival than the centroblastic mono/polymorphic subtype or the centroblastic multilobated subtype ( $P = 0.015$ ). Primary lymphoma of bone represents an uncommon bone tumour with a relatively homogeneous morphology and clinical behaviour. Compared to other aggressive lymphomas, PLB have a favourable prognosis.



## Introduction

Primary lymphoma of bone (PLB) is a rare disease, first described by Oberling in 1928.<sup>1</sup> It was not until 1939 that Parker and Jackson<sup>2</sup> described 17 cases of 'primary reticulum cell sarcoma of bone' and established PLB as a distinct clinical entity. Even today the diagnosis of PLB can be difficult due to the relatively non-specific radiographic appearance and the sometimes profound proliferation of reactive fibroblasts at the histological level.<sup>3</sup> Thus, PLB can be erroneously interpreted as a primary skeletal tumour of non-lymphoid origin such as Ewing's sarcoma or malignant fibrous histiocytoma.

Most studies on PLB published so far describe small groups of patients. In many studies stage IV tumours were excluded and patients were only treated with radiotherapy.<sup>4-11</sup> Uniform directives for classification, treatment and prognosis are still lacking. We describe a relatively large group of 60 patients with clinico-radiologically and histologically documented PLB, collected from the files of the Netherlands Committee on Bone Tumours and the Leiden University Medical Centre. Our objective was to document patient and tumour characteristics of this cohort with emphasis on histological subtype, substantiated by immunohistochemistry and to define factors affecting prognosis for PLB.

## Materials and methods

### Patients

The files from the registry of the Netherlands Committee on Bone Tumours with diagnosis codes 'malignant lymphoma', 'reticulum cell sarcoma' or 'lymphosarcoma' involving bone were reviewed. This registry contains more than 11000 cases, collected between 1943 and 1996 and includes clinical data at presentation, histological slides of the tumour and complete radiographic documentation. In addition to these cases, patients registered at the Leiden University Medical Centre with a diagnosis of primary non-Hodgkin's lymphoma of bone were selected. A total number of 106 patients were identified. Of this group 30 patients were excluded because of a different diagnosis after review of the histological slides, combined with new immunohistochemical data or clinical data obtained at follow-up. These cases included Ewing's sarcoma ( $n = 8$ ), acute lymphoblastic leukaemia/lymphoma ( $n = 5$ ) or Burkitt's lymphoma/leukaemia ( $n = 3$ ), acute myeloid -leukaemia ( $n = 3$ ), multiple myeloma ( $n = 3$ ), secondary bone involvement of NHL ( $n = 3$ ), Hodgkin's lymphoma ( $n = 2$ ) or inappropriate histological material for review ( $n = 3$ ). For a diagnosis of PLB, patients had to present with a histologically proven lymphoma arising within the medullary cavity of a bone, with or without regional lymph node involvement. Multiple bone lesions were acceptable as long as there was no evidence of earlier lymphomatous involvement elsewhere.

A questionnaire was sent to the collaborating hospitals to obtain follow-up data for the 76 selected patients. Follow-up data were successfully collected for 60 patients, whereas 16 patients were lost to follow-up. The last date of follow-up was December 1996. From these

60 cases, 54 were retrieved from the Netherlands Committee on Bone Tumours and six from the Leiden University Medical Centre. The patient records were reviewed for the following parameters: sex, tumour localisation, tumour diameter (5 cm, 5 cm as measured on the radiographs), treatment, response to treatment, date and site of relapse or progression if applicable, date of last follow-up or date of death and cause of death. The clinical parameters age, stage, serum LDH level, number of extranodal sites and performance status according to the Eastern Cooperative Oncology Group scale of the International Prognostic Index (IPI) for aggressive non-Hodgkin's lymphoma<sup>12</sup> were used. Stage was defined according to the Ann Arbor staging classification. Serum LDH level was recorded as 1.5× normal or 1.5 × normal. The number of extranodal sites was defined as the number of all extranodal sites including the bone localisations. According to the IPI<sup>12</sup> performance status was grouped as 0 or 1 (the patient was ambulatory) or 2, 3 or 4 (the patient was not ambulatory).

### **Histological classification and immunohistochemistry**

The pathological diagnosis was established according to the REAL classification<sup>13</sup> and updated Kiel classification<sup>14</sup> using standard histological criteria and, if possible, immunohistochemistry. Immunohistochemical studies were performed on paraffin-embedded material, and could be interpreted in 33 of 60 cases. In the remaining 27 cases the material was not available or inappropriate due to decalcification artefacts. The antibodies used in this study included leukocyte common antigen (CD45) (Dakopatts, Copenhagen, Denmark), L26 as a B cell marker (CD20) (Dakopatts), and a T cell marker (CD3) (Dakopatts). In some cases BerH2 (CD30) (Dakopatts) was also used. Immunohistochemical procedures were performed as detailed previously.<sup>15</sup>

### **Staging**

Staging investigations performed varied over time and patients were staged retrospectively according to the Ann Arbor staging classification. For the purpose of this study, staging was defined as complete if it included: (1) a chest X-ray or a CT scan of the chest; (2) lymph-angiography or CT-scan or echography of the abdomen and pelvis; (3) bone marrow biopsy; and (4) total body bone scintigraphy or MRI. Defined as such 20 patients were completely staged and 40 were not. The investigation most frequently missing in the incompletely staged patients was a bone marrow biopsy.

### **Treatment**

Since 1943 a wide variety of therapies has been used, including radiotherapy, chemotherapy and surgery in various combinations. The patients receiving chemotherapy were subdivided into a group treated with CHOP (cyclophosphamide, adriamycin, vincristine, prednisone) or CHOP-like therapy and a remaining group with mostly non-adriamycin containing single agent therapy. Surgery consisted of either resection or amputation. As patient numbers were too small to perform statistical analysis on all the different treatment combinations, we selected

the following groups (Table 1): group I ( $n = 5$ ) was treated with radiotherapy alone (c-r+s-), group II ( $n = 24$ ) was treated with radiotherapy and chemotherapy (c+r+s-), and group III ( $n = 11$ ) was treated with radiotherapy, chemotherapy and surgery (c+r+s+). The remaining 20 patients received either other combinations of therapy or inadequate therapy (for example radiotherapy <30 Gy). In group II, 15 of 24 patients and in group III, six of 11 patients received adriamycin containing (CHOP or CHOP-like) chemotherapy.

Response to treatment was recorded as complete remission, partial remission (>50% reduction of tumour), no change or progressive disease.

### Survival analysis

For the whole cohort ( $n = 60$ ) the overall survival time was calculated from time of diagnosis until time of death or until date of last follow-up (December 1996). The progression-free period was calculated from the date of diagnosis to the date of progression or relapse or to last contact in case the patient was progression free. Patients who had progressive disease in response to treatment were considered to have a progression free period of 0 months. The five patients of whom the response to treatment could not be determined were excluded from the progression-free period analysis. Survival curves were calculated according to the Kaplan and Meier method; survival analysis was performed using the log-rank test. We performed univariate analysis on the following factors: sex, tumour localisation, tumour diameter, histological subtype, treatment, age, stage, and the level of serum LDH.

## Results

### Patient characteristics

Patient characteristics are summarised in Table 1. The group consisted of 39 males and 21 females, a ratio of 1.8 consistent with other studies.<sup>8</sup> The age of the patients varied from 13 to 86 years (median 48). The PLB most often presented in the long bones (29 localisations, 48%), of which seven localisations (12%) presented in the upper limb and 22 localisations (36%) in the lower limb (Figure 1). In 10 patients (16%) more than one bone localisation was found. The symptoms at presentation were local pain and/or a palpable mass. Three patients presented with a pathologic fracture. No B symptoms were reported in this cohort.

### Clinical staging

In 48 patients the stage could be assigned. Twenty-eight patients presented with stage I disease, 10 with stage II, and 10 with stage IV (Table 1). Twenty-eight out of all 48 patients and 21 out of 38 patients with stage I or II disease had undergone an incomplete staging procedure. All stage II tumours had lymph node involvement near the site of the bone localisation. All stage IV tumours had more than one bone localisation and none had bone marrow or other distant organ involvement. Three of the 20 completely staged and seven of the 28 incompletely staged

**Table 1.** Summary of clinical, histological and therapeutical parameters

Parameter	No. of patients () <sup>a</sup>	Percentage
Sex		
Male	39	65
Female	21	35
Stage		
I	28	46
II	10	16
III	0	0
IV	10	16
Unknown	12	20
Completely staged	20	33
Incompletely staged and unknown	40	67
Histology		
Follicle center cell, diffuse	2 (1)	3
Large B cell	55 (32)	92
Centroblastic mono/polymorphic <sup>b</sup>	18 (12)	30
Centroblastic multilobated <sup>b</sup>	27 (15)	45
Immunoblastic <sup>b</sup>	10 (5)	16
Anaplastic large cell	2 (0)	3
Immunocytoma	1 (0)	2
Therapy		
Radiotherapy only	5	8
Radiotherapy and chemotherapy	24	40
Radiotherapy, chemotherapy and surgery	11	18
Other combinations	20	33
Chemotherapy		
CHOP or CHOP-like	23	38
Other chemotherapy	15	25
Response to therapy		
Complete remission	29	48
Partial remission	5	8
No change	1	2
Progressive disease	20	33
Unknown	5	8

<sup>a</sup>Immunohistochemistry performed.

<sup>b</sup>Updated Kiel classification.<sup>14</sup>

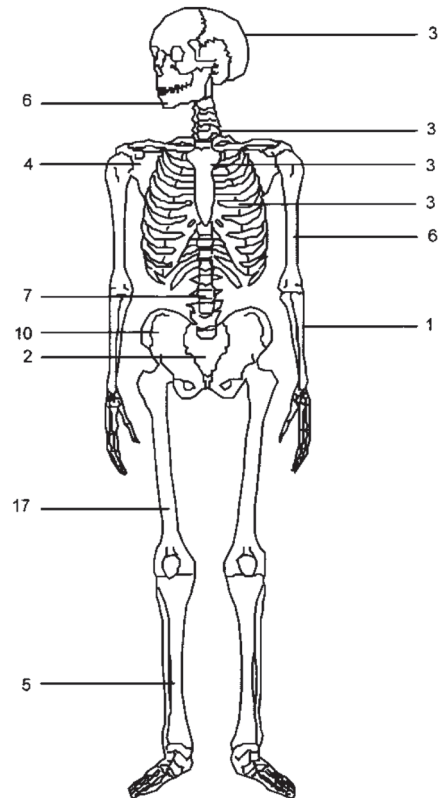
patients had stage IV disease. This makes understaging in the latter group somewhat unlikely. In the remaining 12 patients the stage could not be determined.

### Histological classification and immunohisto-chemistry

The results of the histological analysis and immunohistochemistry are given in Table 1. All 33 out of 60 lymphomas that could be immunophenotyped were of B cell origin. Based on the routine histological slides and limited immunophenotypic data available, almost all lymphomas (92%) were large (B) cell lymphomas according to the REAL classification.<sup>13</sup> According to the updated Kiel classification<sup>14</sup> 45% of the PLB were of the centroblastic multilobated subtype. The two anaplastic large cell lymphomas could not be immunophenotyped, and therefore, it cannot be excluded that they belonged to a subset of large B cell lymphomas with anaplastic morphology.<sup>14</sup>

### Response to treatment, survival and prognostic factors

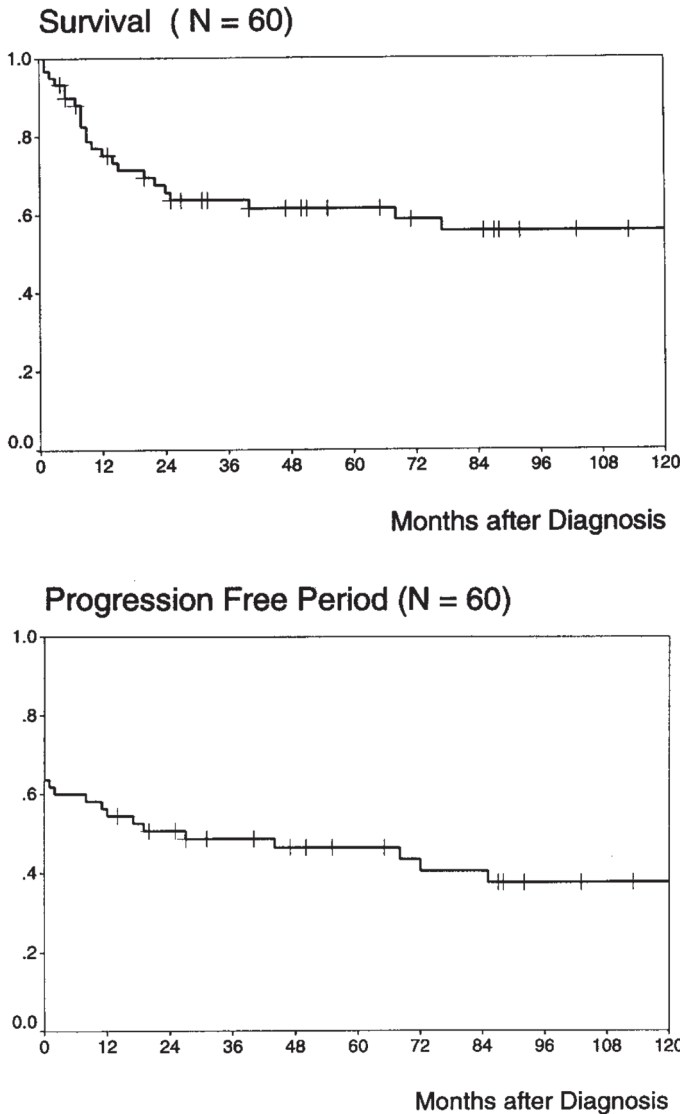
Forty-eight percent (n = 29) of 60 patients achieved complete remission, 8% partial remission, 2% showed no change, 33% had progressive disease and in 8% of the patients response to therapy could not be determined (Table 1).



**Figure 1.** Tumor localisation. PLB most often presented in the long bones (50%): in the upper limb (12%) and in the lower limb (38%). Ten patients presented with more than one bone localisation. The site of these multiple localisations are included in the figure (70 localisations in total).

The mean follow-up for the whole cohort was 174 months, ranging from 1 to 296 months. At 5 years after diagnosis 46% of the patients were free of progression. The 5-year overall survival was 61% for all patients, 66% for patients with stage I and II and 50% for patients with stage IV (Figure 2). Nine out of 29 patients relapsed. The localisation of the relapses were bone ( $n = 3$ ), lymph nodes ( $n = 3$ ), liver ( $n = 1$ ), lungs ( $n = 1$ ) and breast ( $n = 1$ ). Twenty-three patients died during follow-up. The cause of death was primary refractory disease in 18 patients, relapse in four patients and unrelated to NHL in one patient.

For statistical purposes we only included the three largest histological groups (centroblastic mono/polymorphic, centroblastic multilobated and immunoblastic) in the survival and

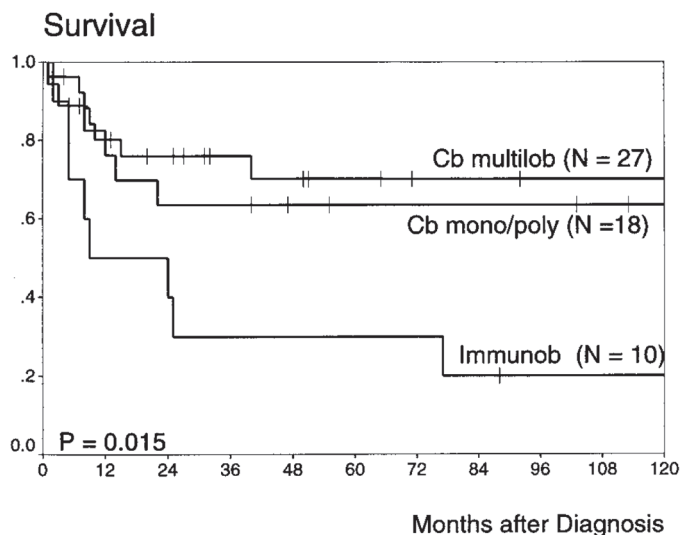


**Figure 2.** Survival in primary NHL of bone. The 5 year overall survival was 61% for all patients ( $n = 60$ ; upper-panel). At 5 years after diagnosis 46% of patients were free of progression ( $n = 60$  patients, lower panel).

progression-free survival analysis. The immunoblastic subtype (as defined by the Kiel classification<sup>14</sup> containing 90% or more immunoblasts) had a statistically significantly shorter overall survival and progression-free period than the other subtypes ( $P = 0.015$  and  $P = 0.05$ , respectively; Figure 3).

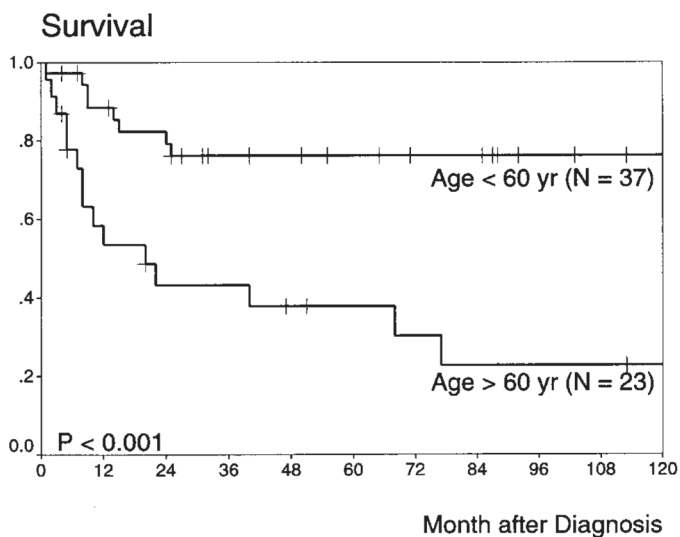
As a consequence of often incomplete clinical data the risk groups defined in the International Prognostic Index could not be determined. We analysed the influence of the individual factors age, sex, primary localisation, tumour size, stage and serum LDH on survival. To prevent bias, only the cases with sufficient data for all six parameters were included in the univariate analysis. Age was a significant prognosticator, with a 5 year overall survival of 76% for patients younger than 60 years and 37% for patients of 60 years and older ( $P = 0.0002$ ; Figure 4) and a 5-year progression-free period of 58% vs 28% ( $P = 0.0073$ ). As there was no difference in survival between stage I and stage II patients, we analysed stage I and II against stage IV. Although there was a trend towards worse survival for stage IV, it was not statistically significant ( $P = 0.56$ ). An elevated serum LDH was associated with decreased overall survival ( $P = 0.25$ ) but this did not reach statistical significance, probably because of the relatively small numbers of patients who could be analysed ( $n = 38$ ). No statistically significant effect on survival was found after univariate analysis of the other prognostic factors such as sex, tumour localisation, and tumour size.

Survival was not statistically different for the three selected treatment combinations. The overall survival of patients treated with CHOP or CHOP-like chemotherapy was not significantly better than the survival of patients treated with other types of chemotherapy ( $P = 0.17$ ). The progression-free period, however, was significantly longer for patients treated with CHOP or CHOP-like therapy, with a 5 year progression-free period of 58% vs 27% (data not shown). A confounding factor is that adequate staging and treatment are related: after 1975 both staging procedures (introduction of CT scan) and treatment modalities (introduction of CHOP or CHOP-like chemotherapy) improved. To investigate the possible impact of accuracy



**Figure 3.** Comparison of tumor subtype related to overall survival. Patients with the immunoblastic subtype had a worse overall survival than the centroblastic multilobated subtype or the centroblastic mono/polymorphic subtype.

**Figure 4.** Comparison of age groups under and over 60 years related to overall survival. The 5-year overall survival was 76% for the patients younger than 60 years ( $n = 37$ ) and 37% for the patients of 60 years and older ( $n = 23$ ).



of diagnostic procedures on survival we analysed the role of complete staging: patients with complete staging had a slightly better prognosis with respect to overall survival, but it did not prove statistically significant in univariate analysis ( $P = 0.48$ ).

## Discussion

The presentation of NHL as a localised bone tumour is relatively uncommon. Any study of the pathophysiology of PLB and on prognostic factors is complicated by the small patient numbers and by the fact that the results of earlier studies are often not comparable to each other.<sup>4-6</sup> We studied a relatively large and representative group of patients, diagnosed and treated between 1943 and 1996. Patients were selected by reviewing all cases previously diagnosed as malignant lymphoma, lymphosarcoma or reticulum cell sarcoma. Since we did not review all primary bone tumours, we cannot exclude that especially in the early years of the registry, a few tumours were misdiagnosed as Ewing's sarcoma or, in case of excessive fibrosis, as sarcoma not otherwise specified, and thus were not included here.

We show that the patients display a homogeneous pathological and clinical presentation as well as clinical behaviour. Histologically, almost all PLBs were of the large B cell type, and half of these tumours were of the multilobated centroblastic subtype. The very high frequency of this latter subtype had been reported previously.<sup>16</sup> The majority of patients presented with pain and/or a palpable mass, most often at a single localisation in one of the long bones. Approximately one quarter of the patients presented with multiple bone lesions, which is in accordance with other studies.<sup>9</sup> Of note, these patients made up the entire group of stage IV patients. In line with a specific pattern of dissemination and homing of tumour cells in PLB, three of nine patients had bone localisations upon relapse.



The initial treatment for these tumours, before chemotherapy became available, was radiotherapy or surgery. Several studies suggest that the combination of chemotherapy and radiotherapy is the best treatment, as a consequence of which resection or amputation can be prevented.<sup>4,17,18</sup> In this cohort the overall 5 year survival was 61%. This is surprisingly high when the heterogeneous treatment schedules over the years of the study and the inclusion of stage IV patients are taken into account. Although survival was not statistically different for the three selected treatment combinations, patients treated with CHOP or CHOP-like therapy had a longer progressionfree period than patients treated with other types of chemotherapy. Although our data are derived from a retrospective analysis of a very heterogeneous study group, some conclusions may be drawn with respect to prognostic factors. Consistent with previous reports,<sup>10,11</sup> immunoblastic lymphoma as defined by the updated Kiel classification,<sup>14</sup> had a worse prognosis than other large B cell lymphoma subtypes. In the past, the clinical parameters used to predict prognosis in PLB, were tumour stage and localisation.<sup>7,8,10,11</sup> We found these prognostic factors not easily applicable to PLB. Furthermore, as in other extra-nodal lymphomas, in PLB prognosis is not strongly affected by regional lymph node involvement: there was no difference in survival between stage I and stage II tumours and just a trend towards worse prognosis in stage IV tumours. This underlines that the Ann Arbor classification is not suitable for staging and predicting prognosis in PLB. Of note, many studies on PLB excluded patients with stage IV disease, partly in an effort to eliminate malignancies in which bone involvement is secondary.<sup>4-6,19</sup> This exclusion is not supported by our data that stage IV disease is mostly determined by multiple, osseous localisations.

Tumour localisation was no significant prognostic factor, neither could we confirm the suggestion that tumour localisation within the pelvis, ribs or vertebra is associated with a worse prognosis.<sup>8</sup> It is interesting that more than 50% of the stage IV tumours had at least one localisation in the pelvis, the vertebra or the ribs.

In conclusion, we propose that primary non-Hodgkin's lymphoma of bone be acknowledged as a specific clinicopathologic entity. Morphologically, PLB forms a homogeneous group and dissemination is often restricted. Furthermore, PLB patients seem to have a better survival than other NHL patients, even with therapy that is considered inadequate nowadays. Finally, this study suggests that age at presentation and tumour subtype are prognostic factors in PLB.

## References

- 1 Oberling C. Les reticulosarcomes et les reticuloendotheliosarcomes de la moelle osseuse (sarcomes d'Ewing). *Bull Assoc Fr Etude Cancer* (Paris) 1928; 17: 259–296.
- 2 Parker F Jr, Jackson H Jr. Primary reticulum cell sarcoma of bone. *Surg Gynecol Obstet* 1939; 68: 45–53.
- 3 Kluin PM, Slootweg PJ, Schuurman HJ, Go DMDS, Rademakers LHPM, Van der Putte SCJ, Van Unnik JAM. Primary B-cell malignant lymphoma of the maxilla with a sarcomatous pattern and multilobated nuclei. *Cancer* 1984; 54: 1598–1605.
- 4 Rathmell AJ, Gospodarowicz MK, Sutcliffe SB, Clark RM. Localised lymphoma of bone. Prognostic factors and treatment recommendations. *Br J Cancer* 1992; 66: 603–606.
- 5 Fairbanks RK, Bonner JA, Inwards CY, Strickler JG, Habermann TM, Unni KK, Su J. Treatment of stage IE primary lymphoma of bone. *Int J Radiat Oncol Biol Phys* 1994; 28: 363–371.
- 6 Bacci G, Jaffe N, Emiliani E, Van Horn J, Manfrini M, Picci P, Bertoni F, Gherlinzoni E, Campanacci M. Therapy for primary non-Hodgkin's lymphoma of bone and a comparison of results with Ewing's sarcoma. Ten years' experience at the Istituto Ortopedico Rizzoli. *Cancer* 1986; 57: 1468–1472.
- 7 Dosoretz DE, Raymond AK, Murphy GF, Doppke KP, Schiller AL, Wang CC, Suit HD. Primary lymphoma of bone. The relationship of morphologic diversity to clinical behavior. *Cancer* 1982; 50: 1009–1014.
- 8 Ostrowski ML, Unni KK, Banks PM, Shives TC, Evans RG, O'Connell MJ, Taylor WF. Malignant lymphoma of bone. *Cancer* 1986; 58: 2646–2655.
- 9 Mendenhall NP, Jones JJ, Kramer BS, Hudson TM, Carter RL, Enneking WF, Marcus RB Jr, Million RR. The management of primary lymphoma of bone. *Radiother Oncol* 1987; 9: 137–145.
- 10 Clayton F, Butler JJ, Ayala AG, Ro JY, Zornoza J. Non-Hodgkin's lymphoma in bone. Pathologic and radiologic features with clinical correlates. *Cancer* 1987; 60: 2494–2501.
- 11 Vassallo J, Roessner A, Vollmer E, Grundmann E. Malignant lymphomas with primary bone manifestation. *Path Res Pract* 1987; 182: 381–389.
- 12 The Non-Hodgkin's Lymphoma Prognostic Factors Project. A predictive model for aggressive non-Hodgkin's lymphoma. *New Engl J Med* 1993; 329: 987–994.
- 13 Harris NL, Jaffe ES, Stein H, Banks PM, Chan JKC, Cleary ML, Delsol G, De Wolf-Peeters C, Falini B, Gatter KC et al. A revised European-American classification of lymphoid neoplasms. A proposal from the International Lymphoma Study Group. *Blood* 1994; 84: 1361–1392.
- 14 Stansfeld AG, Diebold J, Noel H, Kapanci Y, Rilke F, Kelenyi G, Sundstrom C, Lennert K, Van Unnik JAM, Mioduszewska O et al. Updated Kiel classification for lymphomas. *Lancet* 1988; i: 292–293.
- 15 Kramer MHH, Hermans J, Parker J, Krol ADG, Kluin-Nelemans JC, Haak HL, Van Groningen K, Van Krieken JHJM, De Jong D, Kluin PM. The clinical significance of BCL2 and P53 protein expression in diffuse large B-cell lymphoma: a population-based study. *J Clin Oncol* 1996; 14: 2131–2138.
- 16 Pettit CK, Zukerberg LR, Gray MH, Ferry JA, Rosenberg AE, Harmon DC, Harris NL. Primary lymphoma of bone. A B-cell neoplasm with a high frequency of multilobated cells. *Am J Surg Pathol* 1990; 14: 329–334.
- 17 Baar J, Burkes RL, Bell R, Blackstein ME, Fernandes B, Langer F. Primary non-Hodgkin's lymphoma of bone. A clinicopathologic study. *Cancer* 1994; 73: 1194–1199.

- 18 Dubey P, Ha CS, Besa PC, Fuller L, Cabanillas F, Murray J, Hess MA, Cox JD. Localised primary malignant lymphoma of bone. *Int J Radiat Oncol Biol Phys* 1997; 37: 1087–1093.
- 19 Case 21–1996. Hodgkin's disease, nodular-sclerosis type, involving multiple bones. *New Engl J Med* 1996; 335: 115–122.



# Chapter 3

## MR imaging characteristics in primary lymphoma of bone with emphasis on non-aggressive appearance

Fenna H. Heyning<sup>1</sup>, Herman M. J. A. Kroon<sup>2</sup>, Pancras C. W. Hogendoorn<sup>3</sup>,  
Antonie H. M. Taminiau<sup>4</sup>, Henk-Jan van der Woude<sup>5</sup>

*Department of<sup>1</sup>Haematology, <sup>2</sup>Radiology, <sup>3</sup>Pathology and <sup>4</sup>Orthopaedic Surgery,  
Leiden University Medical Centre, Leiden, The Netherlands and <sup>5</sup>Department of Radiology,  
Onze Lieve Vrouwe Gasthuis, Amsterdam, The Netherlands*

*Skeletal Radiology, 2007; 937-944*

## Abstract

*Purpose.* To assess the heterogeneity of magnetic resonance (MR) imaging characteristics in primary lymphoma of bone (PLB), in particular the non-aggressive appearance.

*Subjects and methods.* In a retrospective study, MR imaging features were analyzed in 29 patients with histologically proven PLB. The following parameters were evaluated: tumor size, bone marrow and extension into soft tissues, signal characteristics of bone marrow and soft-tissue components, including enhancement, and involvement of cortical bone (complete disruption, focal destruction, permeative destruction and cortical thickening).

*Results.* PLB presented with extension into the soft tissue in 22 (76%) of 29 patients, was only subtle in three of these 22 patients, and was absent in seven patients. Signal intensity (SI) of the soft-tissue part was most frequently homogeneously isointense with muscle on T1-weighted images (90%) and high on T2-weighted images (91%). Enhancement was predominantly homogeneous and diffuse (82%). In 93% of patients cortical bone appeared abnormal: among those patients complete cortical disruption was seen in 28%, with extension into soft tissues in all but one patient; a permeative pattern of destruction was present in 52% of patients, 66% of these had an associated soft-tissue mass. Two patients with normal-appearing cortical bone had no extension into soft tissues. In two patients focal cortical destruction was noticed; in one patient cortical bone was homogeneously thickened, and in one patient PLB was selectively localized within the cortical bone. SI of the bone marrow tumor component was more frequently heterogeneous (in 54%), compared with the soft-tissue component, being high on T2-weighted images in 89%, intermediate in 7% and low in 4%. Similarly, enhancement was heterogeneous in 59%.

*Conclusion.* The MR imaging appearance of PLB is variable. In 31% of PLB patients, the tumor was intraosseous, with linear cortical signal abnormalities or even normal-appearing or thickened cortical bone without soft-tissue mass, and, as such, PLB may not infrequently look non-aggressive on MR imaging.

## Introduction

Primary lymphoma of bone (PLB) is a rare disease, accounting for less than 1% of all non-Hodgkin's lymphoma (NHL) cases and 3–5% of all extra-nodal lymphoma cases [1-3]. According to the World Health Organization (WHO) classification of hematological malignancies, it is a distinct clinic-pathological subtype of extra-nodal, diffuse, large B-cell lymphoma (DLBCL) with a relatively homogeneous pathological and clinical presentation [4, 5]. Almost all tumors are of the large B-cell type, morphologically composed of large centroblastic cells, frequently with multilobated nuclei [5-8]. The prognosis of PLB, depending on staging and histologic classification, is favorable following combined modality (chemo- and radiation) therapy, with a 5-year overall survival rate that extends to 88% [7, 9–12].

Debates are ongoing as to whether there is a uniform imaging pattern in PLB, in particular on the magnetic resonance (MR) imaging characteristics of PLB. Some authors have stated that a tumor with normal-appearing cortical bone and a substantial soft-tissue mass is likely to be a non-Hodgkin's lymphoma [13, 14]. One study focused on the hypointense signal intensities on T2-weighted images as a feature that may be characteristic of PLB as opposed to other malignant tumors [15]. In other studies MR findings were found to be non-specific and not useful for differentiating PLB from other small, blue, round cell tumors, including Ewing's sarcoma and small cell osteosarcoma and (in older age groups) tumors such as metastases of carcinoma and plasmacytoma [16]. In addition, the plain radiographic appearance of PLB differs from virtually normal to a severely permeative pattern of bone destruction with a blastic, lytic or mixed appearance, and, as such, is also non-specific [17–19].

The order of differential diagnosis is, therefore, mainly based on the patient's age, race and clinical features.

To assess the homogeneity or heterogeneity of MR imaging characteristics in PLB, and to assess the rate of a non-aggressive MR imaging appearance, we evaluated various features known from the literature, with emphasis on cortical bone manifestation and marrow and soft-tissue signal characteristics, in 29 patients in the present retrospective imaging study.

## Subjects and methods

The files of 29 patients with a histologically proven diagnosis of PLB, and MR imaging studies available at the time of diagnosis, were retrieved from the archive of the Netherlands Committee on Bone Tumors, representing the period between 1989 and 2004. All histological diagnoses were re-assured for this study.

## Patients' characteristics

The study group consisted of 29 patients, 14 female and 15 male. In the majority of the patients the tumors were located in the femur (n=13) or humerus (n=6).

Other tumor sites included the ilium (n=4), scapula (n=2), tibia, acetabulum, lumbar vertebra and mandibula (one patient each). The age of the patients ranged from 19–81 years (median 40 years).

## MRI

Since the Netherlands Committee on Bone Tumors serves as a consulting medium for the entire country, MRI studies were performed on different imagers with field strengths between 0.5 T and 1.5 T. T1-weighted spin echo (SE) sequences were available for 28 patients; TRs varied from 400–800 ms, with TEs from 12–25 ms. T2-weighted (fast) SE sequences were available for 29 patients, with fatselective pre-saturation sequences for 14 patients. TRs varied from 2,000–7,000 ms, with TEs from 70–130 ms. Contrast-enhanced, T1-weighted, SE series after intravenous injection of 0.2 mmol gadopentetate dimeglumine (Gd-DTPA) were available for 25 of 29 patients, with fatselective pre-saturation sequences for ten patients. A dynamic contrast-enhanced sequence was used for only three patients. For all patients a combination of axial and longitudinal (either coronal or sagittal) images was available for evaluation.

### Imaging evaluation

The following parameters were evaluated in consensus by two experienced musculoskeletal radiologists:

*Tumor size* Tumor dimensions were established by measuring length, width and depth, assessed from the combination of axial and longitudinal images.

*Extension into the soft tissues* Presence or absence of a softtissue component, defined as a mass beyond the margins of cortical bone and periosteum, was determined.

*Soft-tissue edema* Soft-tissue edema was considered to be present when areas of peri-lesional high signal intensity (SI) were noticed on T2-weighted sequences and/or contrastenhanced T1-weighted sequences in an ill-defined feathery pattern, without disruption of the fascial plane

*Signal intensities of soft-tissue part* SIs were defined as predominantly high, intermediate, low or mixed, relative to muscle SI, assessed on both T1-and T2-weighted sequences. Furthermore, homogeneity or heterogeneity of the SI on T2-weighted images was assessed.

*Enhancement of soft-tissue part* The pattern of tumoral enhancement on T1-weighted Gd-DTPA-enhanced sequences (absent, peripheral or diffuse) was recorded, as well as the homogeneity or heterogeneity.

*Cortical bone destruction* Appearance of the cortical bone was determined as normal or abnormal on both T1-and T2weighted images. Abnormal cortical bone appearance was subdivided into complete cortical destruction (normal low SI, completely replaced by high signal intensity of tumor), focal destruction (normal low signal intensity, partially replaced by high SI of tumor with focal disturbance of cortical integrity), permeative destruction (fine linear pattern of intracortical high SI, without disturbance of cortical integrity) or cortical thickening (thickening of cortical bone, without signal abnormalities).

*Bone marrow involvement* SIs of the bone marrow component and homogeneity were assessed on T1-and T2weighted sequences, compared with muscle SI (higher, equal/intermediate, lower, mixed) and opposed to the high SI of normal bone marrow. Tumor margins were defined as sharp or unsharp.

*Enhancement of bone marrow component* The presence or absence of intra-osseous tumoral



enhancement and the pattern (homogeneous, heterogeneous, focal, diffuse) of enhancement on static T1-weighted Gd-DTPA-enhanced sequences were determined.

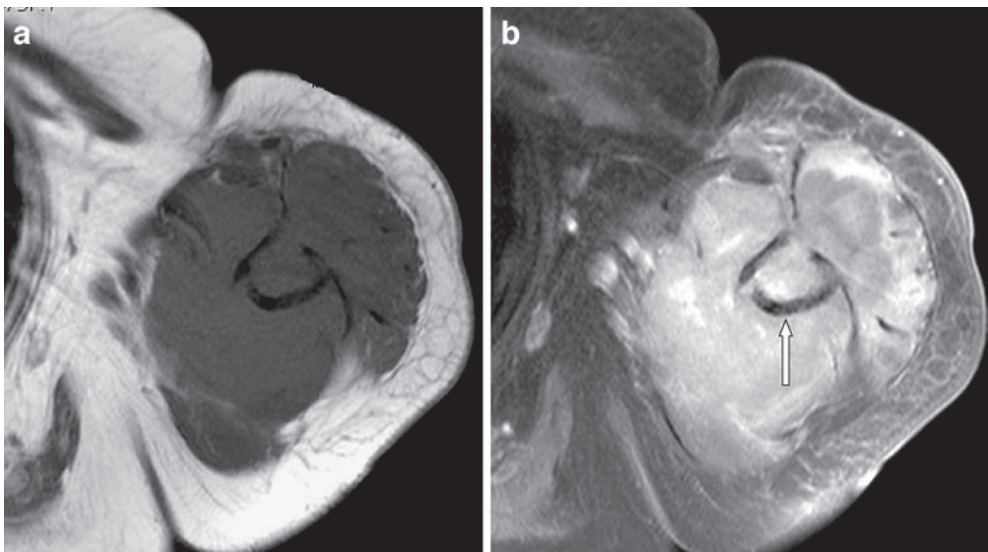
*Histological classification and immunohistochemistry* The pathology diagnosis was established according to the World Health Organization classification on biopsy material, using standard histological criteria and immunohistochemistry using antibodies directed against vimentin, CD45, CD3, CD20, CD79a, and CD99. Immunohistochemical staining was performed on 4  $\mu\text{m}$  sections of formalin-fixed, paraffin-embedded tissues, using standard procedures. In this study, all tumors were of the large B-cell type.

## Results

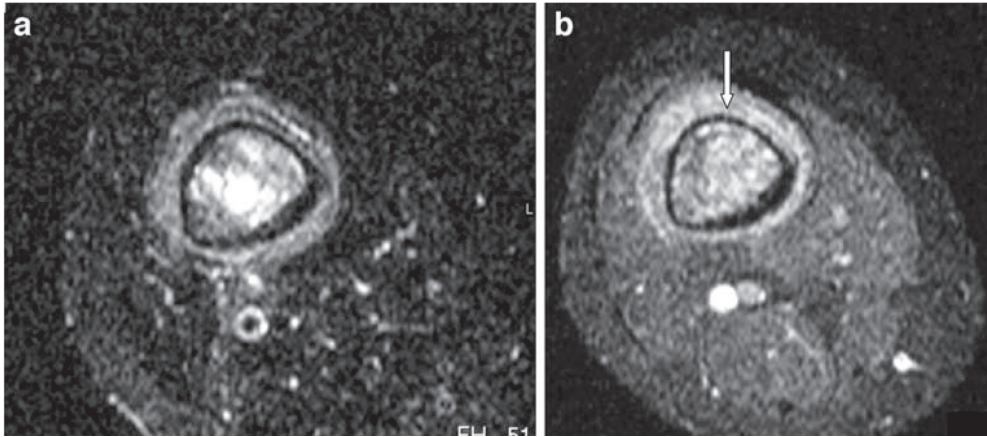
*Tumor size* The mean maximum tumor diameter was 11 cm (range 3–18 cm).

*Extension into the soft tissues* Tumor extension into the soft tissues was apparent in 22 of the 29 patients (Fig. 1) (76%), in three of these patients this was very discrete (Fig. 2). In the remaining seven patients (24%), the tumor was entirely confined to the intramedullary and/or cortical compartment (Fig. 3).

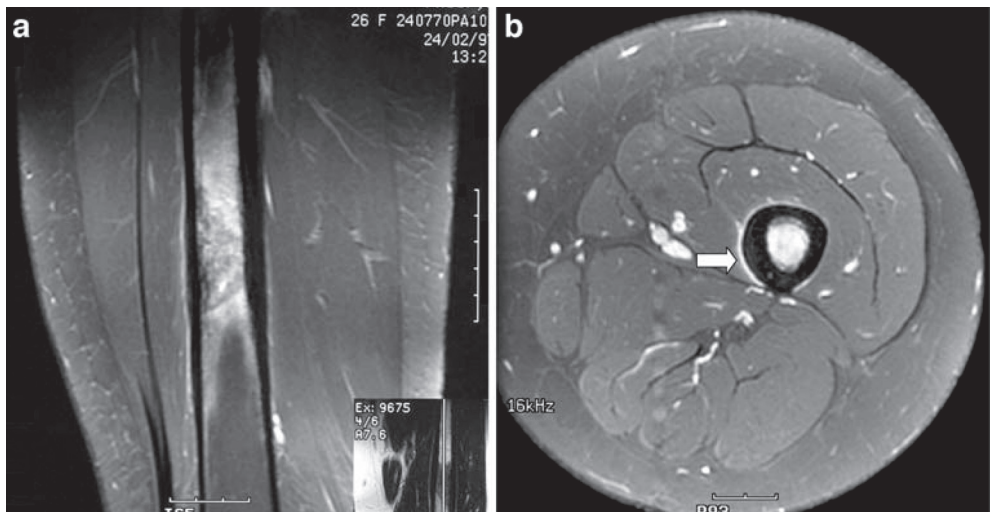
*Soft-tissue edema* Peri-lesional soft-tissue edema was encountered in approximately half of the patients (15 out of 29, 52%), whereas, in the other 14 patients, it was absent.



**Figure 1.** An 80-year-old male patient with primary nonHodgkin's lymphoma of the proximal humerus. Axial T1weighted turbo-spin echo (TSE) (TR/TE 575/15 ms) images before (a) and after (b) Gd-DTPA administration, the latter sequence with fat-selective presaturation. Intra-osseous tumor with circumferential substantial extension into the soft tissue. There is partly complete cortical disruption of cortical bone and otherwise permeative destruction shown as a fine linear pattern of abnormal increased cortical SI (a), even more conspicuous on contrast-enhanced images (b, arrow)

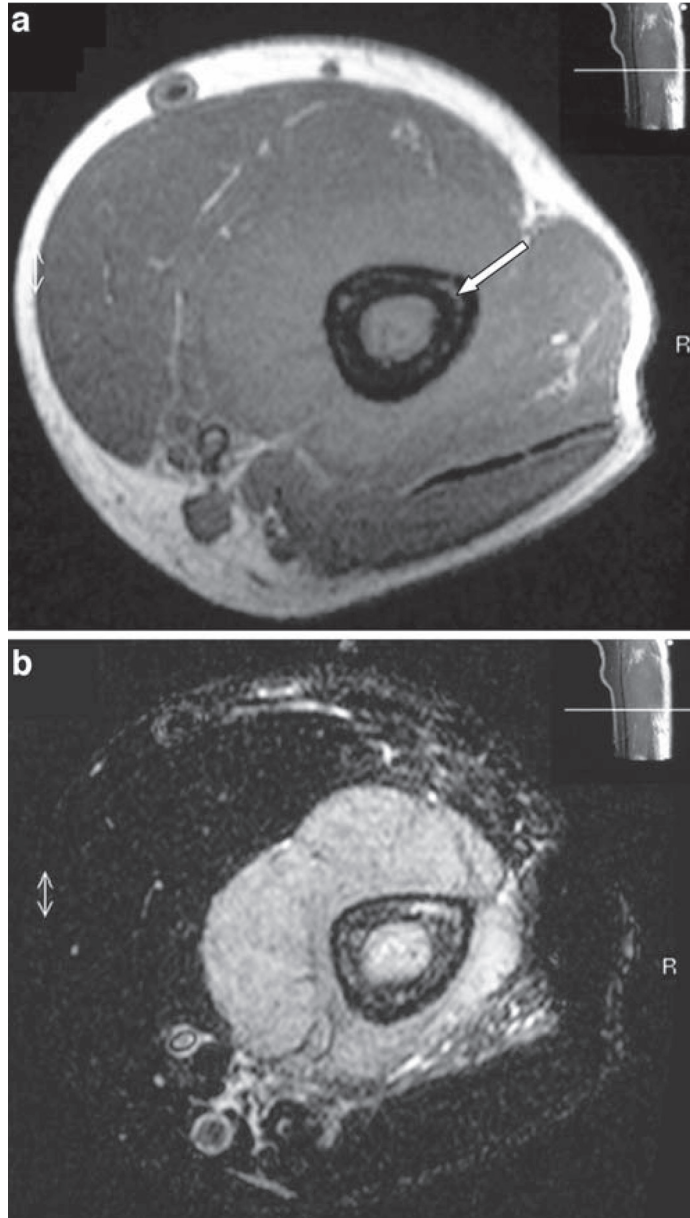


**Figure 2.** A 32-year-old female patient with primary non-Hodgkin's lymphoma of the distal femur diaphysis. Axial T2-weighted fat-suppressed turbo-spin echo (TSE) (TR/TE 3799/80 ms) image (a) and axial T1-weighted contrast-enhanced fat-suppressed TSE (TR/TE 500/15 ms) image (b). Heterogeneous high SI (a) of intraosseous component and limited circumferential soft-tissue cuff. Heterogeneous enhancement. Permeated cortical bone with linear intracortical, increased SI, particularly seen on Gd-enhanced images (b, arrow)



**Figure 3.** A 26-year-old female patient with primary nonHodgkin's lymphoma of the distal femur. Sagittal (a) and axial (b) T1-weighted contrast-enhanced fatsuppressed turbo-spin echo (TSE) (TR/TE 600/20 ms) images. There is inhomogeneous enhancement of the intraosseous tumor, with normal appearing cortical bone and, besides enhancing periosteum, no associated soft tissue mass

**Figure 4.** A 58-year-old male patient with primary non-Hodgkin's lymphoma of the distal humerus. Axial T1 turbo-spin echo (TSE) (TR/TE 504/13 ms) (a) and T2-weighted TSE (5,927/80 ms) image with fat-selective pre-saturation (b). Primary intra-osseous tumor with circumferential soft-tissue mass, homogeneously iso-intense on T1 and high on T2-weighted sequences. Normal cortical thickness with discrete signal abnormalities on T1 (a, arrow), more conspicuous on T2-weighted sequences (b)



*Signal intensities of soft-tissue part* Appearance on T1weighted sequences could be assessed for 21 patients bearing tumors with extension into the soft-tissues: in 19 (90%) of these 21 patients the SI was intermediate and equal to that of muscle. In two patients the SI was higher than for muscle. In 22 patients the SI on T2-weighted sequences could be assessed, being high (higher than that of muscle, lower than that of fat) in 20 patients (91%). This high signal was predominantly homogeneous in 18 of those 20 patients and heterogeneous in the other four.

*Enhancement of soft-tissue part* Enhancement of the soft-tissue component of the tumor could be determined in 17 patients; for the other 12 patients contrast-enhanced studies were not available. Enhancement of the soft-tissue part occurred in all evaluable patients, being predominantly homogeneous and diffuse in 14 (82%) patients and heterogeneous in the other three patients (Fig. 1).

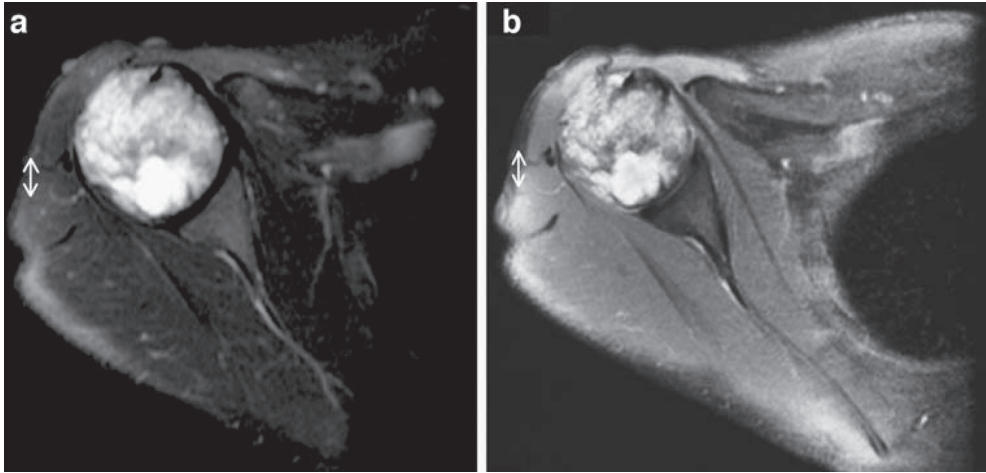
*Cortical bone destruction* For two of the 29 patients the entire cortical bone was scored as normal. In those two patients there was also no extension into soft-tissue (Fig. 3). In 27 patients (93%) the cortical bone was abnormal. A permeative cortical destruction pattern was noticed for a small majority of patients (15 of 29, 52%). In ten of these 15 patients, an associated soft-tissue mass was apparent (Fig. 4); however, in two patients, this was absent. In the remaining three patients only limited extra-cortical abnormalities were present (Fig. 2). Complete cortical disruption was found in eight patients (Fig. 1) (28%). All but one of these eight patients had significant extension into the soft-tissue. Focal destruction was seen in two patients, and homogeneous cortical thickening in one patient. Moreover, selective intracortical tumor localization was encountered in one other patient.

*Bone marrow involvement* Signal intensity of the intraosseous tumor component on T1-weighted images could be assessed in 26 patients being predominantly intermediate (equal to muscle) in 25 patients (Figs. 1, 4) and predominantly low (lower than muscle) in one patient. In three patients (12%) of the former group, a combination of intermediate and low signal intensity was found. Demarcation in the longitudinal extent was scored as sharp in 11 and shaded in nine patients. On T2-weighted images (available in 28 patients) the SI of the bone marrow compartment was high in 25 patients (89%), intermediate in two patients (7%) and low in one patient. The SI of the bone marrow tumor component was homogeneous in 13 of 28 patients (46%), however, inhomogeneous in 15 patients (54%). (Figs. 2, 5).

*Enhancement of bone marrow component* Enhancement of the bone marrow tumor component could be assessed in 23 patients. No enhancement was noticed in only one patient. The other 22 patients showed enhancement, which was homogeneous in nine patients (41%), and heterogeneous in 13 patients (59%) (Figs. 2, 3, 5).

## Discussion

Primary non-Hodgkin's lymphoma of bone (PLB) is a rare entity among musculoskeletal tumors, and it is also uncommon among extra-nodal sites of NHL. The morphology of these lymphomas is identical to that of lymphomas at other sites, but the clinical course is often more protracted. Prognosis of PLB depends mainly on staging and on histological classification, but, generally, the clinical outcome, after treatment with combined chemo- and radiation therapy, is favorable, with a 5-year overall survival rate rising to 88% [1–5, 9–11, 18, 20]. On the other hand, Lewis et al. reported a 5-year survival rate of 58% and no statistically significant difference between PLB and systemic bone lymphoma [6]. With regard to histological subtype, tumor localization and clinical presentation, patients with PLB display homogeneous clinicopathological features



**Figure 5.** A 29-year-old male patient with non-Hodgkin's lymphoma of the proximal humerus. Axial T1-weighted contrast-enhanced (TR/TE 550/12 ms) (a) and T2-weighted (b) turbo-spin echo (TSE) (TR/TE 3,021/80 ms) images with fat-selective pre-saturation. Intra-osseous tumor localization with no extension into soft-tissue and heterogeneous high SI on both sequences.

[4, 5]. Almost all tumors are localized in long bones (particularly the femur, tibia, pelvis and humerus), and patients present with pain and/or a palpable mass. The literature describes a significant male preponderance, which is not confirmed in this present study. Although PLB presents in a wide age range of patients, evenly distributed among the second through eighth decades of life, in general, it is more frequently encountered in patients over 30 years of age, with a peak incidence in the fifth decade, in contrast to that of Ewing's sarcoma and osteosarcoma [6, 8, 10, 11, 13, 14, 18]. In the latter patient group, a significant decrease in incidence is found beyond the third decade. In our study group of 29 patients a broad range of ages at presentation was also found (19–81 years); the median age was 40 years.

Plain radiographs of PLB often show destructive bone lesions, generally with periosteal layering and cortical disruption. On the other hand, plain radiographs of PLB may appear virtually normal or non-specific and can be overlooked as being normal. As such, there is no specific conventional radiographic pattern, and the radiographic differential diagnosis of PLB includes a broad spectrum of both benign (including osteomyelitis) and malignant (such as osteosarcoma, Ewing's sarcoma) lesions [8, 16-19]. These tumors and tumor-like lesions may demonstrate similar radiographic features but warrant different types of therapy. In this respect PLB is associated with a better prognostic outcome than that for other small round cell tumors. Literature on the presentation of MR imaging features of PLB is relatively scarce and contradictory. These studies, frequently with limited numbers of patients, mainly focused on the appearance of the cortical bone, relative to associated soft-tissue abnormalities, and on SI characteristics [13-16, 18, 19, 21, 22]. Low SI on T2-weighted sequences has been mentioned as a feature of PLB, probably due to a high content of fibrous tissue [15]. We could not confirm

this feature to a great extent in our population. Low SI on T1-or T2-weighted sequences was present in only one patient each. Almost all tumors showed a non-specific combination of intermediate (equal to that of muscle) SI on T1-weighted sequences and high SI on T2weighted sequences.

Several studies on PLB and MR imaging focused on the pattern of cortical destruction in order to use it as a differentiating criterion. It was stated that a tumor with a normal (appearing) cortex and a substantial soft-tissue mass is likely to be lymphoma [13, 14]. MR imaging may show small linear foci of intermediate or high SI on T2-weighted sequences, penetrating the cortical bone. This MR pattern of permeative cortical destruction is, however, not specific to lymphoma. It can be seen in other small round cell tumors (in the younger age group) as well as in different metabolic and inflammatory processes, including hyperparathyroidism and osteomyelitis and, for instance, myeloma or metastatic carcinoma (in the older age group) [13, 14]. In our study, cortical abnormalities were present in 93% of patients, and extension into the soft tissue was found in 76%, but various types of destruction and combinations with or without such extension were recognized (Table 1). A pattern of permeative cortical destruction with linear foci of abnormal SI was noticed in 15 of the 29 (52%) patients. Ten of these 15 patients had a definite soft-tissue mass. In five patients, however, this was minimal or even absent. In 28% of our patient population complete cortical disruption could be appreciated; in all but one patient it was accompanied by a large soft-tissue mass. In another two patients, the cortical bone appeared to be completely normal, and in these patients there was no associated softtissue mass. In one patient with histologically confirmed PLB the tumor was selectively located within the cortical bone, without further extension into the soft tissue and/or bone marrow involvement. In one patient the cortical bone was homogeneously thickened, a feature that can also be encountered in reactive processes (after trauma or infection). Peri-osteal or cortical lymphoma without medullary involvement is a very rare manifestation of NHL, but it has been previously described [23]. In this respect, it can be concluded that in patients with PLB the pattern of cortical destruction is heterogeneous and non-specific.

MR imaging is the optimal modality to demonstrate the extent of bone marrow replacement by PLB, particularly using T1-weighted sequences [14, 24]. Multi-centric bone marrow disease is likely to be detected by longitudinal series with a large field of view. Signal intensities of the bone marrow component were non-specific in the present series, being intermediate on T1-weighted sequences and high on T2-weighted sequences in almost all patients. In only three patients a combination of intermediate and low signal intensity was found. Demarcation in the longitudinal extent was scored as sharp in 11 and unsharp in nine patients. The SI of the bone marrow tumor component was homogeneous in 13 of 28 patients (46%); however, it was inhomogeneous in 15 patients (54%), which can be explained by the intermingling of normal bone marrow between areas of tumor. Contrast-enhanced images of the bone marrow showed a similar distribution; enhancement was diffuse and homogeneous in 41% and heterogeneous in 59% of the patients whose condition was eligible for evaluation. Opposed to the bone marrow component, the soft-tissue component, if present, was far more homoge-

**Table 1.** Relationship between MR imaging appearance of cortical bone and extension into the soft tissue in 29 patients with PLB

Cortex appearance	Extension into soft-tissue substantial	Extension into soft-tissue limited	Extension into soft-tissue absent	Total
Normal	0	0	2	2
Permeative destruction	10	3	2	15
Focal disruption	2	0	0	2
Complete disruption	7	0	1	8
Cortex thickening	0	0	1	1
Tumor within cortex only	0	0	1	1
Total	19	3	7	29

neous, both on T1-weighted contrast-enhanced images (82%) and as high SI on T2-weighted images (82%).

The data obtained in this retrospective study demonstrate that, in contrast to the relatively homogeneous clinical and pathological presentation, the MR imaging features are not uniform in patients with PLB. Although the majority of our patients displayed a combination of definite cortical abnormalities (either permeative destruction or complete disruption) and extension into soft-tissue, lymphoma may show different appearances. Particularly, intra-osseous lesions with linear cortical signal abnormalities without substantial soft-tissue mass, or even normal-appearing or thickened cortical bone without soft-tissue mass, may look nonaggressive and even benign. In the present study no fewer than nine of 29 patients (31%) with PLB presented in that manner. Radiologists should thus be aware of that in the right clinical context.

There are several limitations concerning this retrospective and largely descriptive study. The data obtained were collected from various institutions that had used different MR imaging systems, field strengths and protocols. In order to collect a larger number of patients, given the rarity of PLB, we could not avoid this. The assessment of heterogeneity or homogeneity of signal characteristics is quite subjective; however, for the goal of this study it was of minor importance. Fast dynamic contrast-enhanced sequences were used only incidentally. Nowadays, these acquisitions are widely used to assess the biologic behavior of primary bone and soft-tissue tumors and to determine the response to chemo-and/or radiation therapy. With regard to PLB, the rapid decrease of tumor volume and the complete disappearance of the soft-tissue component on MR imaging has been described as a significant indicator of good response to treatment [24]. In this respect, MR imaging has a direct impact on individual patient care, which is however, outside the scope of this study. We could not determine how MR imaging had caused any change in clinical approach in the patients with PLB described here. Differentiating PLB from other malignant small round cell tumors, on the one hand, or reactive processes, on the other hand, based on (MR) imaging criteria only, is, in our opinion, not possible and not useful, which stresses the need for accurate core biopsy, which is definitely crucial for both diagnosis and staging purposes.

## References

1. Huvos AG. Skeletal manifestations of malignant lymphomas and leukemias. In: Bone tumors: diagnosis, treatment, and prognosis. Philadelphia: Saunders; 1979.
2. Mulder JD, Kroon HM, Schutte HE, Taconis WK. Non-Hodgkin's lymphoma. In: Radiologic atlas of bone tumors. Amsterdam, The Netherlands: Elsevier; 1993.
3. Mirra JM, Picci P, Gold RH. Skeletal manifestations of malignant lymphomas and leukemias. In: Bone tumors: clinical, radiologic and pathologic correlations. Philadelphia, PA: Lea and Febiger; 1989.
4. Fletcher CD, Unni KK, Merlens F. WHO classification of tumours. Pathology and genetics of tumours of soft tissue and bone. Lyon: IARC press; 2002.
5. Heyning FH, Hogendoorn PCW, Kramer MHH, et al. Primary non-Hodgkin's lymphoma of bone: a clinicopathologic investigation of 60 cases. *Leukemia* 1999; 13: 2094–2098.
6. Lewis V, Primus G, Anastasi J, et al. Oncologic outcomes of primary lymphoma of bone in adults. *Clin Orthop Relat Res* 2003;
7. Barbieri E, Cammelli S, Mauro F, et al. Primary non-Hodgkin's lymphoma of the bone: treatment and analysis of prognostic factors for stage I and stage II. *Int J Radiat Oncol Biol Phys* 2004;
8. de Camargo O, dos Santos Machado T, Croci A, et al. Primary bone lymphoma in 24 patients treated between 1955 and 1999. *Clin Orthop Relat Res* 2002; 397: 271–280.
9. Vasallo J, Roessner A, Vollmer E, Grundmann E. Malignant lymphomas with primary bone manifestation. *Pathol Res Pract* 1987; 182: 381–389.
10. Baar J, Burkes RL, Bell R, Blackstein ME, Fernandes B, Langer F. Primary non-Hodgkin's lymphoma of bone. A clinicopathologic study. *Cancer* 1994; 73: 1194–1199.
11. Beal K, Allen L, Yahalom J. Primary lymphoma of bone: treatment results and prognostic factors with long-term follow-up of 82 patients. *Cancer* 2006; 106: 2652–2656.
13. Mulligan ME, McRae GA, Murphey MD. Imaging features of primary lymphoma of bone. *AJR Am J Roentgenol* 1999; 173: 1691–1697.
14. Krishnan A, Shirkhoda A, Tehranzadeh J, Armin AR, Irwin R, Les K. Primary bone lymphoma: radiographic–MR imaging correlation. *Radiographics* 2003; 23: 1371–1383.
15. Stiglbauer R, Augustin I, Kramer J, Schurawitzki H, Imhof H, Radaszkiewicz. MRI in the diagnosis of primary lymphoma of bone: correlation with histopathology. *J Comput Assist Tomogr* 1992; 16: 248–253.
16. Hicks DG, Gokan T, O'Keefe RJ, et al. Primary lymphoma of bone; correlation of magnetic resonance imaging features with cytokine production by tumor cells. *Cancer* 1995; 75: 973–980.
17. Mendenhall NP, Jones, Kramer BS, et al. The management of primary lymphoma of bone. *Radiother Oncol* 1987; 9: 137–145.
18. Manaster BJ. Primary bone lymphoma: radiographic-MR imaging correlation. Invited commentary. *Radiographics* 2003; 23: 1384– 1386.
19. Clayton F, Butler JJ, Ayala A, Ro JY, Zornoza J. Non-Hodgkin's lymphoma in bone: pathologic and radiologic features with clinical correlates. *Cancer* 1987; 60: 2494–2501.
20. Yuste A, Segura A, Lopez-Tendero P, Girones R, Montalar J, Gomez-Codina J. Primary lymphoma of bone: a clinico-pathologic review and analysis of prognostic factors. *Leuk Lymphoma* 2004;
21. Haussler MD, Fenstermacher MJ, Johnston DA, Harle TS. MRI of primary lymphoma of bone: cortical disorder as a criterion for differential diagnosis. *J Magn Reson Imaging* 1999; 9: 93–100.
22. Salter M, Sollacio RJ, Bernreuter WK, Weppelmann B. Primary lymphoma of bone: the use of MRI in pretreatment evaluation. *Am J Clin Oncol* 1989; 12: 101–105.



23. Campbell S, Filzen T, Bezzant S, et al. Primary periosteal lymphoma: an unusual presentation of NHL. *Skeletal Radiol* 2003; 32: 231–235.
24. Mengiardi B, Honegger H, Hodler J, Exner U, Csherhati M, Bruhlmann W. Primary lymphoma of bone: MRI and CT characteristics during and after successful treatment. *AJR Am J Roentgenol* 2005; 184: 185–192.



# Chapter 4

## **Primary Lymphoma of Bone: Extranodal Lymphoma with Favourable Survival Independent of Germinal Centre, Post Germinal Centre, or Indeterminate Phenotype**

E.H. Heyning<sup>1</sup>, P.C.W. Hogendoorn<sup>2</sup>, M.H.H. Kramer<sup>3</sup>, C.T.Q. Holland<sup>2</sup>, E. Dreef<sup>2</sup>, P.M. Jansen<sup>2</sup>

<sup>1</sup>Department of Internal Medicine, Medical Center Haaglanden, the Hague, <sup>2</sup>Department of Pathology, Leiden University Medical Center, Leiden, and <sup>3</sup>Department of Internal Medicine, Free University Medical Center, Amsterdam, The Netherlands

*Journal of Clinical Pathology*, 2009; 62: 820-824

## Abstract

**Aims:** To determine prognostic significance of immunohistochemical markers and investigate possible germinal centre (GC) derivation in primary lymphoma of bone (PLB).

**Methods:** In this study we have investigated the immunohistochemical expression of BCL-6, CD10, BCL-2, p53, CD30 and CD44 and MUM-1 in thirty-six patients with PLB. All cases were clinically staged and cases of secondary bone involvement of primary nodal lymphomas were excluded, prior to immunostaining. Clinical charts were reviewed for clinical symptoms and therapy given and survival post-biopsy was calculated.

**Results:** All patients presented with pain and a palpable mass. The majority showed centroblastic-multilobated morphology, half of the cases (19/36) displayed a GC phenotype (CD10+BCL-6+ or CD10-BCL-6+MUM-1-), whereas 8/36 cases demonstrated a non-GC phenotype (CD10-BCL-6- or CD10-BCL-6+ MUM-1+). Nine cases were of indeterminate phenotype (CD10-BCL-6+; MUM-1 not available). Eight out of 22 evaluated patient samples showed immunoreactivity for MUM-1. Most patients (31/36) received combination therapy in the form of polychemotherapy and radiotherapy. The 5-year overall survival was 75%. No significant difference in survival was found between the three different tumour phenotypes, or for the tested antigens individually. Age at presentation and stage of disease were of significant influence on 5-year overall survival. Survival rates were 90% for the patients under 60 years of age and 40% for those of 60 years and older. Furthermore, survival rates were 90% for stage I vs. 41% for stage IV, respectively.

**Conclusion:** This study illustrates the homogeneity of PLB. The majority of cases is of the GC phenotype and has a favourable prognosis.

## Introduction

Primary non-Hodgkin lymphoma of bone (PLB) is a rare neoplastic disorder, comprising 5% of extranodal lymphomas and less than 1% of all non-Hodgkin lymphomas.[1] It is an extranodal subtype of mostly diffuse large B cell lymphoma (DLBCL), which is a heterogeneous group of lymphomas.

Studies on extranodal lymphomas are rare, even though the incidence of extranodal lymphoma in Western countries has increased in the last 40 years.

Immunohistochemical studies on PLB are even rarer, likely because of the limited availability of tissue specimens of this disorder and technological difficulties in handling osseous tumour material.

PLB has morphological homogeneity and a relatively favourable clinical behaviour with a 5-year overall survival of 90% for stage I disease, as published in our previous report.[2,3]

In the last decade, insight into B-cell development and lymphoma pathogenesis has increased substantially due to the increasing availability of well-defined histogenetic markers. These include the expression of BCL-6 and CD10 protein, which are considered germinal centre (GC) markers, and of MUM1/IRF4, which denotes the final step of intra-GC B-cell differentiation, as well as subsequent steps of B-cell maturation towards plasma cells.[4] The expression of the anti-apoptotic factor BCL-2 and of the surface adhesion molecule CD44 is normally down-regulated in GC B-cells.[5,6] Moreover, genotypic analyses have revealed several structural and numerical chromosomal changes in DLBCL, including translocations t(14;18)(q32;q21) and t(3;14)(q27;q32) that involve BCL-2 and BCL-6 genes, respectively. In numerous studies on DLBCL the effect of these chromosomal changes on prognosis has been debated, but a final conclusion cannot be drawn.[7-9]

Research in gene expression profiling has led to the concept that most DLBCL derive from GC B-cells or from their descendants, i.e. activated B-cells or non-GC B-cells.[10] Since most PLB have a centroblastic phenotype, it has been postulated that PLB represents a de novo DLBCL with a genetic relationship to GC B-cells.[11]

Recent studies have analyzed the expression of GC B-cell-associated antigens and other markers in PLB, showing that at least part of the patients with PLB have a GC signature, which was associated with a favourable clinical outcome.[7,11,12]

In the current study, immunohistochemical staining for BCL-6, CD10, BCL-2, MUM-1, p53, CD30 and CD44 was performed in 36 PLB patients to determine both possible GC origin of these lymphomas as well as the prognostic significance of these markers.

## Material and Methods

### Patient Selection

In this study we included the previously described cohort of patients combined with newly registered cases from 1995 until 2001.[2] This new cohort consisted of 83 cases. PLB was defined as a histologically proven non-Hodgkin lymphoma arising within the medullary cavity of a bone, with or without regional lymph node involvement, but without evidence of other extranodal involvement. Multiple bone lesions were acceptable as long as there was no evidence of earlier lymphoma involvement elsewhere. All cases selected were clinicopathologically reviewed independently by two pathologists, if needed with application of additional immunohistochemical stainings to confirm the diagnosis. Of the originally identified group of 106 patients 30 patients were excluded because of a different diagnosis after review of the histological slides, combined with new immunohistochemical data or clinical follow-up as described in our previous study. Clinical follow-up was updated. Adequate paraffin material for additional immunohistochemical studies was available in 36 cases, of which 14 cases were not described in our previous study.

### Histological Classification and Immunohistochemistry (table 1)

The pathological diagnosis was established according to the WHO classification [13] using standard histological criteria and immunohistochemistry using antibodies directed against Vimentin, CD45, CD3, CD20, CD79a, and CD99. Immunohistochemical staining was performed on 4  $\mu$ m sections of formalin-fixed, paraffin-embedded tissues, using standard procedures as detailed elsewhere.[2] In addition to the diagnostic marker panel listed above a set of markers relevant to a GC/non-GC phenotype or relevant to survival was used. The details of the antibodies are given in table 1.

### Immunohistochemical Scoring

Two pathologists assessed all cases independently. Three categories were defined: negative, 30-75% positivity or >75% positivity, reflecting the percentage of positive tumour cells.

### Statistical Methods

Survival curves were plotted following the Kaplan-Meier method and tested for statistical significance using the log-rank test. Overall survival (OS) was calculated from the date of diagnosis until death (all causes) or last-follow-up. The multivariate Wilson regression test was used to determine statistic significance of the parameters independent of the known IPI risk factors age and tumour stage.

**Table 1.** Antibodies Used for Immunohistochemistry

Marker	Clone	Producer	Type	Isotype
BCL-2	124	Dako	Mouse	IgG1
BCL-6	PG-B6P	Dako	Mouse	IgG-k
CD-3		Dako	Rabbit	Polyclonal
CD10	56C6	Neomarkers	Mouse	IgG1
CD20	L26	Dako	Mouse	IgG2a-k
CD30	BER-H2	Dako	Mouse	IgG1
CD44	156-3C11	Neomarkers	Mouse	IgG1-k
CD45	CLA	Neomarkers	Mouse	IgG1-k
P53	DO-7	Neomarkers	Mouse	IgG2b-k
CD79a	JCB117	Dako	Mouse	IgG1-k
CD99	O13	Zymed	Mouse	IgG1
MUM-1	MUM-1p	Dako	Mouse	IgG1

## Results

### Clinical Features (table 2)

A group of 36 patients with PLB was studied. All the patients presented with pain and/or a palpable mass, most often at a single location in one of the long bones.

Multifocal bone involvement (scored as stage IV) was noted in 10 cases. Twelve out of all 36 patients had undergone an incomplete staging procedure, according to the present standards. All stage IV patients had more than one bone localization and none had iliac crest bone marrow involvement.

The male:female ratio was 26:10. The mean age at presentation was 48 years, ranging from 18 years to 79 years. Clinical findings, including age, gender, primary location of tumour, treatment and outcome are summarized in table 2.

The IPI index could be calculated in 26 of the 36 cases. If unknown, this was mostly due to lacking laboratory results. The mean score was 2. The 5-year overall survival of this cohort was 75%. Most patients (31) received combination therapy in the form of poly-chemotherapy or surgical resection with radiotherapy. All chemotherapy courses were given with curative intentions. It consisted of cyclophosphamide, doxorubicin, vincristin, prednisone (CHOP) (16x), or CHOP-like: cyclophosphamide, teniposide, doxorubicin, vincristin, bleomycin, prednisone (CHVmP/BV) (8x) and prednisone, methotrexate, doxorubicin, cyclophosphamide, epipodophyllotoxin VP-16 (PROMACE) (5x).

Twenty-nine patients (80%) demonstrated a complete remission, including one spontaneous remission. The latter was reviewed on multiple occasions by different pathologists and haematologists, with the original diagnosis confirmed each time. To our knowledge this is the first case of PLB with a spontaneous remission mentioned in a study. Follow-up was available in all but one case. The median follow-up was 79 months. Four patients had progressive disease and died of disease. One patient had no change of disease and died during therapy.

**Table 2.** Clinical Characteristics of the Patient Population Studied

Patient	Sex	Age	Primary Location	Multifocal Disease	Therapy	Result	Relapse
1	M	59	Clavicle		RT + SUR	4	
2	F	61	Humerus		RT + SUR	4	
3	M	50	Femur		RT + SUR	1	
4	M	59	Femur	IV	RT + SUR	4	
5	F	53	Femur		RT + SUR + CHOP-like	1	
6	F	41	Femur		RT + CHOP	1	
7	M	54	Scapula + Humerus		RT + SUR + CHOP-like	1	
8	M	23	Shoulder		RT + CHOP-like	1	
9	M	28	Clavicle		RT + CHOP	1	
10	M	69	Femur		RT + SUR + CHOP	1	
11	M	18	Vertebral Column		RT + SUR + CHOP-like	1	
12	M	30	Femur	IV	Unknown	9	
13	M	65	Humerus		RT + CHOP-like	1	
14	F	38	Hipjoint	IV	None	1	
15	M	40	Femur		CHOP	1	
16	M	20	Femur		RT + CHOP	1	
17	M	23	Femur		RT + SUR	1	
18	F	18	Femur		RT + CHOP	1	
19	M	61	Os Pelvis		RT + SUR + CHOP-like	9	
20	M	30	Femur	IV	RT + CHOP	1	28 months
21	F	23	Scapula		RT + SUR + CHOP-like	1	
22	M	31	Femur		RT + CHOP-like	1	
23	M	72	Humerus	IV	RT + CHOP	1	
24	F	51	Vertebral Column	IV	RT + CHOP	1	
25	M	58	Humerus		RT + CHOP-like	1	
26	F	52	Os Pubis		RT + CHOP-like	1	
27	M	27	Femur		RT + CHOP-like	1	
28	M	79	Humerus	IV	RT + SUR + CHOP	4	
29	M	46	Femur		RT + SUR + CHOP	1	
30	M	51	Hipjoint		CHOP	1	
31	F	78	Femur	IV	CHOP	1	
32	F	71	Femur	IV	RT + SUR + CHOP	1	
33	M	29	Humerus		RT + CHOP	1	
34	M	72	Os Ilium		RT + CHOP-like	1	
35	M	75	Femur	IV	SUR + CHOP	3	
36	M	46	Humerus		RT + CHOP-like	1	

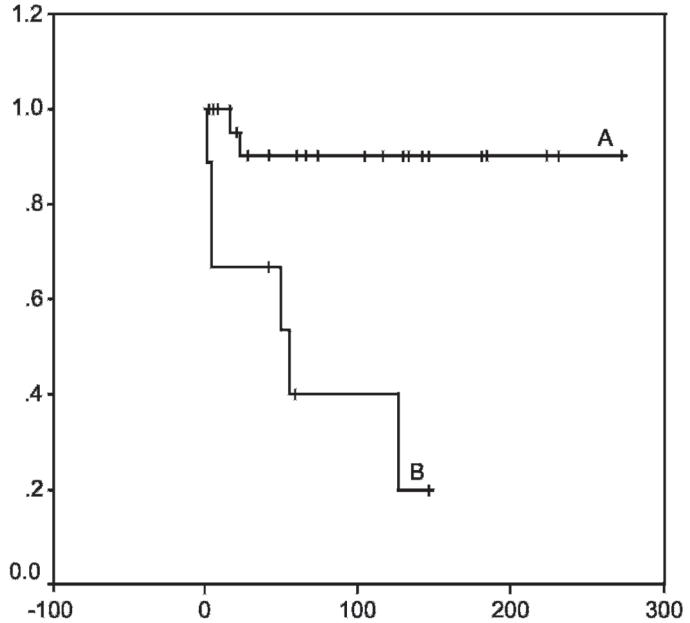
1 Ann Arbor stage; Stage IV is Multifocal

2 RT: radiotherapy; SUR: surgery; CHOP and CHOP-like: chemotherapy

3 1: complete remission; 3: no change; 4: progressive disease; 9: no evaluation possible

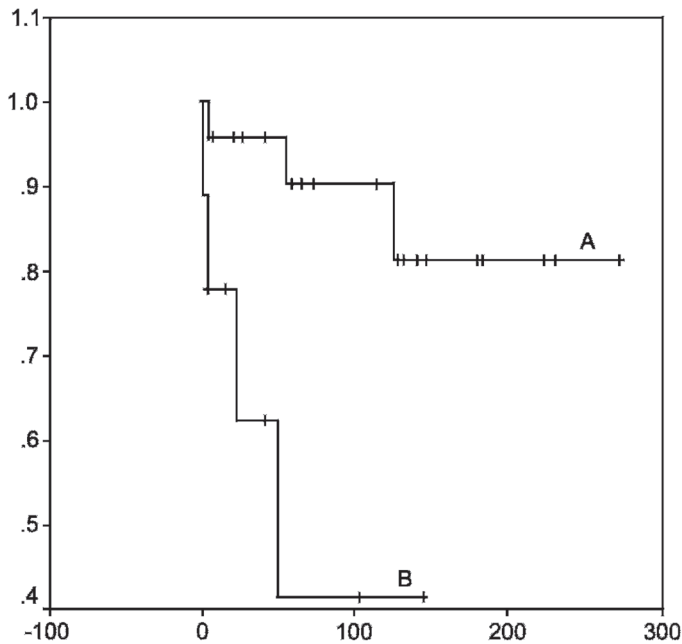


**Figure 1.** Kaplan-Meier overall survival curve of age at diagnosis ( $p=0.0004$ )  
**A:** survival % (in months) of patients of 60 years and younger  
**B:** survival % (in months) of patients above 60 years of age



One patient experienced a nodal relapse at 28 months, with complete remission after second-line chemotherapy and no evidence of disease at 118 months.

There was a significant association between the IPI index factors age and stage of disease and survival. The overall 5-year survival for the patients under 60 years at the time of diagnosis



**Figure 2.** Kaplan-Meier overall survival curve of stage of disease ( $p=0.0085$ )  
**A:** survival % (in months) of stage I patients  
**B:** survival % (in months) of stage IV patients

**Table 3.** Selection of Histological and Immunohistochemical Features

Patient	Morphology	CD10	BCL-6	MUM-1	Phenotype	BCL-2	P53	CD30	CD44
1	Centro-multi	-	-	-	Non-GC	-	-	-	++
2	Diff centro	-	+	+	Non-GC	++	++	-	++
3	Diff centro	+	+		GC	-	+	-	++
4	Diff centro	-	+		Indet	+	-	-	++
5	Diff centro	++	++		GC	-	-	-	-
6	Centro-multi	++	+	-	GC	-	-	-	+
7	Diff centro	-	+		Indet	++	-	-	++
8	Centro-multi	-	+		Indet	-		++	-
9	Centro-multi	-	+	-	GC	-	-	++	-
10	Diff centro	-	-	+	Non-GC	++	+	-	++
11	Centro-multi	+	++		GC	-	+	-	+
12	Centro-multi	-	+	-	GC	-	+	-	+
13	Diff centro	+	-	-	GC	-	-	++	++
14	Diff centro	-	+		Indet	-	+	-	+
15	Centro-multi	-	+		Indet	-	+	-	-
16	Diff centro	-	+		Indet	-	+	-	+
17	Centro-multi	-	-		Non-GC	-	+	-	++
18	Diff centro	+	++	+	GC	-	+	-	++
19	Centroblastic	-	+	-	GC	-		-	-
20	Immunobl	-	++	+	Non-GC	++	-	-	-
21	Centro-multi	++	++	-	GC	-	+	-	++
22	Centro-multi	-	-	-	Non-GC	-	-	-	++
23	Centro-multi	++	+		GC	++	+	-	++
24	Centro-multi	+	-		GC	++	-	-	++
25	Centro-multi	-	+	-	GC	-	-	++	++
26	Centro-multi	-			Indet	++	-	-	++
27	Centro-multi	-	++	-	GC	-	+	-	-
28	Diff centro	++	+	+	GC	++	-	++	++
29	Centroblastic	-	-	+	Non-GC	++	-	-	++
30	Diff centro	-	++		Indet	++	-	++	++
31	Diff centro	++	+	+	GC	-	++	-	++
32	Centro-multi	-	++	-	Indet	-	+	++	+
33	Centro-multi	-	+	-	GC	-	-	-	++
34	Centro-multi	-	+	+	Non-GC	-	++	-	++
35	Centro-multi	++	+	-	GC	++	-	-	+
36	Centro-multi	+	++	-	GC	-	-	-	++

-: no staining

+: 30 to 75% of the tumour cells positive staining

++: more than 75% of the tumour cells positive staining

(n=26) was 90%, versus 40% for those patients who were over 60 years of age at the time of diagnosis (n=10; p-value=0.0004) (figure 1). The patients who presented with multiple bone lesions (n=10) at the time of diagnosis had a significantly worse survival than those who presented with a lymphoma at a single location (n=26), the overall 5-year survival being 41% versus 90%, respectively (p-value=0.0085) (figure 2).

### **Histological and Immunohistochemical Features (table 3)**

The histological and immunohistochemical findings are summarized in table 3. Although not recognized anymore as separate tumour entities in the present WHO, a morphological subclassification was performed in order to establish whether a specific morphology was apparent. Twenty cases demonstrated centroblastic-multilobated morphology, 13 cases showed centroblastic mono- or polymorphic morphology, two cases showed centroblastic-centrocytic morphology and one case demonstrated immunoblastic morphology. No prognostic significant difference in survival between the morphological tumour subtypes was found, nor did we find a difference in morphological subtype between the stage I and IV patients.

Nuclear expression of BCL-6 was seen in 28 cases. BCL-2 expression was demonstrated in 12 cases, 8 cases showed both BCL-2 and BCL-6 expression. CD10 expression was seen in 13 cases. MUM-1 expression was found in 8 out of 22 cases which could be evaluated. P53 expression was found in 16 cases. CD30 expression was seen in 7 cases, CD44 expression was seen in 29 cases.

Applying the Hans' algorithm, GC phenotype was defined as CD10+BCL-6+, non-GC phenotype was defined as CD10-BCL-6-. In case of CD10-BCL-6+, MUM-1 expression was determined. [14] If MUM-1 was negative, the phenotype was defined as GC, if MUM-1 expression was positive, the case was defined as non-GC. If MUM-1 expression was unavailable, the phenotype was defined as indeterminate. Nineteen out of 36 patients revealed a GC phenotype. Tumours that were negative for both CD10 and BCL-6, the non-GC phenotype, were seen in 8 cases. The phenotype was defined as indeterminate in 9 cases.

There was no significant difference in survival between the different tumour phenotypes. None of the other antigens tested had a significant association with survival.

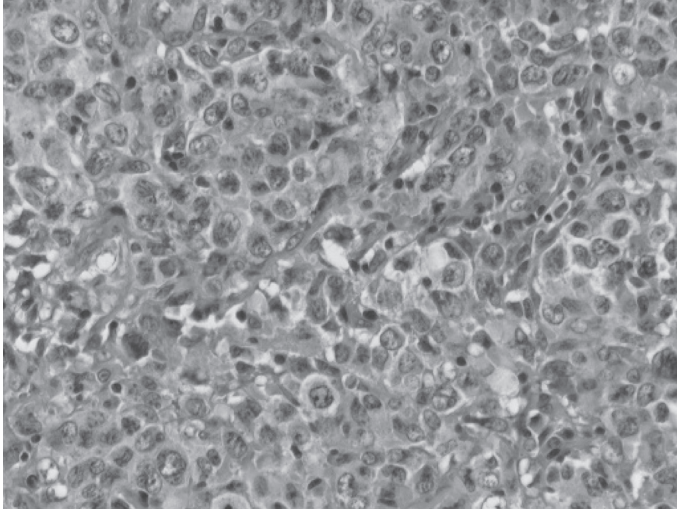
## **Discussion**

Our study of PLB investigated immunohistochemical expression of BCL-6, CD10, BCL-2, MUM-1, p53, CD30 and CD44 to analyse the prognostic significance of these markers and to determine GC derivation.

Patients displayed homogeneous clinical features, consistent with the few other reports on PLB in literature, but not earlier was the homogeneity as strong as in the present cohort. [2,12,15-19]

Similar to other series the presenting symptom in all patients was pain, usually combined with a palpable mass; the site of presentation was mostly in the long bones and the age at presentation was in the fifth decade. The histology was consistently compatible with DLBCL and displayed predominantly a centroblastic morphology with multilobated nuclei.

The PLB patients had a good prognosis, with a complete remission rate of 80% and an overall survival of 75%. Only one patient suffered a relapse, which was followed by complete remission. Our series included 10 cases of stage IV disease with multiple bone localizations, with a 5-year overall survival of 41%, whereas most prior studies excluded patients with multiple



**Figure 3.** A typical case of primary lymphoma of bone showing centroblastic cells with nuclear multilobated features.

bone involvement, which leads to an imperfect representation of the spectrum of this disease.

Two IPI risk factors, age at presentation and stage of disease, were of significant influence on 5-year overall survival, with a survival rate of 90% for the patients under 60, and 40% for those of 60 years and older. Survival rates were 90% for stage I vs 41% for stage IV, respectively.

In recent studies, the relationship of B-cell malignancies to normal stages of B-cell differentiation and activation has been partly clarified using genomic scale gene expression profiling. These molecular distinctions between subgroups of DLBCL are important because a difference in response to multi-agent chemotherapy is noted between these subgroups, with a favourable outcome for the GC phenotype. The Hans' algorithm is the most widely accepted algorithm to define phenotype using immunohistochemistry. Previous studies on PLB confirmed the positive effect on survival for the GC phenotype, whereas a worse survival in case of lack of CD10 expression, presence of MUM-1 expression and non-GC phenotype was found.[11,12]

The p53 tumour suppressor gene product is expressed in 20 to 50% of DLBCL. Protein expression in DLBCL is associated with treatment failure and poor outcome. In this study p53 expression was found in 16 of 36 cases, without a significant effect on survival.[20] The intrinsic capacity of CD44+ tumour cells to disseminate does not appear to play a role in PLB, as all positive cases were localized to the bone without evidence of extra-osseous involvement and without an adverse effect on prognosis.

In our study we could not demonstrate a statistically significant influence on prognosis of tumour phenotype, nor did we find a significant effect on prognosis by the individual immunohistochemical markers. We think this difference between our results and those of others is explained partly by the favourable survival of our cohort, with only five tumour related deaths and only one relapse out of 36 patients. Another difference between our cohort and that of others is the striking homogeneity, with very similar morphology, phenotype and clinical

course for the majority of the cases. This positive and homogeneous clinical course results in few statistical events. Remarkably however, 50% of the patients with progressive disease had a non-GC phenotype. Furthermore, the one patient with a relapse had an immunoblastic morphology and was of the non-GC phenotype. In a previous study, a similar negative correlation with survival was noted for the immunoblastic phenotype.[2]

Of note, all recent PLB studies found a clear morphologic and phenotypic relation of PLB to GC cells, despite the fact that normal bone or bone marrow lacks germinal centres. These findings support the hypothesis that PLB represents a *de novo* DLBCL with a genetic relationship to GC like lymphomas. Some authors speculate that there are specific homing factors for these tumour cells. More research is necessary to investigate the pathophysiology of this rare extranodal subtype of DLBCL.

In conclusion, this study illustrates the homogeneity of PLB. The majority of cases is of the GC phenotype and has a favourable prognosis.

## Reference List

- 1 Desai S, Jambhekar NA, Soman CS, *et al.* Primary lymphoma of bone: a clinicopathologic study of 25 cases reported over 10 years. *J Surg Oncol* 1991;**46**:265-9.
- 2 Heyning FH, Hogendoorn PCW, Kramer MHH, *et al.* Primary non-Hodgkin's lymphoma of bone: a clinicopathological investigation of 60 cases. *Leukemia* 1999;**13**:2094-8.
- 3 Unni KK, Hogendoorn PCW. Malignant Lymphoma. In: Fletcher CDM, Unni KK, Mertens F, eds. *Pathology and genetics of tumours of soft tissue and bone*. Lyon: IARC Press, 2002:306-8.
- 4 Berglund M, Thunberg U, Amini RM, *et al.* Evaluation of immunophenotype in diffuse large B-cell lymphoma and its impact on prognosis. *Mod Pathol* 2005;**18**:1113-20.
- 5 Monni O, Franssila K, Joensuu H, *et al.* BCL2 overexpression in diffuse large B-cell lymphoma. *Leuk Lymphoma* 1999;**34**:45-52.
- 6 Kremmidiotis G, Zola H. Changes in CD44 expression during B cell differentiation in the human tonsil. *Cell Immunol* 1995;**161**:147-57.
- 7 Huebner-Chan D, Fernandes B, Yang G, *et al.* An immunophenotypic and molecular study of primary large B-cell lymphoma of bone. *Mod Pathol* 2001;**14**:1000-7.
- 8 Martinka M, Comeau T, Foyle A, *et al.* Prognostic significance of t(14;18) and bcl-2 gene expression in follicular small cleaved cell lymphoma and diffuse large cell lymphoma. *Clin Invest Med* 1997;**20**:364-70.
- 9 Kramer MHH, Hermans J, Wijburg E, *et al.* Clinical relevance of BCL2, BCL6, and MYC rearrangements in diffuse large B-cell lymphoma. *Blood* 1998;**92**:3152-62.
- 10 Kuppers R, Klein U, Hansmann ML, *et al.* Cellular origin of human B-cell lymphomas. *N Engl J Med* 1999;**341**:1520-9.
- 11 de Leval L, Braaten KM, Ancukiewicz M, *et al.* Diffuse large B-cell lymphoma of bone: an analysis of differentiation-associated antigens with clinical correlation. *Am J Surg Pathol* 2003;**27**:1269-77.
- 12 Adams H, Tzankov A, d'Hondt S, *et al.* Primary diffuse large B-cell lymphomas of the bone: prognostic relevance of protein expression and clinical factors. *Hum Pathol* 2008;**39**:1323-30.
- 13 Harris NL. Mature B-cell neoplasms. In: Swerdlow SH, Campo E, Harris NL, *et al.*, eds. *WHO Classification of Tumours of Haematopoietic and Lymphoid Tissues*. Lyon: IARC Press, 2008:179-267.
- 14 Hans CP, Weisenburger DD, Greiner TC, *et al.* Confirmation of the molecular classification of diffuse large B-cell lymphoma by immunohistochemistry using a tissue microarray. *Blood* 2004;**103**:275-82.
- 15 Baar J, Burkes RL, Bell R, *et al.* Primary non-Hodgkin's lymphoma of bone. A clinicopathologic study. *Cancer* 1994;**73**:1194-9.
- 16 Ostrowski ML, Unni KK, Banks PM, *et al.* Malignant lymphoma of bone. *Cancer* 1986;**58**:2646-55.
- 17 Beal K, Allen L, Yahalom J. Primary bone lymphoma: treatment results and prognostic factors with long-term follow-up of 82 patients. *Cancer* 2006;**106**:2652-6.
- 18 Ramadan KM, Shenkier T, Sehn LH, *et al.* A clinicopathological retrospective study of 131 patients with primary bone lymphoma: a population-based study of successively treated cohorts from the British Columbia Cancer Agency. *Ann Oncol* 2007;**18**:129-35.
- 19 Gianelli U, Patriarca C, Moro A, *et al.* Lymphomas of the bone: a pathological and clinical study of 54 cases. *Int J Surg Pathol* 2002;**10**:257-66.
- 20 Kramer MHH, Hermans J, Parker J, *et al.* Clinical significance of bcl2 and p53 protein expression in diffuse large B-cell lymphoma: a population-based study. *J Clin Oncol* 1996;**14**:2131-8.

# Chapter 5

## **Array-based comparative genomic hybridisation analysis reveals recurrent chromosomal alterations in primary diffuse large B cell lymphoma of bone**

E.H. Heyning,<sup>1</sup> P.M. Jansen,<sup>2</sup> P.C.W. Hogendoorn,<sup>2</sup> K. Szuhai<sup>3</sup>

<sup>1</sup>Department of Internal Medicine, Medical Center Haaglanden,  
The Hague, The Netherlands

<sup>2</sup>Department of Pathology, Leiden University Medical Center, Leiden, The Netherlands

<sup>3</sup>Department of Molecular Cell Biology, Leiden University Medical Center, Leiden,  
The Netherlands

*Journal of Clinical Pathology, 2010; 63: 1095-1100*

## Abstract

**Aims:** Primary non-Hodgkin's lymphoma of bone (PLB) is a rare subtype of primary extranodal diffuse large B cell lymphoma. PLB has morphological homogeneity and a relatively favourable clinical behaviour. Recent studies report that array-based comparative genomic hybridisation (array-CGH) analysis can be used to classify lymphomas into clinically and biologically relevant phenotypes and possibly reveal differences in oncogenic mechanisms. Here the authors performed the first array-CGH study to detect illness related genomic alterations in nine, clinically well-staged primary lymphoma of bone cases.

**Methods:** Nine frozen samples from primary lymphoma of bone patients were immunophenotyped and subsequently investigated using a well-established array-CGH platform. The array-CGH results were confirmed by fluorescence in situ hybridisation. Clinical data and follow-up were obtained for all nine patients.

**Results:** Of the nine patients, eight reached complete remission, and one had progressive disease and died of primary lymphoma of bone. Frequent aberrations were: loss of 14q32 (n=7), trisomy 7 (n=6), gain of the long arm of chromosome 1 (n=5) and amplification of 2p16.1 (n=4). No statistically significant correlation between genetic abnormalities and clinical outcome was found.

**Conclusions:** The authors found several recurrent genomic aberrations, including five cases with gain of 1q and four cases with 2p16.1 amplification. These findings are associated with a germinal centre-like phenotype and favourable treatment outcome, and differ from chromosomal aberrations found in other extranodal lymphomas. These findings further substantiate the notion that primary lymphoma of bone should be considered as a distinct entity not only on clinic-pathological grounds but also on the genomic level as well.



## Introduction

Primary non-Hodgkin's lymphoma of bone (PLB) is a rare neoplastic disorder, comprising 5% of extranodal non-Hodgkin's lymphomas (NHLs).<sup>1</sup> It is a subtype of primary extranodal diffuse large B cell lymphoma (DLBCL), which, as a whole, is the most heterogeneous group of lymphomas. PLB as an entity, however, has morphological and clinical homogeneity.<sup>2</sup> Characteristically, these lymphomas present in the long bones such as the humerus or the femur with pain or a palpable mass. During MR imaging, it might not present infrequently as a non-aggressive lesion.<sup>3</sup> Complete remission is usually achieved with a combination of chemotherapy and radiotherapy, with only a few patients relapsing during follow-up. Needless to say, adequate staging including a CT-scan of the thorax and abdomen, and iliac crest bone marrow biopsy are essential in order to rule out disseminated DLBCL involving the bone instead of a primary bone presentation.

Studies on extranodal lymphoma are infrequent, even though the incidence of extranodal lymphoma in Western countries has increased in the last 40 years.<sup>4,5</sup> This discrepancy can be explained by the low frequency of primary involvement of any particular extranodal site. To overcome these small patient numbers, many authors have combined all extranodal cases to obtain enough statistical power for their research. However, it is questionable whether such a general distinction has any clinical relevance, since clinical outcome and tumour biology differ substantially between the various extranodal localisations.<sup>6-8</sup> Studies on PLB specifically are even rarer because, apart from the low patient numbers, the research on PLB is hindered due to limited availability of frozen tissue specimens and technological difficulties related to handling the tumour material of osseous origin.

Research in gene-expression profiling has led to the concept that most DLBCLs derive from germinal centre (GC) B cells or from their descendants, that is activated B cells or non-GC B cells. Recent studies have shown that the majority of PLBs are of the GC-like phenotype which is associated with a better prognosis than the non-GC phenotype.<sup>2,9,10</sup> Array-based comparative genomic hybridisation (array-CGH) enables us to detect the genomic copy number of alterations of cancers with high resolution. Recent studies report that this technique can be used to classify lymphomas into the clinically and biologically relevant phenotypes, GC-like and non-GC-like, and possibly reveal differences in oncogenic mechanisms.<sup>11</sup>

No studies using array-CGH analysis on PLB have been published so far. We investigated genomic alterations in nine well-documented cases of PLB using this technique and analysed the results in the context of data available from literature on studies of other distinct subtypes of extranodal DLBCL such as skin, brain and testis.<sup>12,13</sup>

## Methods

### Tissue sample collection and selection

Ten frozen samples from PLB patients were collected from the tissue bank at the Leiden University Medical Center, and one sample was collected from the tissue bank at the University Medical Center Groningen, The Netherlands. Following quality control of DNA, we disregarded two samples and performed an array-CGH analysis on nine of the 11 cases. All samples were handled in a coded fashion, and all procedures were performed according to the ethical guidelines, 'Code for Proper Secondary Use of Human Tissue in The Netherlands' (Dutch Federation of Medical Scientific Societies). Clinical data and follow-up were obtained on all nine patients. PLB was defined as a histologically proven non-Hodgkin's lymphoma arising within the medullary cavity of a bone, with or without regional lymph node involvement, but without evidence of other extranodal involvement.<sup>1</sup> Multiple bone lesions were acceptable as long there was no evidence of earlier lymphoma elsewhere. All patients were staged adequately with an MRI of the tumour site, CT-scan of the thorax and abdomen, and iliac crest bone marrow biopsy. The relevant clinical and follow-up data for the patients investigated are summarised in table 1.

### Histological classification and immunohistochemistry

The pathological diagnosis was established according to the WHO classification<sup>14</sup> using standard histological criteria and immunohistochemistry using antibodies directed against Vimentin, CD45, CD3, CD20, CD79a and CD99. Immunohistochemical staining was performed on 4 mm sections of formalin-fixed, paraffin-embedded tissues, using standard procedures as detailed elsewhere.<sup>2</sup> In addition to the diagnostic marker panel listed above, a set of markers relevant to a GC/non-GC phenotype was used: CD10, BCL6 and MUM-1.

**Table 1.** Overview of the clinicopathological data and test results.

patient	gender	age	stage	Localisation	treatment	result	Follow-up
L2734	m	46	I	Humerus	CHOP-like +RT	CR	Disease-free
L2735	m	58	I	Humerus	CHOP-like+RT	CR	Disease-free
L2736	m	61	IV	Os ilium/ vertebra	CHOP-like+RT	PR	Dead from disease
L2737	m	25	I	Femur	R-CHOP	CR	Disease-free
L2738	f	72	I	Femur	R-CHOP+RT	CR	Disease-free
L2739	f	32	I	Femur	CHOP-like+RT	CR	Disease-free
L2740	m	33	I	Tibia	CHOP-like+RT	CR	Disease-free
L2385	m	25	I	Tibia	R-CHOP + RT	CR	Disease-free
L2060	m	35	I	Scapula	CHOP + RT	CR	Disease-free

CR, complete remission; F female; M, male; PR, progressive diseases; RT, radiotherapy; Stage, Ann Arbor stage (Stage IV is multifocal),

### Array-CGH

Genomic DNA was isolated using high salt after SDS/proteinase K digestion; 500 ng was labelled with Cy3-dCTP (GE Healthcare, Diegem, Belgium) using the BioPrime DNA Labelling System (Invitrogen, Breda, The Netherlands). As a reference DNA, 500 ng of either male or female human genomic DNA (Promega, Leiden, The Netherlands) was labelled using Cy5-dCTP. Labelled samples were hybridised array slides containing ~3500 BACs clones spaced at ~1 Mb density over the full genome, a set of subtelomeric sequences for each chromosome arm and a few hundred probes selected for their involvement in oncogenesis, and were meticulously validated.<sup>15</sup> As all clones were part of the Human Genome Project, updated sequencing information is available from the ENSEMBL web page (<http://www.ensembl.org>). The clones were grown, amplified and spotted as described previously, and made available by the Wellcome Trust Sanger Institute (<http://www.sanger.ac.uk>). The array slides were produced in-house at Leiden University Medical Center according to Knijnenburg et al.<sup>16</sup>

Hybridisation and posthybridisation washing steps were performed on a HS400 TECAN automated hybridisation station (Tecan, Giessen, The Netherlands) according to Knijnenburg et al,<sup>17</sup> and slides were then scanned with a GenePix Personal 4100A scanner at 5 mm resolution (Axon Instruments, Union City, California). The spot intensities were measured using GenePix Pro 4.1 software. With this software, spots in which the reference DNA intensity was below five times the mean of the background or presented more than 3% saturated pixels were excluded from further analysis. The test/reference ratios were normalised for the median of the ratios of all features. The triplicates of the features were averaged in a homemade routine developed in Microsoft Excel 2000, and spots outside the 20% CI of the average of the triplicate were excluded. Only those targets presenting at least two spots within 20% CI of their average were used. Any imbalances in the targets were determined based on log<sub>2</sub> ratios of the average of their replicates, and we considered sequences as amplified or deleted when outside the  $\pm 0.3$  range.

Resulting data files were further analysed, and log<sub>2</sub> ratio values were analysed using R packages CGHCall and VAMP webtool.<sup>18 19</sup> Hemi- and homozygous loss were defined as one and two levels lower than normal respectively, and gain as one or two levels higher than normal. Gains with more than two levels were identified as amplified regions. Genomic locations (chromosome band and clone positions) were determined according to Ensembl Gene build (database version 54.36p) ([http://www.ensembl.org/Homo\\_sapiens](http://www.ensembl.org/Homo_sapiens)).

### Confirmatory interphase fluorescence in situ hybridisation (FISH) on formalin fixed paraffin embedded tissue (FFPE) samples

To confirm the array-CGH results, we performed interphase FISH on 4  $\mu$ m thick FFPE tissue of the L2736 with small amplified regions of chromosomes 2p16.1 containing the *BCL11A* and *REL* gene loci. A panel of BAC probes was selected covering the region, and as a reference chromosome two centromer specific alphoid repet probes were combined. The following BAC probes were used: RP11-416L21, RP11-498O5, RP11-493E12, RP11-373L24 and RP11-440P5

(the latter two were present on the BAC array-CGH platform detecting the amplification) for the aliphoid repeat sequence D2Z2 plasmid clone. Probes were labelled using standard protocols as described earlier.<sup>20,21</sup>

Interphase FISH experiments was performed according to previously described protocols on formalin-fixed paraffinembedded tissue slides.<sup>22</sup> Slides were embedded in Citifluor antifading solution containing with 4',6-diamino-2-phenylindole-dihydrochloride (DAPI)/citifluor (500 ng/ml) (Brunschwig Chemie, Amsterdam, The Netherlands). Image acquisition was performed using a DM-RA epifluorescence microscope (Leica Microsystems b.v. Rijswijk, The Netherlands) equipped with a Quantix camera (Roper Scientific, Fairfield, Iowa). Grey scale images were collected with a 63× oil immersion objective by using appropriate filters to visualise the FITC, Cy3 and DAPI stainings. For further image processing, in-house-developed software (ColourProc) was used.<sup>23</sup>

## Results

All patients presented with pain and/or a palpable mass, most often at a single location in one of the long bones. Multifocal bone involvement, scored as stage IV, was noted in one case, and none had iliac crest bone marrow involvement. The male:female ratio was 7:2. The mean age at presentation was 43, ranging from 25 years to 72 years. Clinical findings, including age, gender, primary location of tumour, treatment and outcome, are summarised in table 1. The minimum follow-up was 12 months. All patients were treated with CHOP (cyclophosphamide, doxorubicin, vincristin, prednisone) or CHOP-like chemotherapy; three were also treated with rituximab. Eight patients were also treated with involved field radiotherapy. Of the nine patients, eight reached complete remission; one had progressive disease within 3 months after completing R-CHOP and died of disease, after an initial response to chemotherapy.

### Immunohistochemical features

Applying Hans' algorithm, the GC phenotype was defined as CD10+BCL-6+, and the non-GC phenotype was defined as CD10-BCL-6-. In the case of CD10-BCL-6+, the phenotype was defined as GC if MUM-1 expression was negative and as non-GC if MUM-1 was positive.<sup>24</sup> Eight cases were of the GC phenotype, and one case was of the non-GC phenotype. The results are summarised in table 2.

### Array-based CGH

Following quality control, frozen tumour biopsy samples of nine patients diagnosed as having PLB were analysed for copy-number alterations using array-CGH. The array-CGH profiles showed numerous chromosomal alterations in all analysed PLB samples. No common alteration was observed in all cases. The overall gain/loss frequency was plotted using an R script, CGHC all (figure 1A). The overall pattern of chromosomal alterations of PLB is characterised by gains of large genomic regions on chromosome 1q, 6p and 7, and losses of regions on chromosome

**Table 2.** Overview of Hans' algorithm and selected array-based comparative genomic hybridisation results

Patient	CD10	BCL-6	MUM-1	phenotype	Gain of 1q	Amplification of 2p16.1
L2734	-	+	-	GC	+	-
L2735	-	+	-	GC	+	+
L2736	+	+	-	GC	-	+
L2737	-	+	-	GC	-	+
L2738	-	-	+	Non-GC	-	-
L2739	+	+	-	GC	+	-
L2740	+	+	-	GC	+	-
L2385	-	+	-	GC	+	+
L2060	-	+	-	GC	-	-

GC, germinal-centre-like phenotype; Non-GC, non-germinal-centre-like phenotype.

1p, 6q and 15. A high level of amplification was observed involving the 2p15–16.1 region in 4/9 cases (table 2). None of the analysed samples presented homozygous deletions. In order to delineate the smallest recurrent chromosomal regions with altered probes common to the set of array-CGH profiles in at least 35% of the analysed cases, we determined the minimal common regions (MRC) containing potentially relevant genes<sup>25</sup> and the VAMP web tool.<sup>26</sup> An overview of the MCRs is given in table 3. Eight MCRs were identified, and four of the eight regions were full chromosome or full chromosome arms (gain: 1q, 6q and chromosome 7, loss: chromosome 15). The four MCRs with smaller genomic changes were: loss of chromosome 1p36.3e1p35.1 (w30 Mb region), high level of amplification of chromosome 2p16.1e2p15 (0.9 Mb), gain of chromosome 6p21.31 (3.7 Mb) and loss of 14q32.33 (1 Mb). Analysis of the co-occurrence frequency of the genomic alteration revealed that the deletion of 1p, 6q and 14q and the monosomy of chromosome 15 were mostly together, while no such similar association was seen for other regions. Clustering of the analysed samples, due to the low numbers of samples and homogeneous clinical group, were not informative.

Next, we matched the four MCRs with the Cancer Gene Census, a list of genes for which mutations have been casually identified in cancer.<sup>27</sup> In table 3B, the four identified MCRs with the 12 identified tumour suppressor genes and oncogenes are presented. The most highly recurrent MCR with loss of the *IGH* gene may represent a clonal immunoglobulin gene rearrangement rather than direct oncogenic involvement.

### Confirmatory interphase FISH

For two cases (L2735 and L2736) with small amplification of the 2p16.1 region containing the *BCL11A* and *REL* gene loci, 4 µm FFPE sections were cut and analysed by interphase FISH. A probe mixture was used containing five BAC clones covering the amplified region - including those two that were present on the BAC array and showed the amplification (RP11-373L24 and RP11-440P5)- labeled in red and mixed with a chromosome 2 specific alphoid repeat probe labeled in green. As a control, an FFPE section from skin was used and showed a distinct pattern

**Table 3.** Array-based comparative genomic hybridisation result overview in PLB (A) Most recurrent chromosomal alterations in PBL (losses and gains are separated)

Chromosome Band	Start Clone	End Clone	Start Position (bp)	End Position (bp)	Size (bp)	CNA	No of cases
1p36.3-1p35.1	RP4-785P20	RP1-117N3	3214521	33379650	30165129	Loss	5
6q14.1-6q27	RP11-25O6	RP5-1086L22	83405494	170509779	87104285	Loss	4
14q32.33	RP11-417P24	CTC-820M16	105267358	106278173	1010815	Loss	7
15q11.2-.5	RP11-	RP11-	20363717	100036184	79672467	Loss	5
15q26		289D12	14C10				
1q21.1-1q44.1	RP3-365I19	RP11-438H8	142642781	247249719	104606938	Gain	5
2p16.1-2p15	RP11-440P5	RP11-479F13	60501800	61422449	920349	Amplification	4
6p21.31	RP11-175A4	RP1-90K10	33521322	37077773	3556451	Gain	4
7p22-7q36.2	RP11-449P15	RP11-518I12	885103	157752947	156867844	Gain	6

## B: Candidate genes residing in frequently altered regions

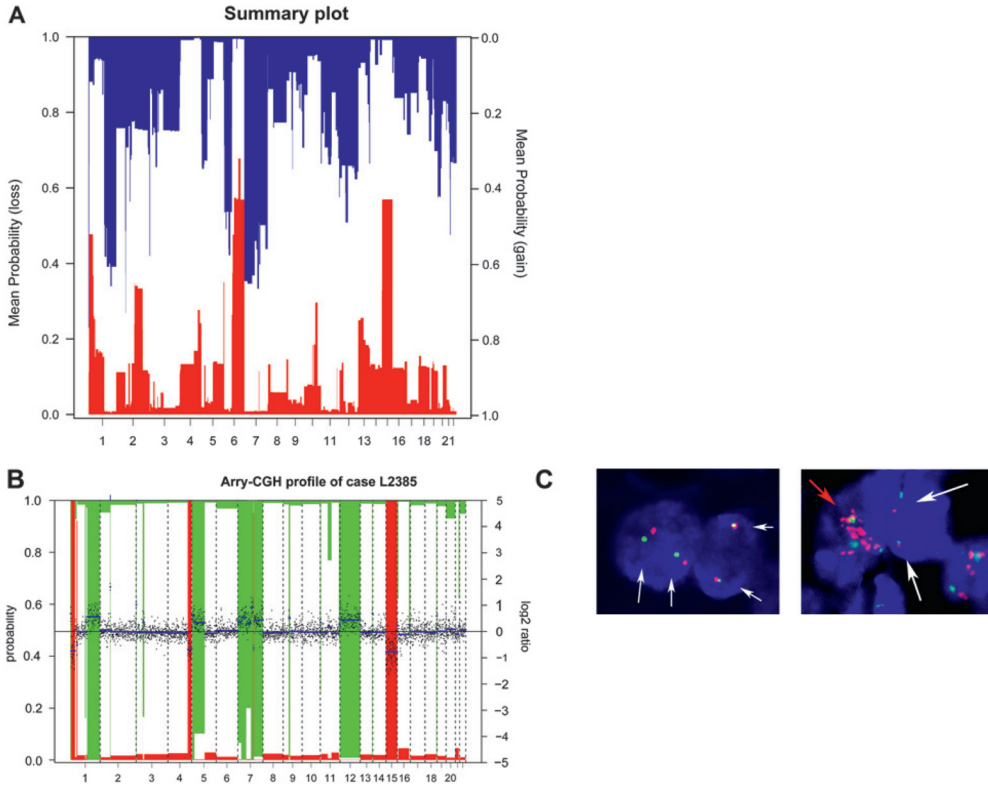
Chromosome	Chromosome Band	Size (bp)	CNA	No of cases	Cancer Gene Census
1	1p36.3-1p35.1	30165129	Loss	5	LCK, MDS2, SDHB, PRDM16, PAX7
14	14q32.33	1010815	Loss	7	IGH
2	2p16.1-2p15	920349	Amplification	4	REL, BCL11A
6	6p21.31	3556451	Gain	4	HMGAI, SFRS3, FANCE

CNA, copy number alteration.

of two centromeric signals in green with two 2p16.1 locus-specific signals in red (figure 1C left panel). The FISH showed a clear amplification pattern in case L2736 with a high level of amplification involving the 2p16.1 locus mingled with normal cells (figure 1C right panel; white arrows indicate the normal cells, and the red arrow points to a tumour cell with amplified red signals).

**Correlation with clinical data**

Because of the very good clinical outcome of this group of patients, which results in few statistical events, no statistically significant correlation between genetic abnormalities and prognosis could be made. The one patient with a dismal clinical course showed no specific array-CGH pattern. It did have the 2p16.1 amplification, but not a gain of 1q. The clinical



**Figure 1.** Overview of the array-based comparative genomic hybridisation (array-CGH) results and confirmatory fluorescence in situ hybridisation (FISH) experiments. (A) Array-CGH cumulative summary plot of all analysed PLB samples generated by default settings of the CGHCall R software. Probabilities for genomic losses displayed on the left y axis and gain probabilities are on the right y axis. The calculated probabilities for genomic loss or gain are represented by red and blue lines, respectively. (B) Representative array-CGH profile of case L2385. Normalised log<sub>2</sub> ratios are plotted with the scale on the right axis. Vertical bars indicate loss and gain probabilities. The probability scale is on the left axis; reversed ('1-') for the gains. Segments are plotted as horizontal lines. Segments with a bar extending beyond the middle axis (probability >0.5) are called gains or losses. Amplification locations are indicated by tick marks on the top axis. This case shows loss of 1p, gain of 1q, amplification of 2p15e16.1 (see blue tick mark on the top), gain of chromosome 7 and loss of chromosome 15 without involvement of chromosome 6. (C) Interphase FISH results using 2p16.1 locus-specific pore set (red) and chromosome 2 centromer-specific alphoid repeat sequence probe (green) in combination with DNA counterstaining agent: DAPI (blue). Left panel: two normal cells with two green and two red signals as indicated by white arrowheads. Right panel: interphase FISH proved the amplification of the 2p16.1 locus in case L2736. The red arrowhead indicates amplified signals in a tumor cell; white arrowheads point to a normal cell with two green and two red signals.

parameters were unfavourable, with age at presentation over 60, multifocal disease and bulky tumour load. The one case with a non-GC phenotype did show an excellent response to chemotherapy. There was no specific array-CGH pattern in this non-GC phenotype either.

## Discussion

Here we present the first array-CGH study on PLB. The sample size of the cohort was restricted due to the rarity of this tumour and, more specifically, the scarcity of fresh frozen tumour samples of PLB. As a result, few studies on PLB have been published because of these difficulties, which stresses the importance of the current investigation. We and others demonstrated in previous reports, using clinical and immunohistochemical data, that PLB has a favourable prognosis and is of GC-like origin in the majority of cases.<sup>2 10 28</sup> Our current cohort is representative of the typical clinical spectrum of PLB, with the majority of the tumours presenting in the long bones, and all but one patient achieving complete remission. Most prior studies on PLB excluded patients with multiple bone involvement stage IV patients—which leads to an imperfect representation of the spectrum of this disease. The patient with progressive disease was the only patient in this cohort with multifocal disease. Moreover, his age at presentation was over 60. As we previously reported, these two parameters, both included in the IPI risk index, are the main adverse clinical prognostic factors in PLB.<sup>2 29</sup>

DLBCL is the most heterogeneous group of lymphomas. Over the years, various subtypes and classifications have been designed in an attempt to predict clinical course and prognosis for individual patients. Historically, DLBCL is divided into nodal and extranodal lymphoma. The data currently available in the literature on extranodal lymphoma are often obtained from studies performed on extranodal lymphoma in general. However, since clinical outcome varies substantially among all the specific sites of primary lymphoma, this generalisation might be clinically inappropriate. It is therefore important to study any particular primary site of lymphoma as a separate entity. Research in genomic scale gene-expression profiling has resulted in the definition of two tumour phenotypes in DLBCL, one GC-like, and one non-GC-like. A difference in response to multiagent chemotherapy is noted between these subgroups, with a favourable outcome for the GC phenotype. Unfortunately, these two phenotypes still show considerable clinical and morphological heterogeneity.

Recent studies show that array-CGH can be used for identifying these tumour phenotypes in malignant lymphoma as well.<sup>11</sup> More importantly, array-CGH can identify chromosomal aberrations within the same tumour phenotype, which is a subsequent step in making the group of (extranodal) DLBCL less heterogeneous.

For example, primary cutaneous large B cell lymphoma, leg-type, which has an moderately aggressive course, frequently shows a 9p21.3 deletion.<sup>13</sup> The prognosis of immune privileged associated DLBCL, such as testis and CNS DLBCL, is only slightly better. The typical aberration of these immune privileged lymphomas is deletion of 6q21e22.<sup>12</sup> Both subtypes of extranodal



lymphoma are mostly of the non-GC origin, but differ considerably in clinical outcome. The dissimilar array CGH results between these subtypes of extranodal DLBCL suggest another tumour aetiology via different oncogenic mechanisms.

In this study, we found several recurrent aberrations, all of which have been described in DLBCL before. Intriguingly, several of these chromosomal changes are described in the literature as negative prognostic factors, which cannot be confirmed in this study focusing on PLB specifically. The data from our and other previous studies<sup>11-13</sup> suggest that for extranodal DLBCL, genotype-based classification (ie, array-CGH study) in combination with the site of involvement is a better class identifier. Loss of 14q32.33 was the most frequently observed event (seven cases). This deletion indicates a breakpoint in the IGH locus, which has been frequently described in B cell malignancies and, more specifically, in extranodal cutaneous DLBCL, such as large B cell lymphoma of the leg, and in primary cutaneous follicle centre lymphoma.<sup>30</sup> Trisomy 7 (six cases) is associated in the literature with progression of follicular lymphoma and with DLBCL, mostly as an adverse prognostic factor.<sup>31</sup> 2p16.1 amplification (four cases) and gain of 1q (five cases) have been associated with GC phenotype in the literature.<sup>8, 32, 33</sup> Our array-CGH results and immunohistochemical results confirm the previously described GC-like origin of PLB and are in accordance with its favourable prognosis (table 2). Of note, the one patient with non-GC phenotype did not have a gain of 1q or 2p16.1 amplification. It has been suggested that the REL proto-oncogene is the target gene of 2p16.1 amplification in DLBCL.<sup>34</sup> It encodes a transcription factor in the nuclear factor (NF) kappa-B family. Studies on the prognostic influence of 2p16.1 amplification in DLBCL are still controversial.<sup>35</sup> The one case in this study with 2p16.1 amplification, age over 60 at presentation, stage IV at presentation and an unfavourable outcome together with the favourable outcome of the case with non-GC phenotype, which had stage I at presentation, does suggest that clinical parameters in PLB have a strong influence on prognosis. Gain of the short arm of chromosome 6 and loss of the long arm of chromosome 6 are both adverse prognostic factors frequently found in DLBCL.<sup>12, 36</sup> In the future, array-CGH could be helpful in risk-stratification of extranodal DLBCL patients, which are all treated in a similar way at this moment. The goal would be to select those patients who need more intensive therapy than the standard regime of R-CHOP and radiotherapy on the one hand, and to protect the patients with a more favourable prognosis against too intensive a treatment on the other hand.

## Conclusions

We found several recurrent genomic aberrations, including five cases with gain of 1q and four cases with 2p16.1 amplification, which are both associated with the GC phenotype. These findings concur with the relatively good prognosis of this rare type of extranodal lymphoma and differ from array-CGH results in other extranodal lymphomas.

## References

1. Unni KK, Hogendoorn PCW. Malignant lymphoma. In: Fletcher CDM, Unni KK, Mertens F, eds. *Pathology and Genetics of Tumours of Soft Tissue and Bone*. Lyon: IARC Press, 2002:306-8.
2. Heyning FH, Hogendoorn PCW, Kramer MH, *et al*. Primary non-Hodgkinis lymphoma of bone: a clinicopathological investigation of 60 cases. *Leukemia* 1999;**13**:2094-8.
3. Heyning FH, Kroon HM, Hogendoorn PCW, *et al*. MR imaging characteristics in primary lymphoma of bone with emphasis on non-aggressive appearance. *Skeletal Radiol* 2007;**36**:937-44.
4. Groves FD, Linet MS, Travis LB, *et al*. Cancer surveillance series: non-Hodgkinis lymphoma incidence by histologic subtype in the United States from 1978 through 1995. *J Natl Cancer Inst* 2000;**92**:1240-51.
5. Chiu BC, Weisenburger DD. An update of the epidemiology of non-Hodgkinis lymphoma. *Clin Lymphoma* 2003;**4**:161e8.
6. Zucca E, Roggero E, Bertonni F, *et al*. Primary extranodal non-Hodgkinis lymphomas. Part 1: Gastrointestinal, cutaneous and genitourinary lymphomas. *Ann Oncol* 1997;**8**:727-37.
7. Zucca E, Roggero E, Bertonni F, *et al*. Primary extranodal non-Hodgkinis lymphomas. Part 2: Head and neck, central nervous system and other less common sites. *Ann Oncol* 1999;**10**:1023-33.
8. Houldsworth J, Mathew S, Rao PH, *et al*. REL proto-oncogene is frequently amplified in extranodal diffuse large cell lymphoma. *Blood* 1996;**87**:25-9.
9. Alizadeh AA, Eisen MB, Davis RE, *et al*. Distinct types of diffuse large B-cell lymphoma identified by gene expression profiling. *Nature* 2000;**403**:503-11.
10. Adams H, Tzankov A, diHondt S, *et al*. Primary diffuse large B-cell lymphomas of the bone: prognostic relevance of protein expression and clinical factors. *Hum Pathol* 2008;**39**:1323-30.
11. Takeuchi I, Tagawa H, Tsujikawa A, *et al*. The potential of copy number gains and losses, detected by array-based comparative genomic hybridization, for computational differential diagnosis of B-cell lymphomas and genetic regions involved in lymphomagenesis. *Haematologica* 2009;**94**:61-9.
12. Booman M, Szuhai K, Rosenwald A, *et al*. Genomic alterations and gene expression in primary diffuse large B-cell lymphomas of immune-privileged sites: the importance of apoptosis and immunomodulatory pathways. *J Pathol* 2008;**216**:209-17.
13. Dijkman R, Tensen CP, Jordanova ES, *et al*. Array-based comparative genomic hybridization analysis reveals recurrent chromosomal alterations and prognostic parameters in primary cutaneous large B-cell lymphoma. *J Clin Oncol* 2006;**24**:296-305.
14. Harris NL. Mature B-cell neoplasms. In: Swerdlow SH, Campo E, Harris NL, *et al*, eds. *WHO Classification of Tumours of Haematopoietic and Lymphoid Tissues*. Lyon: IARC Press, 2008:179-267.
15. Fiegler H, Gribble SM, Burford DC, *et al*. Array painting: a method for the rapid analysis of aberrant chromosomes using DNA microarrays. *J Med Genet* 2003;**40**:664-70.
16. Knijnenburg J, Szuhai K, Giltay J, *et al*. Insights from genomic microarrays into structural chromosome rearrangements. *Am J Med Genet A* 2005;**132A**:36-40.
17. Knijnenburg J, van der Burg BM, Tanke HJ, *et al*. Optimized amplification and fluorescent labeling of small cell samples for genomic array-CGH. *Cytometry A* 2007;**71**:585-91.
18. Willenbrock H, Fridlyand J. A comparison study: applying segmentation to array CGH data for downstream analyses. *Bioinformatics* 2005;**21**:4084-91.
19. Venkatraman ES, Olshen AB. A faster circular binary segmentation algorithm for the analysis of array CGH data. *Bioinformatics* 2007;**23**:657-63.
20. Pajor L, Szuhai K, Mehes G, *et al*. Combined metaphase, interphase cytogenetic, and flow cytometric analysis of DNA content of pediatric acute lymphoblastic leukemia. *Cytometry* 1998;**34**:87-94.
21. Szuhai K, Bezrookove V, Wiegant J, *et al*. Simultaneous molecular karyotyping and mapping of viral

- DNA integration sites by 25-color COBRA-FISH. *Genes Chromosomes Cancer* 2000;**28**:92-7.
22. Rossi S, Szuhai K, Ijszenga M, *et al.* EWSR1-CREB1 and EWSR1-ATF1 fusion genes in angiomatoid fibrous histiocytoma. *Clin Cancer Res* 2007;**13**:7322-8.
  23. Szuhai K, Tanke HJ. COBRA: combined binary ratio labeling of nucleic-acid probes for multi-color fluorescence in situ hybridization karyotyping. *Nat Protoc* 2006;**1**:264-75.
  24. Hans CP, Weisenburger DD, Greiner TC, *et al.* Confirmation of the molecular classification of diffuse large B-cell lymphoma by immunohistochemistry using a tissue microarray. *Blood* 2004;**103**:275-82.
  25. Rouveirol C, Stransky N, Hupe P, *et al.* Computation of recurrent minimal genomic alterations from array-CGH data. *Bioinformatics* 2006;**22**:849-56.
  26. La RP, Viara E, Hupe P, *et al.* VAMP: visualization and analysis of array-CGH, transcriptome and other molecular profiles. *Bioinformatics* 2006;**22**:2066-73.
  27. Futreal PA, Coin L, Marshall M, *et al.* A census of human cancer genes. *Nat Rev Cancer* 2004;**4**:177-83.
  28. Beal K, Allen L, Yahalom J. Primary bone lymphoma: treatment results and prognostic factors with long-term follow-up of 82 patients. *Cancer* 2006;**106**:2652-6.
  29. Heyning FH, Hogendoorn PCW, Kramer MH, *et al.* Primary lymphoma of bone: extranodal lymphoma with favourable survival independent of germinal centre, post-germinal centre or indeterminate phenotype. *J Clin Pathol* 2009;**62**:820-4.
  30. Hallermann C, Kaune KM, Siebert R, *et al.* Chromosomal aberration patterns differ in subtypes of primary cutaneous B cell lymphomas. *J Invest Dermatol* 2004;**122**:1495-502.
  31. Bernell P, Jacobsson B, Liliemark J, *et al.* Gain of chromosome 7 marks the progression from indolent to aggressive follicle centre lymphoma and is a common finding in patients with diffuse large B-cell lymphoma: a study by FISH. *Br J Haematol* 1998;**101**:487-91.
  32. Houldsworth J, Olshen AB, Cattoretti G, *et al.* Relationship between REL amplification, REL function, and clinical and biologic features in diffuse large B-cell lymphomas. *Blood* 2004;**103**:1862-8.
  33. Tagawa H, Suguro M, Tsuzuki S, *et al.* Comparison of genome profiles for identification of distinct subgroups of diffuse large B-cell lymphoma. *Blood* 2005;**106**:1770-7.
  34. Fukuhara N, Tagawa H, Kameoka Y, *et al.* Characterization of target genes at the 2p15e16 amplicon in diffuse large B-cell lymphoma. *Cancer Sci* 2006;**97**:499-504.
  35. Robledo C, Garcia JL, Caballero D, *et al.* Array comparative genomic hybridization identifies genetic regions associated with outcome in aggressive diffuse large B-cell lymphomas. *Cancer* 2009;**115**:3728-37.
  36. Stokke T, DeAngelis P, Smedshammer L, *et al.* Loss of chromosome 11q21e23.1 and 17p and gain of chromosome 6p are independent prognostic indicators in B-cell on-Hodgkin's lymphoma. *Br J Cancer* 2001;**85**:1900-13.



# Chapter 6

## Nuclear factor- $\kappa$ B activation in primary lymphoma of bone

L. Koens,<sup>1</sup> E.H. Heyning,<sup>2</sup> A. Szepesi,<sup>3</sup> A. Matolcsy,<sup>3</sup> P.C.W. Hogendoorn,<sup>1</sup> P.M. Jansen<sup>1</sup>

<sup>1</sup> Department of Pathology, Leiden University Medical Center, Leiden, The Netherlands;

<sup>2</sup> Department of Internal Medicine, Medical Center Haaglanden, The Hague,  
The Netherlands;

<sup>3</sup> First Department of Pathology and Experimental Cancer Research, Faculty of  
Medicine, Semmelweis University, Budapest, Hungary

*Submitted for publication*

## Abstract

Primary lymphoma of bone is a rare type of extranodal diffuse large B-cell lymphoma with a relatively favorable outcome. Recent scientific interest has focused on elucidating the role of nuclear factor- $\kappa$ B pathway in lymphomagenesis and its possible value as a therapeutic target. In nodal B-cell non Hodgkin lymphomas, constitutive activation of nuclear factor- $\kappa$ B appears to be especially involved in tumor cell survival in the non-germinal center type of diffuse large B-cell lymphoma. In nuclear factor- $\kappa$ B activation, two major pathways are involved: the classical and the alternative pathway. We here investigate nuclear factor- $\kappa$ B activation via both pathways in primary lymphoma of bone, performing immunohistochemical staining procedures for nuclear factor- $\kappa$ B family members on tumor tissues of 50 cases. Nine cases (18%) showed nuclear positivity for p50, and one case showed nuclear co-expression of p52. Positivity for p50 was not restricted to either germinal center- or non-germinal center phenotype of the tumor, or related to an inferior prognosis or treatment resistance. P65 did not show significant nuclear expression. The immunohistochemical nuclear expression of p50 in 18% of the cases suggests constitutive activation of nuclear factor- $\kappa$ B via the classical pathway in a minority of primary lymphoma of bone patients. In contrast to other extranodal types of diffuse large B-cell lymphoma, there was a lack of nuclear co-expression of p65, which may suggest different pathway activation. Alternative pathway activation of nuclear factor- $\kappa$ B does not appear to be significantly involved, as only one case showed significant nuclear expression for p52. Finally, nuclear expression of p50 was not preferentially detected in non-germinal center type or germinal center type primary lymphoma of bone, or related to an inferior prognosis. Therefore, in contrast to nodal diffuse large B-cell lymphoma, the nuclear factor- $\kappa$ B pathway does not appear to be an attractive pathway for targeted therapy in primary lymphoma of bone.

## Introduction

Primary non Hodgkin lymphoma of bone (PLB) is a rare neoplastic disorder, comprising 5% of extranodal lymphomas<sup>(1)</sup> and less than 2% of all non Hodgkin lymphomas.<sup>(2)</sup> PLB mainly presents as an extranodal subtype of diffuse large B cell lymphoma (DLBCL) and shows a non-aggressive radiological presentation.<sup>(3)</sup> Although extranodal DLBCL in general seems to represent a biologically very heterogeneous group of lymphomas with a varying prognosis, PLB shows morphological and clinical homogeneity with a relatively favorable clinical outcome. The 5-year overall survival rate is approximately 90%.<sup>(4,5)</sup> Complete remission is usually achieved with combined chemotherapy and radiotherapy regimens. PLB exhibits a germinal center B-cell (GCB) phenotype in at least half of the cases, but still a considerable amount of tumors show a non germinal center (GC)/activated B-cell (ABC) phenotype.<sup>(6)</sup> Age at presentation over 60 years and immunoblastic tumor cell morphology/non GC phenotype are considered the most important unfavorable predictive factors, although results concerning the prognostic value of the GC phenotype cannot be reproduced in all studies on PLB.<sup>(5,7-9)</sup> The most frequently encountered genomic aberrations include gain of 1q, amplification of 2p16.1 and loss of 14q32.33.<sup>(10)</sup> Considering the amplification of 2p16.1 in PLB, encoding for nuclear factor (NF)- $\kappa$ B family member c-Rel, we were interested in elucidating a potential role of constitutive activation of NF- $\kappa$ B in the pathogenesis of PLB.

NF- $\kappa$ B is a transcription factor involved in several cellular survival mechanisms. It has been implicated that NF- $\kappa$ B activity plays a role in the pathogenesis of different types of B-cell lymphomas, especially in nodal non-GC/ABC type DLBCL, although it is also encountered in a minority of GCB type DLBCL.<sup>(11)</sup> Constitutive activation of NF- $\kappa$ B is required for survival of activated ABC type DLBCL cells *in vitro*<sup>(12)</sup> and ABC type DLBCLs preferentially express known NF- $\kappa$ B target genes.<sup>(13)</sup> Furthermore, mutations in multiple genes involved in the NF- $\kappa$ B activation pathway can cause deregulation of NF- $\kappa$ B in DLBCL.<sup>(11)</sup> It is shown that a small molecule inhibitor of I $\kappa$ B kinase, an essential molecule in the activation of NF- $\kappa$ B, is selectively toxic to ABC type DLBCL cell lines.<sup>(14)</sup> These results suggest a role for the NF- $\kappa$ B pathway as a potential therapeutic target in DLBCL.

In this study, 50 cases of PLB were selected and examined for immunohistochemical expression of three NF- $\kappa$ B subunits (p65, p50 and p52) as surrogate read-outs for constitutive activation of the canonical pathway (p65 and p50) and alternative pathway (p52) of NF- $\kappa$ B. We evaluated the expression of NF- $\kappa$ B proteins in relation to the postulated cell of origin (GC versus non-GC B-cell/activated B-cell). Furthermore, we correlated the clinical parameters with the immunohistochemical results.

## Materials and Methods

Fifty cases of primary lymphoma of bone were investigated, 27 were collected at the Leiden University Medical Center (Leiden, The Netherlands) and 23 at the Semmelweis University (Budapest, Hungary). According to the WHO classification<sup>(1)</sup> PLB was defined as a histologically proven non Hodgkin lymphoma arising within the medullary cavity of a bone, with or without regional lymph node involvement, but without evidence of other extranodal involvement, or as non Hodgkin lymphoma with multiple bone involvement without lymph node or visceral involvement. Staging procedures included Computed Tomography scan, iliac crest bone marrow biopsy and total blood count. The pathological diagnosis was established according to the WHO classification<sup>(15)</sup> using standard histological criteria and immunohistochemical staining procedures. All cases selected were reviewed independently by at least two pathologists. The samples were handled in a coded fashion, and all procedures were performed according to the ethical guidelines, 'Code for Proper Secondary Use of Human Tissue in The Netherlands' (Dutch Federation of Medical Scientific Societies).

### Tissue microarray

Tissue microarrays were prepared using hematoxylin and eosin (H&E) stained sections from each paraffin-embedded, formalin-fixed block to select tumor rich areas. Accordingly, 3 representative 2-3 mm cores were obtained from each case and inserted in a grid pattern into a recipient paraffin block using a tissue arrayer device (TMA Master, 3D Histech Ltd, Budapest, Hungary).

### Antibodies and Immunohistochemistry

Immunohistochemical staining was performed on 4  $\mu$ m paraffin sections using standard procedures. After antigen retrieval by boiling for 10 minutes in 10 mmol/L citrate buffer (pH 6.0, tissue sections were incubated overnight with p50 (dilution 1:200, Abcam, Cambridge, UK), p52 (18D10) (dilution 1:100, Cell Signaling Technology, Beverly, MA, USA) and p65 (dilution 1:200, Neomarkers, Fremont, CA, USA). Sections were then incubated for 30 minutes with PowerVision Poly-horseradish peroxidase. Subsequently, a 10-minute incubation with diaminobenzidine (DAB) solution (Sigma-Aldrich, Zwijndrecht, The Netherlands) was performed. Finally, all slides were counterstained with Mayer's haematoxylin. Immunohistochemical stainings for BCL6, CD10 and IRF4/MUM1 were performed as previously described.<sup>(6)</sup>

### Immunohistochemical Scoring

NF- $\kappa$ B expression was detected as nuclear and/or cytoplasmic staining of tumor cells for p50, p52 and/or p65. Nuclear staining was scored according to the estimated percentage of positive tumor cells; less than 10%, 10-20%, 20-30% or more than 30%, irrespective of cytoplasmic staining. In the largest cohort of DLBCL published thus far<sup>(10)</sup>, cases were considered to be



positive for NF- $\kappa$ B activity when  $\geq 30\%$  of tumor cells showed nuclear staining. In our series, cases showed either virtually no nuclear staining ( $< 10\%$ , merely scattered positive tumor cells), or staining of 20% or more for p50 and p52. Because of this dichotomy, we considered cases of more than 20% positive tumor cells positive for nuclear staining. Tonsil sections were used as positive controls. As an extrinsic control group, paraffin sections of cases of nodal DLBCL and primary central nervous system DLBCL were also stained, since these groups have been previously reported to immunohistochemically express nuclear p50 and p52<sup>(11)</sup> and nuclear p65,<sup>(16)</sup> respectively.

## Results

### Patient characteristics

Patient characteristics are summarized in Table 1, subdivided by GC or non-GC phenotype as defined by diagnostically performed immunohistochemical staining procedures for CD10, BCL-6 and IRF4/MUM1, according to the Hans' algorithm. All stage IV patients had multifocal osseous disease without lymph node or visceral involvement. Forty-three patients received multagent chemotherapy, of which 9 were additionally treated with rituximab.

### NF- $\kappa$ B expression

Nuclear immunohistochemical expression of p50 was detected in 9 cases (18%, see Figure 1), whereas almost all other cases just showed cytoplasmic expression throughout the tumor tissue. Nuclear expression of p50 was equally distributed between the GC- and non-GC type of PLB as determined by Hans' algorithm (see Table 2).

P52 showed nuclear expression of 20-30% of tumor cells in only one case. This case was a non-GC type PLB, and also showed nuclear p50 positivity in more than 30% of tumor cells. After a follow-up of ten years, this patient was still alive without recurrence of disease after polychemotherapy treatment.

Staining procedures for p65 did not show significant nuclear staining. Only scattered cells were considered positive (scored as less than 10% nuclear staining), while cytoplasmic staining in virtually all tumor cells was detected in 46 and 43 cases respectively.

None of the nuclear p50 positive cases presented with a recurrence or progression of disease, although for one of the positive cases, no follow-up data were available. Furthermore, exploring known prognostic factors in PLB, p50 positivity was evenly distributed between patients under and over 60 years of age and was not related to disease stage at time of presentation.

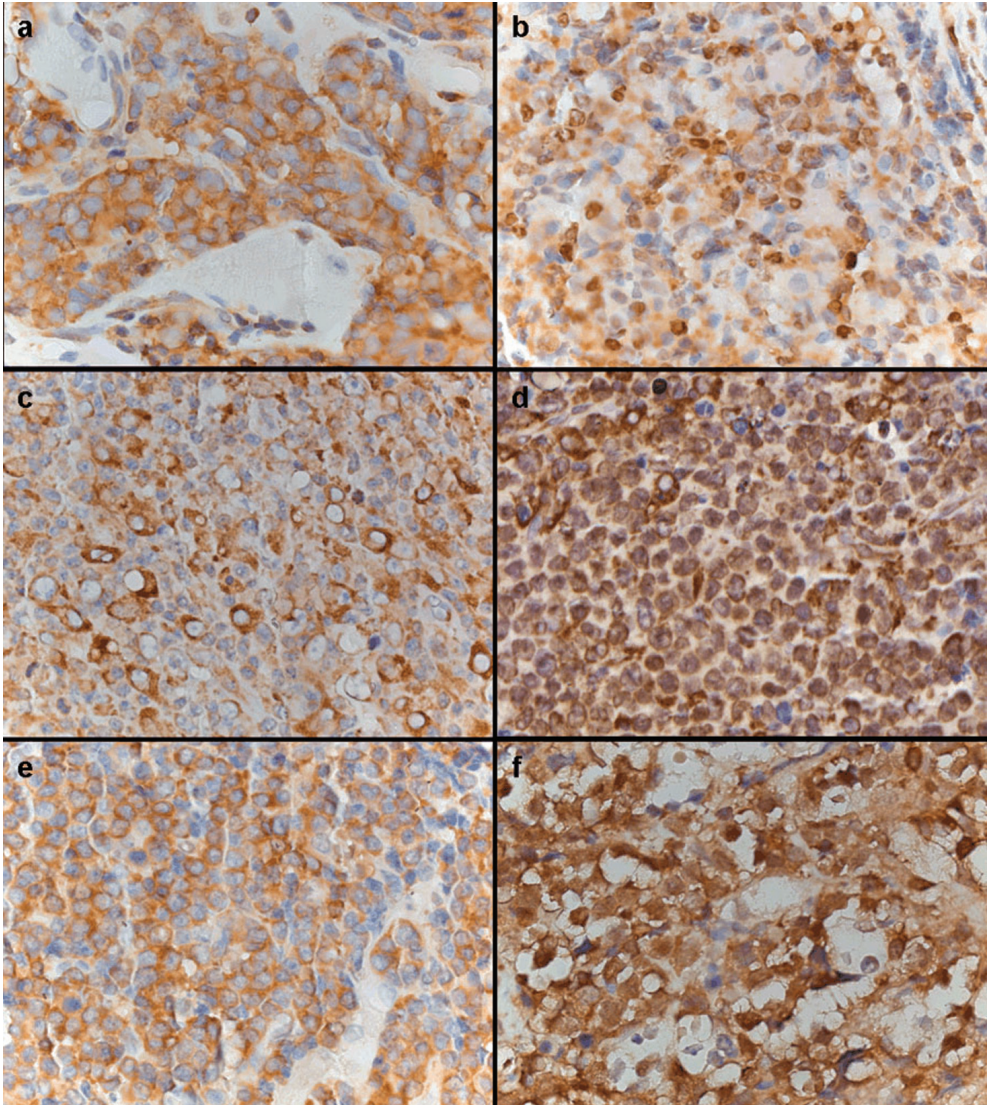
## Discussion

The NF- $\kappa$ B comprises of a family of transcription factors that control genes that play critical roles in B-cell activation, proliferation and resistance to apoptosis. The NF- $\kappa$ B family has five members: p65 (RelA), p50 (NF- $\kappa$ B1), p52 (NF- $\kappa$ B2), RelB and c-Rel. In unstimulated human

**Table 1:** Patient characteristics.

	all 50	GC-type 25	non-GC-type 25
Sex			
male	32	16	16
female	18	9	9
Age (years)			
mean	49	50	47
range	18-78	18-78	20-72
Location			
femur	25	11	14
humerus	6	5	1
os ileum	6	3	3
vertebra	5	3	2
other	8	3	5
Stage			
I	33	17	16
II	4	0	4
III	0	0	0
IV	11	8	3
unknown	2	0	2
Treatment			
PCT + RT	25	13	12
PCT + RT	14	5	9
RT + resection	6	4	2
PCT + RT + resection	3	1	2
PCT + resection	1	1	0
unknown	1	1	0
Outcome			
complete response	37	19	18
partial response	3	0	3
progressive disease	7	4	3
unknown	3	2	1
Recurrence			
yes	2	1	1
no	45	22	23
unknown	3	2	1
Status			
A-	37	19	18
A+	0	0	0
D-	1	0	1
D+	9	4	5
unknown	3	2	1
Follow-up (months)			
mean	57	52	62
range	0-240	0-192	0-240

GC-type: germinal center phenotype, non-GC-type: non germinal center phenotype, PCT: polychemotherapy, RT: radiotherapy, A-: alive without evidence of disease, A+: alive with evidence of disease, D-: died of causes unrelated to disease, D+: died of causes related to disease



**Figure 1:** Immunohistochemical staining of nuclear factor- $\kappa$ B pathway members.

The majority of cases of primary lymphoma of bone merely showed cytoplasmic staining of the tumor cells for p50 (a) and p52 (c). P65 was only detected in the cytoplasm of tumor cells (e), while p50 and p52 showed nuclear staining in part of the tumor cells (b,d). P65 was not detected in the nucleus of tumor cells in primary lymphoma of bone (e). However, cases of primary central nervous system diffuse large B-cell lymphoma did show significant nuclear staining (f) and served as an external positive control.

**Table 2:** Nuclear immunohistochemical positivity for p50.

	All	GC-type	non-GC-type
<10%	41	21	20
10-20%	0	0	0
20-30%	2	0	2
>30%	7	4	3

GC-type: germinal center type, non-GC-type: non germinal center type.

cells, these NF- $\kappa$ B proteins and their precursor proteins reside in the cytoplasm in an inactive form bound to NF- $\kappa$ B inhibitory proteins (I $\kappa$ Bs). The NF- $\kappa$ B pathway signals downstream after activation through different kinds of surface receptors, including the B-cell receptor. Two major signaling pathways account for the activation of NF- $\kappa$ B. In the canonical pathway, signal transduction events lead to activation of the I $\kappa$ B kinase complex resulting in phosphorylation and proteasomal degradation of I $\kappa$ B. Heterodimers and homodimers of p50, p65 and c-Rel can then be translocated to the nucleus to regulate gene transcription. The alternative pathway is characterized by I $\kappa$ B kinase complex activation through NF- $\kappa$ B induced kinase, eventually leading to processing of the p52 precursor subunit into active p52 translocating to the nucleus and forming a heterodimeric complex with RelB.<sup>(17;18)</sup> The clinical importance of the two different pathways of activation includes the potential of targeted therapy directed against NF- $\kappa$ B activation, as some specific inhibitors only target one of both activation pathways.<sup>(19)</sup>

This is the first study reporting on NF- $\kappa$ B activation in PLB. In our cohort, 18% of cases demonstrated nuclear positivity for p50, suggesting constitutive activation of the classical NF- $\kappa$ B pathway in a minority of PLB. Only one case showed significant nuclear positivity for p52, which implies that constitutive activation of NF- $\kappa$ B through the alternative pathway may not play a significant role in PLB. This is in contrast to previous reports showing nuclear staining for p52 in one-third (ABC-type) to one-fifth (GCB-type) of cases of nodal DLBCL.<sup>(11)</sup> We could not demonstrate co-localization of p65 with p50 in the nucleus, which is in line with recent results in nodal DLBCLs<sup>(20)</sup>. Interestingly, nuclear immunohistochemical staining for p65 was observed in primary central nervous system DLBCL and primary cutaneous DLBCL, two other variants of extranodal DLBCL.<sup>(16;21)</sup> It would be interesting to investigate whether the lack of nuclear staining for p65 indicates that another form of constitutive activation of NF- $\kappa$ B is involved in PLB, possibly by forming p50 homodimers in the nucleus or by co-localizing with C-Rel.

A considerable amount of nodal DLBCLs are known to show constitutive activation of NF- $\kappa$ B. In non-GC DLBCLs, gene set enrichment analysis showed high NF- $\kappa$ B transcriptional activity in >95% of cases, whereas this percentage was 47% in GC DLBCL. Immunohistochemical staining procedures in the same group showed nuclear localization of p50 and/or p52 in 61% and 30%, respectively.<sup>(11)</sup> Although this difference might be interpreted as a result of lower

sensitivity of immunohistochemical staining to detect aberrant NF- $\kappa$ B activity, it may also reflect the inability of gene set enrichment analysis to discriminate signals deriving from infiltrating reactive cells. Indeed, in our series, small infiltrating T-lymphocytes did also show nuclear staining for some of the NF- $\kappa$ B family members. Therefore, it seems reasonable to assume that immunohistochemistry may be a surrogate marker for determining constitutive activation of NF- $\kappa$ B.

Although constitutive activation of NF- $\kappa$ B in nodal DLBCL was not restricted to the non-GC type, a marked preference for non-GC tumors was observed <sup>(11)</sup>. In our cohort, nuclear expression of p50 was not confined to the tumors with a non-GC phenotype and was evenly distributed between GC- and non-GC like tumors. Activation of the NF- $\kappa$ B pathway as shown by upregulated gene expression of different NF- $\kappa$ B target genes is even considered as a specific gene array signature of the ABC/non-GC type DLBCL <sup>(12)</sup>. It therefore seems remarkable that in our series only 20% of non-GC type PLBs showed nuclear p50 staining. These results once more emphasize the heterogeneity of nodal and extranodal DLBCLs and of the different types of extranodal lymphomas.

It is hypothesized that NF- $\kappa$ B activation plays a role in chemotherapy resistance and a subsequent poor outcome in different types of lymphomas, by promoting cell proliferation, blocking apoptosis and potentially blocking differentiation and promoting metastases.<sup>(22;23)</sup> As PLB generally has an excellent prognosis, relating nuclear p50 staining to survival may not be relevant. Nevertheless, in our cohort, all patients with nuclear positivity for p50 are still alive without disease. This implies that p50 positivity in PLB is not a negative prognostic factor, and that constitutive activation of NF- $\kappa$ B is not likely to be significantly involved in (chemo) therapy-resistance in the minority of PLB cases that show progressive disease.

In conclusion, our results show that NF- $\kappa$ B activation through the classical pathway is seen in a minority of cases of PLB and is evenly distributed among cases with a non-GC or GC phenotype. Therefore, in contrast to nodal DLBCL, the NF- $\kappa$ B pathway does not appear to be an attractive pathway for targeted therapy in PLB.

## References

- (1) Fletcher C.D.M, Unni K.K., Mertens F. World Health Classification of Tumours: Tumours of Soft Tissue and Bone. Malignant Lymphoma. 306-308. 2010.
- (2) Lopez-Guillermo A, Colomo L, Jimenez M, Bosch F, Villamor N, Arenillas L, Muntanola A, Montoto S, Gine E, Colomer D, Bea S, Campo E, Montserrat E. Diffuse large B-cell lymphoma: clinical and biological characterization and outcome according to the nodal or extranodal primary origin. *J Clin Oncol* 2005 Apr 20;23(12):2797-804.
- (3) Heyning FH, Kroon HM, Hogendoorn PC, Taminau AH, van der Woude HJ. MR imaging characteristics in primary lymphoma of bone with emphasis on non-aggressive appearance. *Skeletal Radiol* 2007 Oct;36(10):937-44.
- (4) Beal K, Allen L, Yahalom J. Primary bone lymphoma: treatment results and prognostic factors with long-term follow-up of 82 patients. *Cancer* 2006 Jun 15;106(12):2652-6.
- (5) Heyning FH, Hogendoorn PC, Kramer MH, Hermans J, Kluin-Nelemans JC, Noordijk EM, Kluin PM. Primary non-Hodgkin's lymphoma of bone: a clinicopathological investigation of 60 cases. *Leukemia* 1999 Dec;13(12):2094-8.
- (6) Heyning FH, Hogendoorn PC, Kramer MH, Holland CT, Dreef E, Jansen PM. Primary lymphoma of bone: extranodal lymphoma with favourable survival independent of germinal centre, post-germinal centre or indeterminate phenotype. *J Clin Pathol* 2009 Sep;62(9):820-4.
- (7) Adams H, Tzankov A, d'Hondt S, Jundt G, Dirnhofer S, Went P. Primary diffuse large B-cell lymphomas of the bone: prognostic relevance of protein expression and clinical factors. *Hum Pathol* 2008 Sep;39(9):1323-30.
- (8) de Leval L, Braaten KM, Ancukiewicz M, Kiggundu E, Delaney T, Mankin HJ, Harris NL. Diffuse large B-cell lymphoma of bone: an analysis of differentiation-associated antigens with clinical correlation. *Am J Surg Pathol* 2003 Sep;27(9):1269-77.
- (9) Bhagavathi S, Micale MA, Les K, Wilson JD, Wiggins ML, Fu K. Primary bone diffuse large B-cell lymphoma: clinicopathologic study of 21 cases and review of literature. *Am J Surg Pathol* 2009 Oct;33(10):1463-9.
- (10) Heyning FH, Jansen PM, Hogendoorn PC, Suzhai K. Array-based comparative genomic hybridisation analysis reveals recurrent chromosomal alterations in primary diffuse large B cell lymphoma of bone. *J Clin Pathol* 2010 Oct 20.
- (11) Compagno M, Lim WK, Grunn A, Nandula SV, Brahmachary M, Shen Q, Bertoni F, Ponzoni M, Scandurra M, Califano A, Bhagat G, Chadburn A, Dalla-Favera R, Pasqualucci L. Mutations of multiple genes cause deregulation of NF-kappaB in diffuse large B-cell lymphoma. *Nature* 2009 Jun 4;459(7247):717-21.
- (12) Davis RE, Brown KD, Siebenlist U, Staudt LM. Constitutive nuclear factor kappaB activity is required for survival of activated B cell-like diffuse large B cell lymphoma cells. *J Exp Med* 2001 Dec 17;194(12):1861-74.
- (13) Ngo VN, Davis RE, Lamy L, Yu X, Zhao H, Lenz G, Lam LT, Dave S, Yang L, Powell J, Staudt LM. A loss-of-function RNA interference screen for molecular targets in cancer. *Nature* 2006 May 4;441(7089):106-10.
- (14) Lam LT, Davis RE, Pierce J, Hepperle M, Xu Y, Hottel M, Nong Y, Wen D, Adams J, Dang L, Staudt LM. Small molecule inhibitors of IkappaB kinase are selectively toxic for subgroups of diffuse large B-cell lymphoma defined by gene expression profiling. *Clin Cancer Res* 2005 Jan 1;11(1):28-40.
- (15) Harris NL. Mature B-cell neoplasms. In: Swerdlow SH, Campo E, Harris NL, Jaffe ES, Pileri SA, Stein H, Thiele J, Vardiman JW, editors. WHO Classification of Tumours of Haematopoietic and Lymphoid Tissues. Lyon: IARC Press; 2008. p. 179-267.


- 
- (16) Courts C, Montesinos-Rongen M, Martin-Subero JI, Brunn A, Siemer D, Zuhlke-Jenisch R, Pels H, Jurgens A, Schlegel U, Schmidt-Wolf IG, Schaller C, Reifenberger G, Sabel M, Warnecke-Eberz U, Wiestler OD, Kuppers R, Siebert R, Deckert M. Transcriptional profiling of the nuclear factor-kappaB pathway identifies a subgroup of primary lymphoma of the central nervous system with low BCL10 expression. *J Neuropathol Exp Neurol* 2007 Mar;66(3):230-7.
  - (17) Perkins ND. Integrating cell-signalling pathways with NF-kappaB and IKK function. *Nat Rev Mol Cell Biol* 2007 Jan;8(1):49-62.
  - (18) Sun SC, Ley SC. New insights into NF-kappaB regulation and function. *Trends Immunol* 2008 Oct;29(10):469-78.
  - (19) Baud V, Karin M. Is NF-kappaB a good target for cancer therapy? Hopes and pitfalls. *Nat Rev Drug Discov* 2009 Jan;8(1):33-40.
  - (20) Espinosa I, Briones J, Bordes R, Brunet S, Martino R, Sureda A, Sierra J, Prat J. Activation of the NF-kappaB signalling pathway in diffuse large B-cell lymphoma: clinical implications. *Histopathology* 2008 Oct;53(4):441-9.
  - (21) Bhagavathi S, Blenc AM, Amin M, Nikitin VD, Patel MC, Warren S, Malhotra RK. Primary cutaneous large B-cell lymphoma shows activation of nuclear factor kappa B and low incidence of Epstein-Barr virus. *Am J Dermatopathol* 2010 Jul;32(5):439-41.
  - (22) Baldwin AS. Control of oncogenesis and cancer therapy resistance by the transcription factor NF-kappaB. *J Clin Invest* 2001 Feb;107(3):241-6.
  - (23) Dunleavy K, Pittaluga S, Czuczman MS, Dave SS, Wright G, Grant N, Shovlin M, Jaffe ES, Janik JE, Staudt LM, Wilson WH. Differential efficacy of bortezomib plus chemotherapy within molecular subtypes of diffuse large B-cell lymphoma. *Blood* 2009 Jun 11;113(24):6069-76.





# Chapter 7

**Summary,  
general discussion and  
future perspectives**





Since Oberling first mentioned primary lymphoma of bone in 1928 as a distinct entity, knowledge on lymphoma in general has increased substantially. The improvements in diagnosis and treatment of primary diffuse large B lymphoma of bone in over eighty years has changed treatment from amputation of an extremity to combined chemo- and radiotherapy. The earlier treatment of amputation usually resulted in complete remission, but with a high treatment related morbidity.

Primary diffuse large B cell lymphoma of bone however has remained somewhat of an outcast in lymphoma literature and in clinical practice. The incidence is low, although with the establishment of immunohistochemical markers for monoclonal B-cells the entity has become easier to recognize. Currently there is the suggestion that the frequency of occurrence might have been underestimated in the past. While the diagnostic improvements have helped the patient, ironically it has had an adverse effect on research, since less tumor material is sent to referral hospitals or registries such as the Netherlands Committee on Bone Tumors for advice. In general hospitals extranodal lymphoma of any particular site is not always documented as such, which makes it more difficult to find adequate patient numbers for research purposes. Moreover, there are often technical difficulties in handling the osseous tumor material, which hampers scientific research as well. This most likely explains the few studies on primary diffuse large B cell lymphoma of bone in literature, with often small patient numbers and poorly compatible cohorts. By definition, primary lymphoma of bone excludes secondary bone localization of nodal lymphoma, but when a patient presents with stage IV primary lymphoma of bone at different skeletal sites, it can be difficult to exclude primary nodal disease. For this reason, stage IV patients are often excluded in primary lymphoma of bone studies, causing an incomplete representation of the clinical spectrum. Although clinical stage is defined as a negative prognostic factor, the stage four cases often do reach complete remission. It was therefore important to us to include all tumor stages in our study cohorts.

This thesis describes the first extensive multidisciplinary study on primary diffuse large B cell lymphoma of bone with large patient numbers, including our cohort of 60 cases in **chapter two**. When studied in large numbers, it is noticeable how homogeneous the clinico-pathological presentation of primary diffuse large B cell lymphoma of bone in fact is. The tumor presents in either the femur or the humerus in over 50% of the cases, the stage of the disease is most often stage I with pain usually as the presenting symptom. The clinical outcome following therapy including chemotherapy and irradiation is complete remission in most cases, with a low incidence of recurrent disease. Morphologically, the tumor most frequently consists of large centroblastic cells with either multilobated features or mono-/polymorphic features, although some cases with an immunoblastic tumor cell phenotype are also encountered. The treatment schedules varied in this cohort, from surgery and radiotherapy to CHOP multi-agent chemotherapy and radiotherapy. The 5 year overall survival in our series for the whole cohort was 61%. No significant difference was found between the different treatment schedules, as long as a combination of radiotherapy and chemotherapy was given. We demonstrated that the IPI risk factors age at presentation and stage of disease have a negative influence on prognosis

in primary lymphoma of bone. We did not find a significant impact on prognosis of tumor localization, which is opposite earlier reported findings. We found a trend towards worse survival for the immunoblastic tumor subtype, as it was called at that time, as compared to the centroblastic mono-/polymorphic or multilobated tumor subtype according to the updated Kiel classification.

Of note, as we describe in **chapter three**, the clinico-pathological homogeneity is in contradiction with the radiological characteristics of the disease. We discovered that the MRI image of primary diffuse large B cell lymphoma of bone can be rather deceptive. We studied the MRI characteristics of 29 bone lymphoma patients. We found that the MRI features are not uniform at all. The majority of the patients displayed a combination of definite cortical abnormalities and extension to the soft tissue, but up to 31% of the patients showed MRI features that looked radiologically non-aggressive or even benign. The study stresses the need for accurate core biopsy to establish a definite diagnosis of primary diffuse large B cell lymphoma of bone, following adequate local imaging including MRI.

We have used various techniques to identify parameters for risk stratification in primary diffuse large B cell lymphoma of bone patients. In **chapter four**, we determined the prognostic significance of several immunohistochemical markers: BCL-6, CD10, MUM1, BCL-2, p53, CD30 and CD44. We also investigated the possible germinal center derivation of primary diffuse large B cell lymphoma of bone. Applying the Hans' algorithm, which is an algorithm using immunohistochemical staining results for BCL-6, CD10 and MUM1 to determine the germinal center B-cell subtype of diffuse large B-cell lymphoma versus the non-germinal center B-cell subtype, we concluded that 19 out of a cohort of 36 cases displayed a germinal center-like phenotype. Eight of 36 cases demonstrated a non-germinal center-like phenotype, whereas nine of 36 cases were of indeterminate phenotype. No significant difference in survival was found between the different tumor phenotypes, nor for the tested immunohistochemical markers individually. We did find again a statistically significant influence on prognosis of the IPI risk factors age at presentation and stage of disease. This confirmed our findings from our earlier study (chapter two), although this might be partially explained by the fact that some patients were included in both study cohorts.

In **chapter five**, we described the first array-CGH study of primary diffuse large B cell lymphoma of bone, in which we investigated genomic alterations in nine such cases. We found several recurrent genomic aberrations, but none had statistically significant prognostic influence. The most frequent finding was five cases with gain of 1q (five out of nine cases) and 2p16.1 amplification (four out of nine cases). The amplified region 2p16.1 encodes for the proto-oncogene REL, a transcription factor of the NF- $\kappa$ B family.

In **chapter six** we described the first study on NF- $\kappa$ B pathway activation in primary diffuse large B cell lymphoma of bone. This signaling pathway is known to have a role in tumorigenesis in lymphoma; recent research has focused on elucidating its working mechanisms through the classical pathway and the alternative pathway and on its possible role in targeted therapy. We investigated 50 cases for involvement of aberrant NF- $\kappa$ B activation by performing

immunohistochemical stainings for different NF- $\kappa$ B family members and evaluated its possible prognostic influence. In a minority (19%) of cases, we found substantial nuclear staining of p50, as an indication of aberrant activation of the classical pathway of NF- $\kappa$ B activation, while alternative activation did not appear to be significantly involved. The nuclear expression of p50 was not preferentially detected in non-germinal center or germinal center type cases, nor related to an inferior prognosis.


The knowledge of this rare type of extranodal non-Hodgkin lymphoma has increased by describing the complete clinicopathological spectrum of primary diffuse large B cell lymphoma of bone, including clinical characteristics, radiological aspects and molecular genetic factors. When we studied this disease in a large number of patients it became clear that primary diffuse large B cell lymphoma of bone is a homogeneous entity with a favorable outcome, contrary to what was earlier believed for extranodal lymphoma in general and primary diffuse large B cell lymphoma of bone in particular. We have demonstrated that primary diffuse large B cell lymphoma of bone is often of germinal center cell derivation, but the associated favorable outcome was also seen in cases with characteristics of the non-germinal center phenotype. Interestingly, in our first study we did find a worse outcome for the so-called immunoblastic tumor subtype, which largely corresponds to the non-germinal center phenotype. In later studies we could not confirm this trend. We could not identify any statistically significant molecular-biological prognostic parameters. We think this is explained partly by the favorable survival of our cohort, with very similar morphology, phenotype and clinical course for the majority of the cases. This positive and homogeneous clinical course results in few statistical events.

The pathogenesis of primary diffuse large B cell lymphoma of bone is unknown. Most cases probably arise de novo without a recognizable initial noxe; more specifically there is no relationship with a history of osteomyelitis or fracture. Of note, of all the prognostic parameters that we studied, the clinical parameters, especially the IPI risk factors age at presentation and stage of disease, have the strongest influence on prognosis.

We hope that this thesis on primary diffuse large B cell lymphoma of bone, a rare and fascinating subtype of extranodal lymphoma, will ultimately help to improve the treatment of diffuse large B cell lymphoma patients.



# **Nederlandse samenvatting**







## **Algemene inleiding**

Primair bot lymfoom is een zeldzame aandoening. Het is een extranodaal subtype van het grootcellig B non Hodgkin lymfoom, dat zich meestal presenteert in de lymfeklieren (nodale subtype). De eerste keer dat deze ziekte als aparte entiteit werd erkend in de wetenschappelijke literatuur was in 1928, maar het duurde nog tot 1963 voordat de term bot lymfoom officieel erkend en gebruikt werd. Dat dit zo lang duurde heeft verschillende oorzaken. Ten eerste is een primair bot lymfoom zeldzaam. Zoals al eerder is gezegd komt een lymfoom meestal voor in de lymfeklieren, en als het zich al in de botten presenteert, dan is het meestal een secundaire localisatie van een lymfoom dat zich oorspronkelijk in de lymfeklieren manifesteerde. Ten tweede is de diagnostiek van een bot lymfoom niet eenvoudig. Er kan makkelijk verwarring ontstaan met bijvoorbeeld een sarcoom of juist een benigne aandoening zoals een bot infectie. Pas sinds de komst van moderne, gestandaardiseerde diagnostische technieken, zoals de immunohistochemie sinds 1987, kan in moeilijke gevallen de diagnose toch met zekerheid gesteld worden.

## **Nederlandse Commissie van Beentumoren**

In 1953 werd de Nederlandse Commissie van Beentumoren opgericht in Leiden. Dit is een groot nationaal archief waarin alle maligne bontumoren in Nederland worden geregistreerd. Inmiddels bevat het archief meer dan 25.000 casus, alle inclusief klinische gegevens bij presentatie, follow-up, radiologie en histologische coupes. Dit archief bood de unieke kans om een groot cohort van primair bot lymfoom patienten samen te stellen; op dit moment is ons cohort een van de grootste wereldwijd. De opbouw van dit cohort was het startpunt van dit onderzoek.

## **Klinisch-pathologische kenmerken**

Primair bot lymfoom komt het meeste voor in de lange pijpbeenderen, het meest frequent in het bovenbeen of de bovenarm. De gemiddelde leeftijd bij presentatie is in de vijfde decade. De ziekte komt vaker bij mannen voor dan bij vrouwen, in een ratio van 1.8 : 1. Morfologisch hebben de tumoren grote centroblast-achtige cellen met multilobulaire kenmerken. De morfologische classificatie wordt vaak bemoeilijkt door mechanische schade aan het biopt, ontkalkingsprocedures en relatief weinig tumor cellen in het biopt.

De behandeling bestaat tegenwoordig uit R-CHOP chemokuren, vaak nog gevolgd door bestraling. Vroeger, tot eind jaren zeventig, werd in het algemeen het aangedane lichaamsdeel geamputeerd. De prognose voor botlymfoom patienten is in het algemeen gunstig, met een vijfjaars overleving van 75% voor de gehele groep, en meer dan 90% voor stadium I patienten.

## **Risicofratificatie in diffuus grootcellig B Non Hodgkin lymfoom**

Diffuus grootcellig B Non Hodgkin lymfoom is een zeer heterogene groep van tumoren met sterk uiteen lopende ziektebeelden en prognoses. Er zijn reeds vele onderzoeken gedaan om binnen deze groep risicofratificatie systemen te ontwerpen en prognostische indicatoren

te definiëren om patienten te identificeren die zwaardere behandeling nodig zullen hebben dan het standaard regime van R-CHOP. Een van de eerste risicoclassificatie systemen was de internationale prognostische index, IPI genoemd. Deze index werd ontworpen in 1993, en deelt de patienten in op grond van een score voor de klinische parameters leeftijd, conditie, LDH waarde in het bloed, aantal aangedane extranodale klieren en ziekte stadium. Deze index werkt goed voor nodale lymfomen, maar veel minder voor extranodale subtypes.

Een modernere manier om non Hodgkin lymfoom patienten in te delen in prognostische subgroepen maakt gebruik van de moleculair genetische kenmerken van de tumorcellen. Met behulp van gen-expressie profilering worden twee tumor types onderscheiden: het kiemcentrum fenotype en het zogenaamde “geactiveerde B cell” type. Het laatste tumortype heeft een slechtere prognose, onafhankelijk van klinische parameters. Tegenwoordig is het mogelijk om met een eenvoudiger techniek, dat wil zeggen immunohistochemie op paraffine coupes, toch deze indeling te maken. Dat maakt het mogelijk om deze risicoclassificatie ook te gebruiken in een algemeen ziekenhuis zonder speciale onderzoeksfaciliteiten.

Met meer verfijnde technieken, die wel alleen in onderzoeks context worden gebruikt op dit moment, zoals array-based comparative genomic hybridization analysis wordt op dit moment gezocht naar aanvullende prognostische parameters. Alhoewel er verschillende kandidaat parameters zijn, is deze risicoclassificatie nog onvoldoende uitgekristalliseerd om op brede schaal al toe te kunnen passen.

In **hoofdstuk twee** hebben we de tumormorfologie en het klinische beloop van 60 patienten bestudeerd, waarbij we hebben gezocht naar prognostisch significantefactoren voor dit lymfoom type. We hebben onder andere tumorsubtype, wijze van behandeling en de parameters van de internationale prognostische index getest op hun waarde bij het primaire bot lymfoom. Tumor subtype en leeftijd bij presentatie bleken het meest significant van invloed op de prognose bij deze groep patienten.

In **hoofdstuk drie** hebben we de MRI karakteristieken van 29 bot lymfoom patienten onderzocht. De wetenschappelijke literatuur over dit onderwerp is schaars en niet eenduidig. In tegenstelling tot wat eerdere studies concluderen hebben wij geen uniform MRI beeld kunnen vaststellen. Ook bij MRI diagnostiek is het moeilijk om een botlymfoom te onderscheiden van een andere maligne bottumor of van een botontsteking. Het blijft dus uitermate belangrijk om in een dergelijke situatie een biopsie van het afwijkende bot gedeelte te nemen. Om geen storing van het radiologische beeld door de biopsie te veroorzaken dient de biopsie na de radiologische documentatie, inclusief de MRI plaats te vinden.

In **hoofdstuk vier** hebben we diverse immunohistochemische markers onderzocht en hun associatie van expressie op de prognose van primair bot lymfoom patienten vastgesteld. Door technische moeilijkheden met het kalkhoudende materiaal van botlymfomen was dit type onderzoek eerder nog maar weinig gedaan. In ons onderzoek hebben we geen individuele markers gevonden die een significante invloed hebben op de prognose van primair bot lymfoom. Met behulp van het zogenaamde Hans’ algoritme, een methode om het tumor fenotype door middel van drie immunohistochemische markers vast te stellen, hebben we

gevonden dat ongeveer vijftig procent van de patienten een kiemcentrum fenotype heeft, een type met een meestal gunstige prognose.

In **hoofdstuk vijf** hebben we de eerste array-CGH studie op bot lymfomen in de wetenschappelijke literatuur beschreven. We hebben met behulp van deze techniek 9 tumoren onderzocht op het aantal genoom veranderingen dat daarin voorkomt. Ons resultaat was dat er bij deze bot tumoren meerdere genoom veranderingen te vinden zijn die ook al in andere lymfoom types zijn beschreven. Deze veranderingen worden meestal geassocieerd met een gunstige prognose, maar ook hierin is de literatuur niet eenduidig. Ook met deze techniek is weer een indeling naar tumor fenotype mogelijk. Wij konden in dit kleine cohort onze eerdere bevinding dat meer dan vijftig procent van het kiemcentrum fenotype is, bevestigen. Wij hebben echter geen statistisch significant effect op prognose kunnen vinden.

In **hoofdstuk zes** hebben we NF- $\kappa$ B activatie in primair bot lymfoom beschreven. NF- $\kappa$ B speelt een belangrijke rol in cel proliferatie en regulatie van apoptose. Bovendien wordt steeds meer bekend over de rol van NF- $\kappa$ B in het ontstaan van maligne lymfomen. NF- $\kappa$ B activatie verloopt via twee verschillende mechanismes, de klassieke weg en de alternatieve weg. De klassieke activatie weg wordt vaker gevonden in tumoren van het kiemcentrum fenotype. De alternatieve activatie weg wordt meer beschreven in tumoren van het geactiveerde B cell fenotype en is geassocieerd met een ongunstige prognose. Wij hebben in onze studie uitsluitend activatie van de klassieke weg gevonden. Interessant genoeg was de activatie niet beperkt tot tumoren van het kiemcentrum fenotype in ons cohort. Wij hebben geen negatieve invloed op de prognose gevonden.


## Conclusies

Primair bot lymfoom is een zeldzaam subtype van diffuus grootcellig B non Hodgkin lymfoom. De klinische presentatie en de histologische morfologie is zeer homogeen, echter de radiologische presentatie is divers. Over het algemeen is het ziektebeloop gunstig, met een vijf jaars overleving van stadium I patienten van meer dan 90%. Van de tot nu toe bekende prognostische parameters bij grootcellig B non Hodgkin lymfoom hebben leeftijd bij presentatie en stadium van de ziekte een statistisch significante invloed bij primair botlymfoom. Van het tumor fenotype, in meerderheid kiemcentrum fenotype, en genomische aberraties hebben we geen statistisch significante invloed aan kunnen tonen.

Deze studie van een zeldzaam type extranodaal lymfoom heeft een bijdrage proberen te leveren aan het ontrafelen van de heterogene groep van ziekten die onder de noemer diffuus grootcellig B non Hodgkin lymfoom wordt geschaard. Door onderzoek naar de verschillende subtypes van deze grote groep lymfomen zal uiteindelijk duidelijk worden welke gemeenschappelijke pathofysiologische mechanismen deze groep binden en welke mechanismen subtype specifiek zijn. Een beter begrip van het ontstaan van grootcellig B lymfomen zal uiteindelijk leiden tot een betere behandeling van de patient met deze ziekte.



# Curriculum Vitae






De auteur van dit proefschrift werd geboren op 30 november 1970 te Leiden. In 1989 behaalde zij het eindexamen Gymnasium  $\beta$  aan het Stedelijk Gymnasium Haarlem. Aansluitend studeerde zij een jaar aan de Wittenberg University, Springfield, Ohio, Verenigde Staten, met een beurs van de NACEE (Netherlands America Committee for Educational Exchanges). In 1990 begon zij aan de studie Geneeskunde aan de Rijksuniversiteit Leiden. Voorafgaand aan haar doctoraal examen in 1995 deed zij eerst acht maanden onderzoek naar primaire bot lymfomen op de afdeling Pathologie (Prof.dr. P.C.W. Hogendoorn) en vervolgens vier maanden onderzoek naar Multipele Sclerose aan de University of Pennsylvania, Philadelphia, Verenigde Staten (Prof.dr.M.A. van Buchem). Het artsexamen werd behaald in 1997 waarna zij vier maanden onderzoek deed naar tuberculose in Kabale, Uganda (Dr.D.Overbosch). In 1998 begon zij haar opleiding tot internist in het Ziekenhuis Bronovo te Den Haag (opleider dr. R. Bieger en dr.J. van 't Wout). De opleiding werd in 2001 voortgezet in het LUMC (Prof.dr.A.E. Meinders), leidend tot registratie als internist in 2004. Vanaf september 2003 tot september 2005 was zij werkzaam op de afdeling Hematologie van het LUMC, resulterend in de registratie als hematoloog in 2006 (opleider Prof. dr. R.W. Willemze). Van oktober 2005 tot december 2006 was zij werkzaam als internist-hematoloog in het Medisch Centrum Alkmaar. Vanaf januari 2007 is zij werkzaam als internist-hematoloog in het Medisch Centrum Haaglanden te Den Haag.





# Acknowledgements





The author thanks the Netherlands Committee on Bone Tumours for the assistance and availability of clinicopathological material.









