

# Laparoscopic management of primary abdominal pregnancy: a case report

## *Primer abdominal ektopik gebeliğin laparoskopik tedavisi: olgu sunumu*

Mehmet Metin Altay, Betül Dündar, Ahmet Okyar Erol, Volkan Kurtaran, Orhan Gelişen  
Department of Obstetrics and Gynecology, Etilik Zübeyde Hanım Women's Health Training and Research Hospital, Ankara, Turkey

### Abstract

This is a case report of a primary abdominal pregnancy managed by laparoscopic intervention. A 22 year old, gravida 1, woman was admitted to our emergency room with vaginal bleeding and pain in lower abdomen. She was 4 weeks pregnant according to her last menstrual period. She had undergone right salpingoophorectomy previously. Pelvic examination revealed cervical motion tenderness, bilateral adnexal tenderness and rebound tenderness. Her vital signs were normal. Beta hCG was 15826 IU/ml and hemoglobin was 10.0 g/dl. Transvaginal sonography showed an endometrium of 3 mm thickness and free fluid in the pelvis. Upon admission to the Early Pregnancy Clinic, abdominal pain became worse and hemoglobin decreased to 8.0 g/dL. Therefore, we performed a laparoscopy which showed that the uterus, left tube and ovary were completely normal with absence of the right ovary and tube. Approximately 500 cc blood was aspirated from the pelvis. Between the right sacrouterine ligament and rectum, there was a bleeding area 2 cm in width which was removed with forceps and sent for frozen pathological examination, which revealed 'placental tissue fragments'. Endometrial sampling was reported to be 'secretory endometrium'. A rapid decrease in the beta HCG post operative titer confirmed the resolution of the pregnancy. Primary abdominal pregnancy is extremely rare. The diagnosis is confirmed according to Studdiford's criteria. In the literature, there only a few cases of abdominal pregnancy in which laparoscopic procedure has been used effectively as treatment. However, laparoscopic procedure is usually successful in treatment of abdominal pregnancy if the gestational age is early enough.

(J Turkish-German Gynecol Assoc 2010; 11: 220-2)

**Key words:** Primary abdominal pregnancy, ectopic pregnancy, laparoscopic surgery

**Received:** 23 August, 2010

**Accepted:** 20 October, 2010

### Özet

Kliniğimizde laparoskopik olarak tedavi edilen bir primer abdominal gebelik olgusunu sunduk. 22 yaşında, gravida 1 olan hasta acil servise vajinal kanama ve alt abdominal ağrı yakınmasıyla başvurdu. Son adet tarihine göre yaklaşık 4 haftalık gebe olduğu ve daha önce tubovaryan torsiyon tanısıyla sağ salpingoofektomi yapıldığı öğrenildi. Pelvik muayenede serviks hareketleri ağrıydı, bilateral adneksal hassasiyet ve rebound mevcuttu. Vital bulguları stabildi. Beta-hCG: 15826 IU/mL, Hb: 10.0 g/dL idi. Transvajinal ultrasonografide pelviste yaygın sıvı vardı, endometrium kalınlığı 3 mm, intrauterin ve/veya ektopik gebelik izlenmiyordu. Erken Gebelik Kliniği'ne kabulünde hastanın karn ağrısı arttı, Hb: 8.0 g/dL ye düştü. Hastaya intraabdominal kanama tanısıyla laparoskopik cerrahi uygulandı. Laparoskopide sağ over ve sağ tubanın cerrahi yokluk halinde olduğu izlendi. Uterus, sol over ve sol tuba normal görünümdeydi. Douglas boşluğundan yaklaşık 500 cc kan aspire edildi. Sağ sakrouterin ligament ile rektum arasında 2 cm genişliğinde kanamalı alan izlendi ve çıkarıldı. Doku örneği frozen incelemeye gönderildi, sonuç plasental doku parçaları olarak bildirildi. Aynı anda yapılan endometrial örnekleme sonucu sekretuar endometrium olarak rapor edildi. Post operatif dönemde beta-hCG değerlerinde hızlı bir düşüş izlendi. Primer abdominal gebelik son derece nadirdir. Tanı, Studdiford kriterleri ile konur. Literatürde laparoskopik cerrahinin abdominal gebelik tedavisinde etkin bir şekilde kullanıldığı olgu sayısı oldukça azdır, ancak, gebelik haftasının erken olduğu uygun vaka grubunda başarı oldukça yüksektir.

(J Turkish-German Gynecol Assoc 2010; 11: 220-2)

**Anahtar kelimeler:** Primer abdominal gebelik, ektopik gebelik, laparoskopik cerrahi

**Geliş Tarihi:** 23 Ağustos 2010

**Kabul Tarihi:** 20 Ekim 2010

### Introduction

An ectopic pregnancy is one in which the blastocyst implants anywhere other than the endometrial lining of the uterine cavity. Ectopic pregnancy accounts for 1.3 to 2 percent of reported pregnancies (1). Ectopic pregnancy remains the leading cause of early pregnancy related death. It is the 4th common cause of maternal mortality (2, 3). Serial serum beta human chorionic gonadotropin (beta HCG) titers with subnormally decreasing or increasing pattern and transvaginal sonography

are the most valuable diagnostic tools for confirming a clinical suspicion of ectopic pregnancy.

Clinical presentation varies from mild vaginal bleeding to hemoperitoneum and shock in the case of rupture. Nearly 95 percent of ectopic pregnancies implant in the fallopian tube and the remaining 3.2 percent are ovarian and 1.3 percent abdominal (4). Transvaginal sonography helps us to localize the ectopic pregnancy.

Abdominal pregnancy is an extremely rare and serious form of ectopic pregnancy with an incidence of 1 in 2200 to 10200

of all pregnancies (5). We would like to report a case of primary abdominal pregnancy which is managed successfully by laparoscopic intervention.

### Case Report

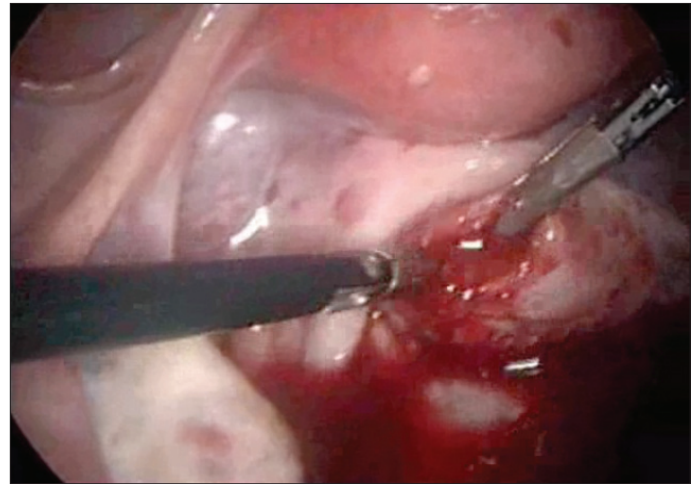
A 22 year old, gravida 1, para 0 woman admitted to our emergency room with mild vaginal bleeding and pain in lower abdomen. It was learned that she had 4 weeks of pregnancy according to the first day of her last menstrual period. She had undergone right salpingooferection previously because of tuba ovarian torsion. Upon admission, pelvic examination revealed cervical motion tenderness, adnexal tenderness bilaterally and rebound tenderness. Beta HCG assay was reported as 15826 IU/ml and hemoglobin concentration was 10.0 g/dl, hematocrit was 29.8 percent, blood pressure and pulse rate were normal. Transvaginal sonography demonstrated an empty uterus with an endometrium of 3 mm thickness and free fluid in the right adnexal region, in the left paraovarian localization and in front of the uterus. The right ovary could not be visualized since it was surgically removed and the left ovary was normal and intrauterine or extrauterine pregnancy could not be demonstrated in sonographic scanning. During her clinical follow up, from admission of the patient at the Emergency Room to evaluation of her at the Early Pregnancy Clinic of our hospital, vital signs remain stable but the patient's complaints got worse and hemoglobin concentration decrease from 10.0 to 8.0 and hematocrit from 29.8 to 25.9 percent.

With those findings, we suspected intraabdominal bleeding due to tubal abortion or abdominal pregnancy. Therefore we did a laparoscopy by using dual puncture technique. Standard surgical techniques were used with a camera and monitor set up. The uterus, the left tuba and the ovary were completely normal, no bleeding was observed from the left fimbria and there weren't any signs of tubal rupture. The right ovary and tuba had been amputated surgically 3 years previously, and there weren't also any signs of bleeding from the stump. From the pouch of Douglas and abdomen approximately 500 cc blood was aspirated. In the area between the right sacrouterin ligament and rectum, there was a bleeding area 2 cm in width containing trophoblastic tissue (Figure 1). The trophoblastic tissue was removed with forceps and sent for frozen pathological examination. Moderate active bleeding occurred from the implantation site during the procedure and bleeding was controlled by electrocautery using bipolar forceps. Pelvis was irrigated with saline at the end of procedure and dilatation and curettage (D/C) was performed. A rapid decrease in the beta HCG titer post operatively confirmed the resolution of the pregnancy. Since the post operative hemoglobin concentration is 6.2 g/dl, 2 units of red blood cell were transfused and the patient was discharged 48 hours post operatively.

The frozen examination of the tissue removed intraoperatively revealed placental tissue fragments confirming the diagnosis of an abdominal pregnancy and histological examination of D/C material revealed secretory endometrium fragments, which was also confirming a primary abdominal pregnancy and excluding a uteroplacental fistula.

### Discussion

Abdominal pregnancy is classified as primary or secondary. The diagnosis of primary abdominal pregnancy was confirmed



**Figure 1. Primary abdominal pregnancy located next to the right sacrouterine ligament in the pouch of Douglas**

according to Studdiford's criteria (6). According to those criteria the diagnosis of primary abdominal pregnancy is based on the following conditions:

1. Presence of normal tubes and ovaries,
2. Absence of a uteroplacental fistula,
3. Attachment exclusively to a peritoneal surface early enough in gestation to eliminate the likelihood of reimplantation after tubal abortion (7).

Usual sites for implantation of an abdominal pregnancy are intraabdominal organs especially the bowel or mesentery or the peritoneum. Transvaginal sonography and MRI are the diagnostic imaging methods which may be used in case of abdominal pregnancy. Transvaginal sonography is the first choice for diagnosis. MRI may be helpful when the transvaginal sonography is inadequate and anatomic relationships are important for determination of surgical approach.

Most of the abdominal pregnancies are secondary, resulting from the reimplantation of a tubal abortion (8). Our case was an example of primary abdominal pregnancy which was managed by laparoscopic intervention. According to Studdiford's criteria tubes and ovaries should be normal. In our case there weren't any evidences of tubal abortion or tubal rupture or uteroplacental fistula, and the gestational age was as early as 4 weeks which also meets the Studdiford's criteria.

Laparoscopic procedure in diagnosis and treatment of ectopic pregnancy is gradually replacing laparotomy (9). Although in most cases of abdominal pregnancies, surgical management is via laparotomy because of risk of massive sometimes uncontrollable intraoperative hemorrhage from the implantation site (10). In the literature, there only a few cases of abdominal pregnancy in which laparoscopic procedure are used effectively in diagnosis and treatment (11-13). Laparoscopic procedure is usually successful in treatment of abdominal pregnancy if the gestational age is early enough.

The vascular supply of implantation site of abdominal pregnancy is also important for determination of surgical approach. Sometimes the implantation site involves a vascular area such as the surface of colon as it was reported by Dover and Powell (11). In that case, the majority of gestational product had been removed laparoscopically from the surface of ascending

colon, leaving a small remnant of organized clot at the site because of the risk of colonic perforation and active bleeding. If the diagnosis of abdominal pregnancy is made early enough, the laparoscopic management will be successful, as in our case we presented here. We recommend laparoscopic approach for similar cases because laparoscopy is less invasive than laparotomy and it has shorter hospital stay.

#### Conflict of interest

No conflict of interest is declared by authors.

#### References

1. Zane SB, Kieke BA Jr, Kendrick JS, Bruce C. Surveillance in a time of changing health care practices: estimating ectopic pregnancy incidence in the United States. *Matern Child Health J* 2002; 6: 227.
2. Centers for Disease Control and Prevention. Ectopic Pregnancy United States, 1990-1992. *MMWR Morb Mortal Wkly Rep* 1995; 44: 46-8.
3. Lewis G and Drife J. Why Mothers Die. Triennial Report 2000-2002. The Sixth Report of the Confidential Enquiries into Maternal Deaths in the United Kingdom. RCOG Press, London, 2004.
4. Bouyer J, Coste J, Fernandez H, Pouly JL, Job-Spira N. Sites of ectopic pregnancy: a 10 year population based study of 1800 cases. *Hum Reprod.* 2002; 17: 3224.
5. Alto WA. Abdominal pregnancy. *Am Fam Physician* 1990; 41: 209-14.
6. Studdiford WE. Primary peritoneal pregnancy. *Am J Obstet Gynecol* 1942; 44: 487-91.
7. Wagner A, Burchardt A. MR imaging in advanced abdominal pregnancy. *Acta Radiol* 1995; 36: 193-5.
8. Hallatt JG, Grove JA. A Abdominal pregnancy: a study of twentyone consecutive cases *Am J Obstet Gynecol* 1985; 152: 444-9.
9. Silva, PD A laparoscopic approach can be applied to most cases of ectopic pregnancy *Obstet Gynecol* 1988; 72: 944-7.
10. Atrash HK, Friede A, Hogue CJ. Abdominal pregnancy in the United States: frequency and maternal mortality *Obstet Gynecol* 1987; 69: 333-7.
11. Dover RW and Powell MC. Management of a primary abdominal pregnancy *Am. J. Obstet. Gynecol* 1995; 172: 1603-4
12. Abossolo T, Sommer JC, Dancoisne P, Orvain E, Tuailon J, Isoard L. First trimester abdominal pregnancy and laparoscopic surgical treatment, 2 case reports of evolving abdominal pregnancy Healed with laparoscopy at 10 and 12 weeks *J Gynecol Obstet Biol Reprod* 1994; 23: 676-80.
13. Ben-Rafael Z, Dekel A, Lerner A, Orvieto R, Halpern M, Powsner E, Voliovitch I. Laparoscopic removal of an abdominal pregnancy adherent to the appendix after ovulation induction with human menopausal gonadotrophin *Hum Reprod* 1995; 10: 1804-5.