

# Pseudo-dissection of ascending aorta in inferior myocardial infarction

Muhammad Nadeem Attar, Hossam Elmahy, Grahame K. Goode

Lancashire Cardiac Centre, Blackpool Victoria Hospital, Lancashire, UK

## Abstract

Acute aortic dissection is a cardiac emergency which can present as inferior myocardial infarction. It has high morbidity and mortality requiring prompt diagnosis and treatment. Rapid advances in non-invasive imaging have facilitated the early diagnosis of this condition and in ruling out this potentially catastrophic illness. We report an interesting case of a 57-year old man who presented with inferior myocardial infarction requiring thrombolysis and temporary pacing wire for complete heart block. An echocardiogram was highly suspicious of aortic dissection. CT scan confirmed that the malposition of the temporary pacing wire through the aorta mimicked aortic dissection.

## Case Report

A 57 year old man was found to be unresponsive and not breathing properly by his wife. She commenced cardiopulmonary resuscitation, called the ambulance and the patient was taken to the emergency department in a nearby district hospital. He was severely

bradycardic, hypotensive and ECG showed ST elevation in inferior leads. He was thrombolysed with tenecteplase. Atropine was administered intravenously with little improvement and complete heart block persisted. A temporary pacing wire was inserted via right internal jugular vein. He was agitated, requiring sedation with midazolam, remained hypotensive and was hence transferred to the tertiary center for further management with dobutamine being administered via the peripheral line. An arterial line in left radial artery was placed for BP monitoring. Risk factors for coronary artery disease included current smoking history. Past medical history was unremarkable and he was not on any regular medications.

On arrival in the coronary care unit, he was fully conscious and orientated. Chest pain had settled and ST elevation had resolved. Pulse rate was a regular 95/min. Systolic blood pressure in the right arm was 100 mm hg and in the left arm 115 mm hg. Heart sounds were normal, chest was clear on auscultation and there was no focal neurological deficit. Echocardiogram performed at the bedside showed hypokinetic inferoposterior walls. Aortic root was enlarged at 4.1 cm, there was suspicion of a dissection flap (Figures 1 and 2; supplementary videos 1, 2 and 3). A diagnosis of possible aortic dissection causing inferior myocardial infarction due to right coronary artery occlusion was considered. Urgent CT was performed. There was no evidence of dissection on the CT aorta. The temporary pacing wire was found in the right common carotid artery and coursed through the innominate artery, the ascending aorta and into the left ventricle (Figure 3).

## Discussion

Aortic dissection is an uncommon catastrophic illness which can present with inferior myocardial infarction and focal pulse deficit. Clinicians fail to initially consider a diagnosis of aortic dissection in up to 35% of cases and many patients are found to have aortic dissection later are initially suspected to have other conditions such as acute coro-

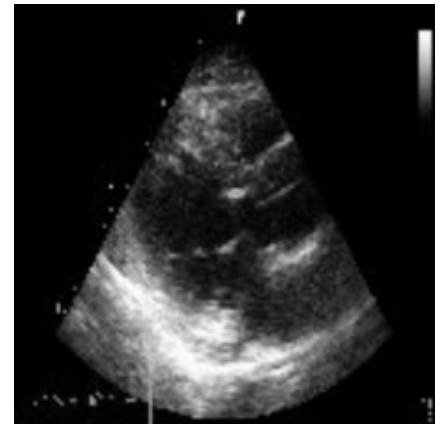


Figure 1. Linear structure in ascending aorta.

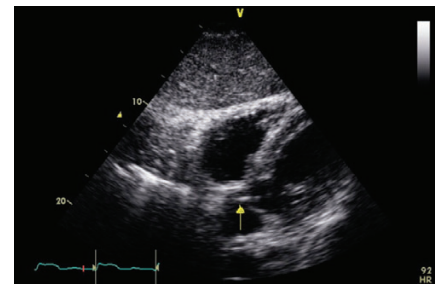


Figure 2. Arrow showing position of linear structure.

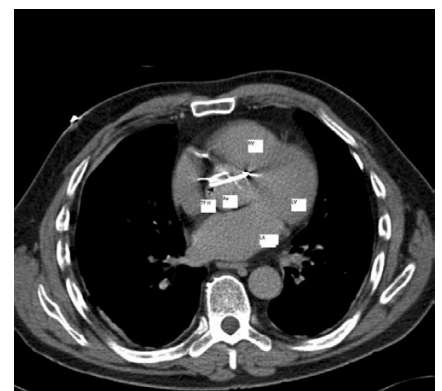

Figure 3. Computed tomography thorax shows TPW crossing ascending Ao into LV. Dark arrow points to temporary pacing wire. LA, left atrium, RV, right ventricle; TPW, temporary pacing wire; Ao, aorta; LV, left ventricle.

Correspondence: Muhammad Nadeem Attar, 28, St Francis Close, Preston PR2 9WJ, Lancs, UK. Tel. +44.7981.925 483. E-mail: nadattar@hotmail.com

Key words: dissection, aorta, temporary pacing wire, artefact.

Conflict of interest: the authors report no conflicts of interest.

Received for publication: 8 May 2011.

Accepted for publication: 23 May 2011

This work is licensed under a Creative Commons Attribution NonCommercial 3.0 License (CC BY-NC 3.0).

©Copyright M.N. Attar et al., 2011  
Licensee PAGEPress, Italy  
Heart International 2011; 6:e1  
doi:10.4081/hi.2011.e1

nary syndrome.<sup>1</sup> Coronary artery occlusion may occur due to extension of the dissection into the coronary arterial wall or secondary to extravasation of blood into pericardial and perivascular tissues.<sup>2</sup> Our patient had inferior MI and differential BP recording in his arms which was suspicious of aortic dissection. Moreover, the echocardiogram findings were suggestive of a dissection flap in the ascending aorta.

Rapid advances in non-invasive imaging technology have facilitated the early diagnosis of aortic dissection and these imaging modalities should be considered in the differential diagnosis of any patient with chest, back, or abdominal pain.<sup>3</sup> An echocardiogram was done at the bedside which was suspicious of dissection in our case. Hence urgent CT scan was

performed which showed that the temporary wire was traversing the ascending aorta into the left ventricle and that there was no evidence of aortic dissection. The temporary wire artefact was mimicking the aortic dissection flap on transthoracic echocardiography. There are several pointers which help distinguish true intimal flaps from artefacts. Flaps are usually thin structures showing mild curvature and artefacts are generally linear varying in thickness and frequently extend beyond the confines of the aorta.<sup>4</sup> On revisiting the echo recording, this artefact can be seen moving into the left ventricle.

## References

1. Kasher JA, El-Bialy A, Balingit P. Aortic dissection: a dreaded disease with many faces. *J Cardiovasc Pharmacol Ther* 2004;9:211-8.
2. Zegers ES, Gehlmann HR, Verheugt FWA. Acute myocardial infarction due to an acute type A aortic dissection involving the left main coronary artery. *Neth Heart J* 2007;15:263-4.
3. Mukherjee D, Eagle KA. Aortic dissection-an update. *Curr Probl Cardiol* 2005;30:287-325.
4. Gallagher S, Dixon AK. Streak artefacts of the thoracic aorta: pseudodissection. *J Comput Assist Tomogr* 1984;8:688-93.