

# Molar pregnancy with false negative urine hCG: the hook effect

Pang Y P, Rajesh H, Tan L K

## ABSTRACT

**Urine pregnancy tests are widely used in emergency departments as the first screening test for patients of reproductive age presenting with gynaecological problems in order to rule out pregnancy. Conditions, such as complete molar pregnancy, which produces large amounts of beta human chorionic gonadotropin ( $\beta$ -hCG), may cause a false negative result due to an oversaturation of the assay system, known as the “hook effect”. We report a case where the exclusion of pregnancy by urine testing led to the initial misdiagnosis of a molar pregnancy as a degenerative fibroid. Physicians need to be reminded of the possibility of false negative results with this commonly used test. Negative or inconclusive results in patients with a high suspicion of pregnancy should be further evaluated by serum quantification of  $\beta$ -hCG and appropriate sample dilution.**

**Keywords: beta-human chorionic gonadotropin, false negative, hook effect, hydatidiform mole, urine pregnancy test**

*Singapore Med J 2010; 51(3):e58-e61*

## INTRODUCTION

The hydatidiform mole, commonly known as a molar pregnancy, is a non-malignant tumour that arises from the trophoblast in early pregnancy, after an embryo has failed to develop. The degenerated trophoblast has a vesicular appearance and has been described to resemble a “bunch of grapes.” There is a geographic variation in the incidence of molar pregnancies, with an increased incidence in Asia compared to the western world. Approximately one in 800 pregnancies in Singapore<sup>(1)</sup> is a molar pregnancy, compared to approximately one in 1,500 in the United States. In other Asian countries such as Taiwan, the incidence is as high as one in 125 pregnancies.

A molar pregnancy often produces large amounts of beta-human chorionic gonadotropin ( $\beta$ -hCG), and the diagnosis should be suspected in patients presenting in early pregnancy with inappropriately high levels

of  $\beta$ -hCG, and with no identifiable foetal poles on ultrasonography examination. However, in some urinary  $\beta$ -hCG immunoassay systems commonly used for pregnancy screening, the large amount of  $\beta$ -hCG secreted in a molar pregnancy may produce a false negative result due to a phenomenon known as the high-dose “hook effect”.

We report a case demonstrating this phenomenon. A 47-year-old Malay woman was initially diagnosed with uterine fibroids after her urine pregnancy test was found to be negative, but was subsequently found to have a hydatidiform mole.

## CASE REPORT

A 47-year-old multiparous Malay woman presented to the Singapore General Hospital emergency department with a two-month history of abdominal bloatedness, mild epigastric discomfort and loss of appetite. She also reported giddiness, orthopnoea, fatigue and difficulty in bladder and bowel movements. She had no remarkable past medical history, except for a previous Caesarean section, and had been well prior to the onset of her symptoms.

The patient had a regular 30-day menstrual pattern, and her last normal menstrual bleeding was one month ago. However, she had been having per vaginal spotting since the last period until the day of presentation. She denied recent sexual activity and was not using any form of contraception. On examination, she was pale and tachycardic, with a heart rate 104 bpm and a blood pressure of 145/75 mmHg. Examination of her heart and lungs was unremarkable, but bilateral lower limb pitting oedema was noted. She had a large, non-tender abdominal mass corresponding to 22 weeks gestation. Speculum examination showed a parous cervix with no obvious lesions. There was moderate per vaginal bleeding at the time of examination.

The patient claimed that she had not noticed the abdominal mass prior to the examination but only felt increased bloatedness of the abdomen, especially after eating. The urine  $\beta$ -hCG pregnancy test was negative, and her haemoglobin was 7.8 g/dl. Ultrasonography (Fig. 1) revealed an enlarged uterus (1,094 ml) with a heterogeneous mass measuring 16.0 cm  $\times$  14.2 cm  $\times$

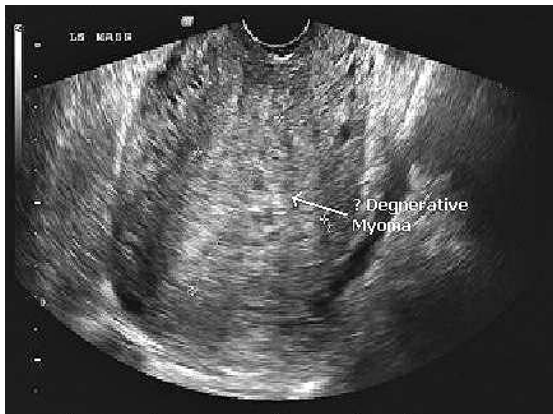
**Department of Obstetrics and Gynaecology, Singapore General Hospital, Outram Road, Singapore 169608**

Pang YP, MBBS, MRCOG, MMed Registrar

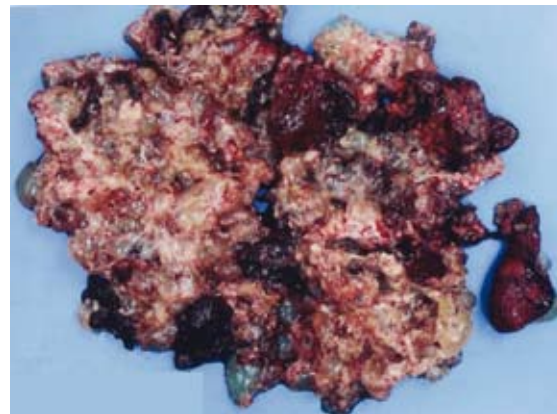
Rajesh H, MBBS, MD, MRCOG Associate Consultant

Tan LK, MBBS, MRCOG, MMed Senior Consultant

**Correspondence to:**  
Dr Cindy Pang  
Tel: (65) 6321 4673  
Fax: (65) 6225 3464  
Email: cindypangyp@yahoo.com



**Fig. 1** Ultrasonography image shows a heterogenous mass (arrow), initially diagnosed as a degenerative myoma after consideration of the patient's symptoms.



**Fig. 2** Photograph shows the vesicular material passed out by the patient, which was histopathologically confirmed as a hydatidiform mole.

9.4 cm in the corpus. Multiple cystic areas were noted within this mass. Colour spectral Doppler demonstrated a vascular lesion that was being supplied by the uterine artery.

In view of the clinical picture of prolonged menses and abdominal mass in a 47-year-old non-pregnant woman, the lesion was diagnosed as a myoma with degenerative changes. Chest radiography revealed a small pleural effusion with a mildly enlarged heart. Doppler of the lower limbs showed no deep venous thrombosis. In view of the patient's abnormal bleeding pattern, endometrial sampling using a pipelle device was performed.

The patient was then admitted for blood transfusions and started on haematinics. She continued to have moderate per vaginal bleeding despite intramuscular progesterone and oral norethisterone. The initial plan was to perform an elective total hysterectomy, based on the diagnosis of a degenerative fibroid. Two days after admission, the patient developed a fever with severe abdominal pain in the early hours of the morning. Her haemoglobin level dropped from 11.4 g/dl to 6.8 g/dl, and she was resuscitated with fluids and blood. One hour later, she passed out necrotic material and grapelike vesicles per vaginum (Fig. 2), and a subsequent abdominal examination found that the uterine volume had decreased to 14 weeks.

A urine pregnancy test was repeated, which was weakly positive. The histological result from the pipelle biopsy was available later in the day, and it showed degenerate products of conception with no foetal tissues. An urgent serum  $\beta$ -hCG test was performed, and a reading of  $> 1,000,000$  U/l was reported. A repeat ultrasonography revealed an irregularly echogenic, relatively isoechoic mass measuring 6.3 cm  $\times$  4.9 cm  $\times$  6.3 cm, which was confluent with normal-looking

endometrium. Power Doppler detected a rich vascularity of low-impedance flow. A provisional diagnosis of molar pregnancy was made.

Thyroid function tests showed a free thyroxine level of 50 pmol/L and a thyroid-stimulating hormone (TSH) of  $< 0.006$  mu/L. The patient was administered propylthiouracil 200 mg, propranolol 40 mg and intravenous hydrocortisone 100 mg preoperatively, before an emergency evacuation of the uterus was performed. Pathological examination of the necrotic material confirmed a complete hydatidiform mole. Further anti-thyroid medications were deferred, as the thyrotoxicosis was attributed to the molar pregnancy.

No further complications were observed, and the patient was discharged two days post operation. As she was considered to be at high risk of persistent molar disease, a weekly follow-up with serum  $\beta$ -hCG level measurement was planned. Her repeat  $\beta$ -hCG ten days postoperatively was 49,348 U/l. The patient subsequently defaulted follow-up despite reminders of the need for  $\beta$ -hCG measurements. The patient attended the emergency department six months later with complaints of heavy per vaginal bleeding. She claimed to have had regular periods in the interim period, and her  $\beta$ -hCG level on admission was 2,870 U/l. Ultrasonography revealed a rich vascular mass measuring 3.4 cm  $\times$  2.9 cm  $\times$  3.7 cm with isoechoic as well as echogenic areas.

A survey for extrauterine spread was done with a subsequent chest radiograph and computerised tomography of the abdomen and pelvis, which were found to be negative. Although an evacuation of the uterus was planned, a hysterectomy was eventually performed as the evacuation was complicated by excessive bleeding. The histological examination revealed a complete hydatidiform mole in the curettage, but the hysterectomy specimen did not reveal myometrial

invasion. The postoperative  $\beta$ -hCG level was 55 U/l. The patient subsequently discontinued follow-up again.

## DISCUSSION

Gestational trophoblastic disease (GTT) demonstrates marked geographic and ethnic differences, with the highest incidence in South-East Asia. The rates range from one to two in 1,000 pregnancies in Japan and China.<sup>(2)</sup> This disorder is more common in young women and women nearing the end of their reproductive years. The classical presentation is vaginal bleeding, with a large-for-date uterus. 7% of women can present with hyperthyroidism. With the advent of high resolution ultrasonography, most of these moles are now diagnosed in the first trimester, before the onset of classic signs and symptoms.<sup>(3)</sup>

A woman of reproductive age who visits our emergency department routinely has a urine qualitative assay for  $\beta$ -hCG screening test performed to exclude pregnancy. As this patient denied amenorrhoea and any recent sexual activity, and as the initial urine pregnancy test was negative, the suspicion for a pregnancy-related complication was very low.

Current urine and serum pregnancy tests use antibodies directed against  $\beta$ -hCG for immunologic identification. Two antibodies directed against different parts of the beta chain are used, and the resultant "sandwich" they form around the antigen is detected and interpreted as "positive". Most test kits have one antibody to site  $\beta$ 1 and another to the C-terminus of the  $\beta$ -subunit ( $\beta$ -CTP), or to the  $\alpha$ -subunit. However, falsely low or negative results can occur when an extremely high level of  $\beta$ -subunit core fragment, a breakdown product of  $\beta$ -hCG, overwhelms the assay system and blocks the formation of "sandwiches" between the two sites.<sup>(4,5)</sup> This is known as the "hook effect" or "prozone phenomenon", and can be observed in immunometric sandwich assays.

In our patient, a serum  $\beta$ -hCG assay assisted in making the diagnosis. However, it is important to note that hook effects occurring in both qualitative urine and quantitative serum  $\beta$ -hCG assays have been reported.<sup>(6)</sup> Therefore, it is possible that if the actual serum  $\beta$ -hCG is extremely high, the reported serum  $\beta$ -hCG may be spuriously underestimated due to the hook effect. This hook effect has also been documented with immunoassays with ferritin, prostate-specific antigen, prolactin, rapid plasma reagin for syphilis,<sup>(7)</sup> thyrotropin and CA-125. It can be overcome by dilution of the test sample if the suspicion is high.<sup>(8)</sup>

The hook effect may confound pregnancy test

results for patients who undergo the test several weeks after missing their menses, at a time when the  $\beta$ -hCG concentrations are very high. A paper surveying urinary pregnancy test devices tested the reliability of the kits at  $\beta$ -hCG concentrations of up to 500,000 IU/l, in which eight devices gave a weak positive at this concentration, even though a strong positive had been indicated at 100,000 IU/L.<sup>(9)</sup> The signal was even weaker or absent at higher concentrations. To overcome the hook effect, dilution of the serum or urine sample can be performed.<sup>(10)</sup>

The authors wish to highlight that clinicians should understand the possibility of inaccurate results, and should rely on clinical acumen in such tricky situations. On review of this case, after the histology was known, it was acknowledged by the ultrasonist that the lesion in the uterus raised suspicion for a molar pregnancy due to the cystic areas. However, as the patient was informed that the urine pregnancy test was negative, the possible differential diagnosis was not discussed with the referring gynaecologist. The symptoms of abnormal per vaginal bleeding, a size 22-week uterus and the ultrasonographic findings of cystic areas in a lesion within the uterus were, in retrospect, typical of a molar pregnancy. However, the managing team was confounded by the negative urine pregnancy test, and therefore, worked with the diagnosis of a degenerative large fibroid.

Another learning point is the need to advocate close follow-up for post-molar GTT, especially in older women. In women over 35 years of age, the risk of post-molar GTT after suction evacuation appears to have increased and has been reported to be as high as 56% in women over 50 years of age.<sup>(11)</sup> In approximately 15% of cases of complete molar pregnancies, the abnormal trophoblast cells continue to proliferate and invade into the uterine wall. They can then metastasise to other organs, particularly the lungs. This is more likely with older patients.<sup>(12)</sup> Hence, for older women diagnosed with a molar pregnancy and who have completed their families, consideration should be given for a hysterectomy to decrease the risk of post-molar GTT and possible invasive disease.<sup>(13)</sup>

Our patient had withheld important information in her history and repeatedly defaulted follow-up despite reminders. In retrospect, with this patient demonstrating a lack of knowledge and regard for her own medical condition, hysterectomy may have been a better treatment option during the initial visit, and the second episode may have been avoided.

For the second evacuation of the uterus, consent was rightly obtained for hysterectomy, as complete moles are highly vascular tumours and can bleed heavily.

If the patient had consented to a hysterectomy during the second operation, it would have been a reasonable form of treatment. However, our patient chose to have an evacuation, with a conversion to hysterectomy only if there was excessive bleeding. Although hysterectomy eliminates the risk of local invasion, it does not prevent metastases, and follow-up with serial  $\beta$ -hCG testing is still mandatory.

In conclusion, false-negative pregnancy tests have also been reported in ectopic pregnancy, multiple gestations and cancer. Negative or inconclusive results in patients with high suspicion of pregnancy should be further evaluated by serum quantification of  $\beta$ -hCG and appropriate sample dilution. In an older patient with a molar pregnancy, increased vigilance for persistence GTT is required, and hysterectomy may be considered for those who have completed their families, or are noncompliant with follow-up. Although modern assay methods have much improved reliability, physicians should still be aware of the potential for false-negative urinary and serum  $\beta$ -hCG results due to the high-dose hook effect, especially in the setting of hydatidiform moles and delayed pregnancy tests.

## REFERENCES

1. Chong CY, Koh CF. Hydatidiform mole in Kandang Kerbau Hospital – a 5-year review. *Singapore Med J* 1999; 40:265-70.
2. Bracken MB. Incidence and aetiology of hydatidiform mole: an epidemiological review. *Br J Obstet Gynaecol* 1987; 94:1123-35.
3. Steigrad SJ. Epidemiology of gestational trophoblastic diseases. *Best Pract Res Clin Obstet Gynaecol* 2003; 17:837-47.
4. Er TK, Tsai LY, Ginés Ruiz MA, et al. Quantitative human chorionic gonadotropin measurement in urine using the Access immunoassay. *Am J Emerg Med* 2008; 26:103-4.
5. Yunus D, Muppala H, Hamer F, Clarke F. Three consecutive false negative pregnancy tests in a twin pregnancy: a case report. *Int J Gynecol Obstet* [serial online] 2007; 6. Available at: [www.ispub.com/journal/the\\_internet\\_journal\\_of\\_gynecology\\_and\\_obstetrics/volume\\_6\\_number\\_2\\_6/article/three\\_consecutive\\_false\\_negative\\_pregnancy\\_tests\\_in\\_a\\_twin\\_pregnancy\\_a\\_case\\_report.html](http://www.ispub.com/journal/the_internet_journal_of_gynecology_and_obstetrics/volume_6_number_2_6/article/three_consecutive_false_negative_pregnancy_tests_in_a_twin_pregnancy_a_case_report.html). Accessed February 10, 2010.
6. Er TK, Jong YJ, Tsai EM, et al. False-negative pregnancy test in hydatidiform mole. *Clin Chem* 2006; 52:1616-8.
7. el-Zaatari MM, Martens MG, Anderson GD. Incidence of the prozone phenomenon in syphilis serology. *Obstet Gynecol* 1994; 84:609-12.
8. Wolf BA, Garrett NC, Nahm MH. The “hook effect”: high concentrations of prostate-specific antigen giving artifactually low values on one-step immunoassay. *N Engl J Med* 1989; 320:1755-6.
9. Wheeler MJ. Evaluation of home pregnancy test kits for reliability. *Nursing Times* [serial online] 2007; 103: 30-1. Available at: [www.nursingtimes.net/nursing-practice-clinical-research/evaluation-of-home-pregnancy-test-kits-for-reliability/199782.article](http://www.nursingtimes.net/nursing-practice-clinical-research/evaluation-of-home-pregnancy-test-kits-for-reliability/199782.article). Accessed February 10, 2010.
10. Tabas JA, Strehlow M, Isaacs E. A false negative pregnancy test in a patient with a hydatidiform molar pregnancy. *N Engl J Med* 2003; 349:2172-3.
11. Tsukamoto N, Iwasaka T, Kashimura Y, et al. Gestational trophoblastic disease in women aged 50 or more. *Gynecol Oncol* 1985; 20:53-61.
12. Bandy LC, Clarke-Pearson DL, Hammond CB. Malignant potential of gestational trophoblastic disease at the extreme ages of reproductive life. *Obstet Gynecol* 1984; 64:395-9.
13. Bahar AM, el-Ashnehi MS, Senthilselvan A. Hydatidiform mole in the elderly: hysterectomy or evacuation? *Int J Gynaecol Obstet* 1989; 29:233-8.