

Isolated high lateral acute myocardial infarction with superior injury current axis

Lee L C, Tan H C, Poh K K

ABSTRACT

We report a 70-year-old man with high lateral ST elevation myocardial infarction secondary to occlusion of left circumflex artery. Electrocardiography (ECG) showed ST depression in inferior leads and isolated ST elevation in leads aVR and aVL, demonstrating a superior axis of the injury current vector. Different presentations of ECG pattern from left circumflex artery occlusion were discussed. This case highlights the importance of recognising unusual ECG pattern in accurate diagnosis of acute myocardial infarction.

Keywords: acute myocardial infarction, isolated high lateral acute myocardial infarct, left circumflex artery occlusion, myocardial infarction, ST depression, ST elevation

Singapore Med J 2008;49(10):e266-e268

INTRODUCTION

Prompt and accurate diagnosis of ST elevation myocardial infarction in the management of patients presenting with acute chest pain facilitates early invasive approach. We report an unusual case of high lateral ST elevation myocardial infarction and discuss the presentation, especially with respect to the electrocardiography (ECG) diagnosis.

CASE REPORT

A 70-year-old man presented to the emergency department with severe chest pain four hours earlier. He had a background history of diabetes mellitus and hyperlipidaemia. Clinical examination was unremarkable and he was haemodynamically stable. His presenting ECG showed mild ST elevation (< 1 mm) in leads aVR and aVL accompanied by ST depression in leads II, III and aVF (Fig. 1a). He was admitted to the coronary care unit with the working diagnosis of acute coronary syndrome. He continued to experience intermittent angina despite medical treatment. Two hours after admission, he became hypotensive and repeated ECG showed junctional rhythm with retrograde P waves. There was further ST

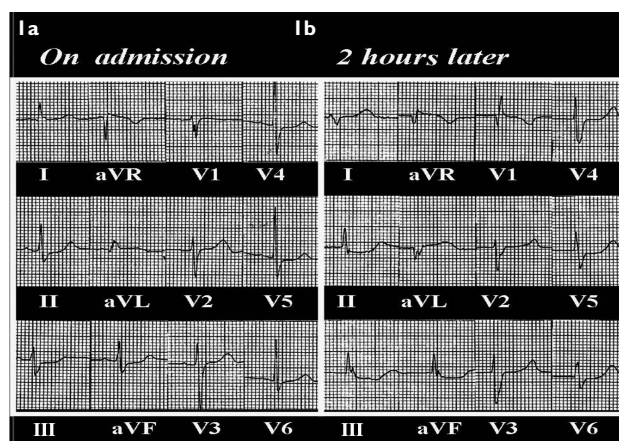


Fig. 1 (a) Initial ECG on presentation shows predominant ST depression in leads II, III and aVF with mild ST elevation (< 1 mm) of leads aVR and aVL. (b) Repeat ECG shows junctional bradycardia with worsening of the ST elevation and depression. There were also pathological Q waves in leads aVR and aVL.

elevation in leads aVR and aVL as well as worsening ST depression in II, III and aVF. In addition, pathological Q waves were developing in leads aVR and aVL (Fig.1b). He was diagnosed to be having high lateral ST elevation acute myocardial infarction (AMI) complicated by haemodynamically-significant junctional bradycardia.

Urgent coronary angiogram showed triple vessel disease with significant stenosis of the proximal right coronary artery (75%), right posterior descending artery (90%), first diagonal branch (75%), mid left anterior descending artery (90%) and complete occlusion of the proximal left circumflex artery (LCx), which was the culprit lesion (Fig. 2a). Primary percutaneous coronary intervention was performed. The circumflex lesion was balloon angioplastied and stented (Fig. 2b). This was followed by resolution of angina, junctional rhythm and improvement in haemodynamics. Peak creatinine kinase, CK-MB, troponin were 2,368 U/L, 15 mcg/L and 7.66 mcg/L, respectively. He had an uneventful recovery. Post-revascularisation ECG (Fig. 3) showed resolution of the ST changes in the respective leads. Exercise nuclear myocardial perfusion scan performed four months later confirmed the presence of a basal lateral fixed defect with reduced uptake of Tc 99m-tetrofosmin both at rest and during exercise stress (Fig. 4).

The Cardiac Department, National University Hospital, 5 Lower Kent Ridge Road, Level 3 Main Building, Singapore 119074

Lee LC, MBBS, MRCP Registrar

Tan HC, FRCP, FAMS, FACC Senior Consultant and Chief

Poh KK, FCCP, FAMS, FASE Consultant

Correspondence to: Dr Lee Li Ching
Tel: (65) 6772 5211
Fax: (65) 6872 2998
Email: leeliching@yahoo.com

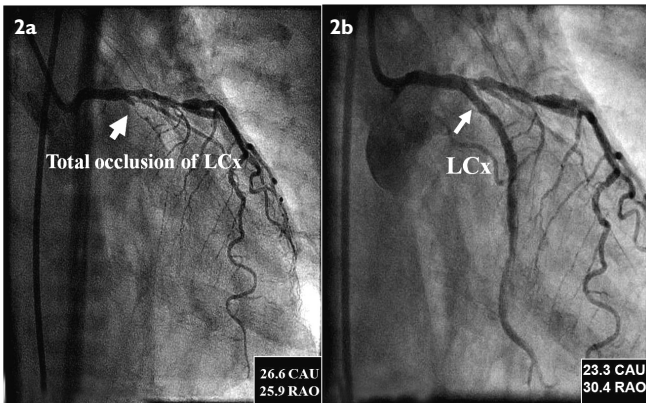


Fig. 2 (a) Coronary angiogram (RAO caudal view) shows that the left circumflex artery (LCx) was totally occluded proximally. (b) Postpercutaneous coronary intervention (PCI) coronary angiogram shows restoration of flow in the left circumflex artery.

DISCUSSION

Prompt and accurate diagnosis of AMI is essential as reperfusion has been shown to reduce infarct size and has prognostic significance.⁽¹⁾ ECG changes are important; when ECG criteria for ST elevation myocardial infarction (STEMI) are met, revascularisation is recommended. However, Huey BL et al demonstrated that the initial ECG failed to show acute changes (i.e. ST-segment elevation) in as many as 25%–50% of patients who then developed AMI.⁽²⁾ This is especially true for patients with acute occlusion of the left circumflex coronary artery. They may present with either: (i) ST segment elevation in the inferior leads II, III and aVF and the lateral leads I, aVL, V5 and V6; (ii) ST segment depression in the precordial leads V1 to V4; (iii) ST segment elevation in the high lateral leads I and aVL; or (iv) a normal ECG.⁽²⁻⁶⁾ Concomitant posterior ST elevation in leads V7 to V9 may aid in the identification of posterior STEMI from circumflex artery occlusion.⁽⁶⁾ However, among all the STEMI secondary to circumflex artery occlusion, isolated high lateral STEMI would be the most difficult to diagnose.

In our patient's first ECG, ST segment elevation was not prominent. Instead, ST depression predominated. It is not uncommon that ST depression and elevation coexist on a 12-lead ECG. It is therefore important to determine, whether ST elevation was primary with reciprocal ST depression or vice versa, and thus the predominant pathophysiology. In our case, ST elevation in aVR and aVL become more prominent with the evolution of pathological Q waves and development of an abnormally tall R wave in V1. This favoured proximal circumflex artery as the infarct related artery and underlying multivessel disease with

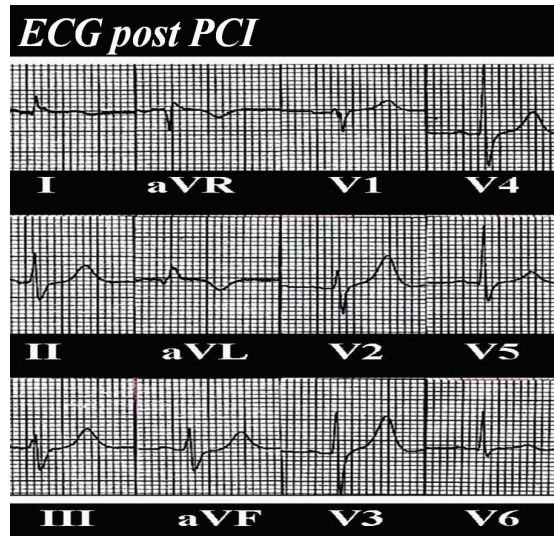


Fig. 3 ECG shows resolution of ST segment changes postrevascularisation.

a specificity of 96% and sensitivity of 21%.^(2,7)

The aVL, aVF and aVR are augmented unipolar limb leads. These, together with bipolar limb leads (I, II and III), form the Cabrera display, which establishes more accurately spatial contiguity in the frontal plane. Fig. 5 shows the concept of the Einthoven triangle and the hexaxial reference system. The direction of the ST vector is determined by the current of injury and the relative position of the electrodes measuring the vector. For instance, if lead III has a 2-mm ST elevation and lead II a 1-mm ST elevation, then the ST segment axis will be between aVF and III (+90° to +120°).

Lead aVR faces the heart from the right shoulder and is oriented to look at the outflow tract of the right ventricle and basal septum. In general, the current of injury resulting from occlusion of the LCx has a mean vector that forms an obtuse angle with the axis of aVR, ie towards leads I and aVL. Therefore, we would expect ST-segment depression in aVR with LCx occlusion. In our case, the axis was superior as both aVR and aVL were elevated. Subsequent pathological Q waves developed in these leads consistent with these as primary changes. ST depressions in II, III, and aVF were thus secondary. The superior ST axis is likely due to the involvement of the basal lateral area in our patient. Gorgels et al had showed that in some cases of circumflex occlusion, with ischaemia in the posterobasal area, the current of injury is directed towards the right shoulder, hence aVR may be elevated.^(8,9) In addition, Yamaji et al have also demonstrated that lead aVR is primarily elevated in the setting of left main artery occlusion suggesting of basal septum ischaemia.⁽⁹⁾

Therefore, while the location of myocardial infarction depends on the “indicative” ECG infarct

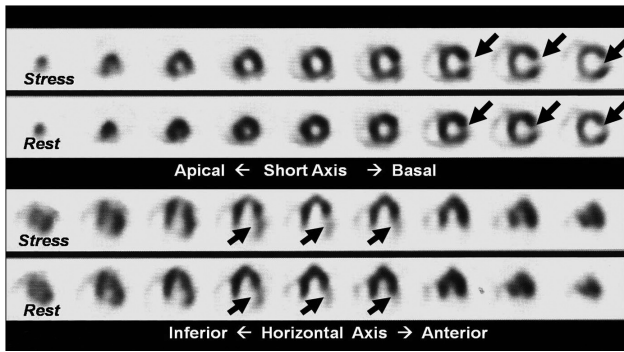


Fig. 4 Exercise myocardial nuclear perfusion scan shows basal lateral fixed defect (arrows).

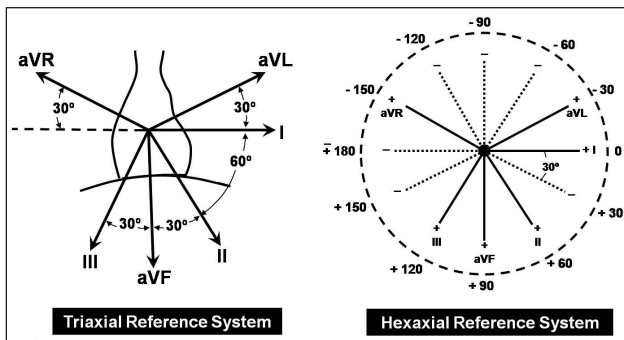


Fig. 5 Diagram shows triaxial and hexaxial reference system. (Source: BL Chia. Clinical Electrocardiography. 3rd ed. Singapore: World Scientific, 1998: 4)

pattern in certain leads, the direction of ST segment elevation helps predict the thrombosed coronary artery. We described, for the first time, isolated ST elevation in leads aVR and aVL associated with circumflex artery occlusion demonstrating superior axis of the injury current vector. This may be due to a greater basal involvement of the high lateral infarction. Indeed myocardial perfusion scan demonstrated the presence of a basal lateral fixed defect on stress and rest images. The defect size was quantitated to be 10% of the left ventricular area on the bull's eye nuclear map. Though there was only minor ST elevation on the ECG, there was a significant raise in cardiac enzymes (CK-MB and troponin levels) associated with total circumflex artery occlusion. The nuclear perfusion defect was also moderate in size.

ECG reflects the physiology of the myocardium during acute ischaemia and infarction. The evolving

changes of ST waveforms and Q waves allow clinician to diagnose the event, localise the involved area, infarct related artery, and estimate the amount of myocardium at risk, thereby guiding subsequent management as well as providing prognostic value. This is a novel description of superior axis of injury currently manifesting as ST elevation in only leads aVR and aVL due to complete occlusion of the LCx. It is important to recognise this unique pattern since clinical management of myocardial infarction is aided by ECG pattern.

REFERENCES

1. Indications for fibrinolytic therapy in suspected acute myocardial infarction: collaborative overview of early mortality and major morbidity results from all randomised trials of more than 1000 patients. Fibrinolytic Therapy Trialists' (FTT) Collaborative Group. *Lancet* 1994; 343:311-22.
2. Huey BL, Beller GA, Kaiser DL, Gibson RS. A comprehensive analysis of myocardial infarction due to left circumflex artery occlusion: comparison with infarction due to right coronary artery and left anterior descending artery occlusion. *J Am Coll Cardiol* 1988; 12:1156-66.
3. Berry C, Zalewski A, Kovach R, Savage M, Goldberg S. Surface electrocardiogram in the detection of transmural myocardial ischemia during coronary artery occlusion. *Am J Cardiol* 1989; 63:21-6.
4. Shah A, Wagner GS, Green CL, et al. Electrocardiographic differentiation of the ST-segment depression of acute myocardial injury due to the left circumflex artery occlusion from that of myocardial ischemia of nonocclusive etiologies. *Am J Cardiol* 1997; 80:512-3.
5. Chia BL, Yip JW, Tan HC, Lim YT. Usefulness of ST elevation II/III ratio and ST deviation in lead I for identifying the culprit artery in inferior wall acute myocardial infarction. *Am J Cardiol* 2000; 86:341-3.
6. Poh KK, Chia BL, Tan HC, Yeo TC, Lim YT. Absence of ST elevation in ECG leads V7, V8, and V9 in ischaemia of non-occlusive aetiologies. *Int J Cardiol* 2004; 97:389-92.
7. Shen WF, Tribouiloy C, Lesbre JP. Relationship between electrocardiographic patterns and angiographic features in isolated left circumflex coronary artery disease. *Clin Cardiol* 1991; 14:720-4.
8. Gorgels A, Engelen DJM, Wellens HJJ. Lead aVR, a mostly ignored but very valuable lead in clinical electrocardiography. *J Am Coll Cardiol* 2001; 38:1564-9.
9. Yamaji H, Iwasaki K, Kusachi S, et al. Prediction of acute left main coronary artery obstruction by 12-lead electrocardiography. ST segment elevation in lead aVR with less ST segment elevation in lead V1. *J Am Coll Cardiol* 2001; 38:1348-54.