



Menkes Disease: X-Chromosome linked inborn disorder of copper metabolism

Waleed Ali¹, M. Imran Qadir^{1*}, Khalid Hussain Janbaz²
¹College of Pharmacy, Government College University, Faisalabad, Pakistan
²Faculty of Pharmacy, Bahauddin Zakariya University, Multan, Pakistan
*mrimranqadir@hotmail.com

Summary

Menkes disease is an inborn disorder of copper metabolism which consequently results in serum copper deficiency. It was discovered by Johns Han Menkes in 1962 and therefore named as Menkes disease. Mutation in ATP-7A gene on chromosome Xq12-q13 is the molecular cause of Menkes disease. It is characterized by small, scanty, thin scarce hair, growth failure and damage to nervous system. Seizures, stoppage to flourish, abnormal body temperature and kinky colourless or steel coloured hairs are the main characteristics of this disease. Serum copper and ceruloplasmin levels are used for the diagnosis of Menkes Disease. Not a definite management for Menkes disease is available. Most persons with this condition die within the first few years of life. However, parenteral copper may be used to control the copper level for the time being.

Keywords: Menkes disease, Copper, Mutations in ATP-7A gene

Introduction

Menkes disease is an inborn disorder of copper metabolism which consequently results in serum copper deficiency^(1,2). It was discovered by Johns Han Menkes in 1962 and therefore named as Menkes disease. It is an X-chromosome linked⁽³⁾ recessive disease; and due to this reason, it is more common in men than in women⁽⁴⁾. It is also known as Menkes syndrome, kinky hair disease⁽⁵⁾, Menkes kinky hair syndrome⁽⁶⁾. Menkes disease represents only one end of the complete full spectrum of mutations of ATP-7A gene. The clinical spectrum of ATP7A-related copper transport disorders ranges from classic Menkes disease at the severe end to occipital horn syndrome (OHS) to distal motor neuropathy (DMN). Menkes Disease is listed as a "rare disease" by the Office of Rare Diseases (ORD) of the National Institutes of Health (NIH). This means that Menkes Disease, or a subtype of Menkes Disease, affects less than 200,000 people in the US population. Estimated 1 per 100,000 people suffer Menkes syndrome.

ETIOLOGY

Mutation in ATP-7A gene on chromosome Xq12-q13 is the molecular cause of Menkes disease^(7,8). Mutation in this gene causes poor copper transport to the cells⁽⁹⁾. As a result, the concentration of copper increases in tissues like kidney and small intestine; while the level of copper in brain and in some other tissues remains the normal. The activity of several enzymes which are essential for the proper structure and function of bone, skin, hair, blood vessels, and nervous system and several systems, can also be decreased due to low supply of copper^(10,11).

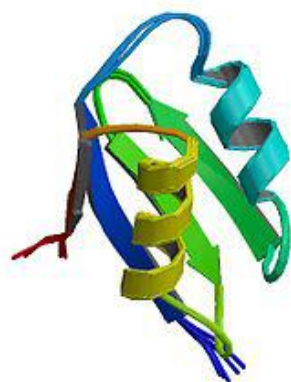


Figure 1: ATP-7A Protein, its poor function causes Menkes disease

CLINICAL SYMPTOMS

It is characterized by small, scanty, thin scarce hair, growth failure and damage to nervous system⁽¹²⁾. Seizures, stoppage to flourish, abnormal body temperature and kinky colourless or steel coloured hairs are the main characteristics of this disease. Grey matter of the brain can also be extensively degraded. It can also result in twisting of arteries of brain with split inner walls. Twisted arteries causes blockage or bursting of arteries, weakened bones may result in fracture. This disease usually begins when the baby is in the womb of his mother and results in impulsive birth of babies. The affected babies are in good physical shape and show standard progress for about one to two months. After that the signs like hypotonia, seizures, feeding difficulties and other symptoms of the disease appear⁽¹³⁾.

PATHOPHYSIOLOGY

The molecular genetics and pathophysiology of Menkes disease and an animal model for this disease are reviewed. The Menkes gene, located on chromosome X13.3, encodes a copper-transporting ATPase, as shown by the sequencing of a cDNA of 4500 bp. Mutations in the Menkes gene in patients with Menkes disease show great variety, including missense, nonsense, deletion and insertion mutations. Mutations in the Menkes gene have also been identified in patients with mild Menkes disease or occipital horn syndrome, showing that these diseases are allelic variants of Menkes disease. Mutations in the mottled gene, the murine homolog of the Menkes gene, have been demonstrated in mottled mutant mice that display biochemical and phenotypic abnormalities similar to those observed in patients with Menkes disease. In affected cells, copper significantly accumulates as metallothionein-bound copper in the cytosol and copper transport to the organelles, as well as copper efflux, is disturbed. As a result, cuproenzymes cannot receive the copper necessary for their normal function. Thus, the objective in treatment of Menkes disease and occipital horn syndrome is to

deliver copper to the intracellular compartments where cuproenzymes are synthesized.

DIAGNOSIS

There is often a history of Menkes syndrome in a male relative.

Signs include:

- Abnormal appearance of the hair under the microscope
- Abnormally low body temperature
- Bleeding in the brain
- Slow growth in the womb

In males, all of the hairs will be abnormal. In females who carry this trait, only half of the hairs may be abnormal.

Tests include:

- Serum ceruloplasmin
- Serum copper level
- Skin cell (fibroblast) culture
- X-ray of the skeleton or x-ray of the skull

Genetic testing may show a change (mutation) in the ATP7A gene⁽¹⁴⁻¹⁶⁾

Copper and ceruloplasmin levels

Serum copper and ceruloplasmin levels are used for the diagnosis of Menkes Disease. If serum copper level is less than 70 mg/dL (reference 80-160) and serum ceruloplasmin level is less than 20 mg/dL (reference 20-60), it may be an indicator of the disease.

Plasma catecholamines

Decreased norepinephrine level is a marker for Menkes Disease⁽¹⁷⁾.

Hydroxyphenylalanine and dihydroxyphenylglycol (DOPA/DHPG) ratio is increased in Menkes Disease due to decreased activity of dopamine beta-hydroxylase. Normal value is 1.7-3.3.

Urine homovanillic acid/vanillylmandelic acid

(HVA/VMA) ratios above 4 may be noted.

Imaging findings

Observed features include:

- metaphyseal widening of the femur and ribs
- tibial and femoral spurs
- wormian bones

Other findings

Other findings may include the following:

- Increased intestinal and kidney copper
- Decreased hepatic copper
- Hypoglycemia

Misdiagnosis

When checking for misdiagnosis of Menkes disease or confirming a diagnosis of Menkes disease, it is useful to consider what other medical conditions might be possible or other alternative conditions related to diagnosis. These alternate conditions may be:

- Leigh disease
- Phenylketonuria (PKU)
- Biotinidase deficiency
- Organic acidurias
- Aminoacidurias
- Mitochondrial myopathies

MANAGEMENT

Modern technologies are trying to control different diseases⁽¹⁸⁾. However, not a definite management for Menkes disease is available. Most persons with this condition die within the first few years of life.

Amount of copper and ceruloplasmin in the serum are not affected by oral intake of copper as they are poorly absorbed. However, parenteral copper may cause the formation WND gene product and apoceruloplasmin. These two proteins lead to

increased value of serum copper and ceruloplasmin.

A physician who is aware of the worth of copper in the shape histidine⁽¹⁹⁾ and chloride salts may treat the patients with these drugs. About 350 to 500 micro grams of copper in the shape of histidine and chloride salts are injected into the blood which results in elevation of copper in the serum and also in the cerebrospinal fluid. The result of this remedy is enhancement in the signs of this sickness. After this treatment bones begin to develop again, however the copper levels are not maintained normal in the body. Symptoms of Menkes disease related to the nervous system can also be overcome by treating the child in the intrauterine life with copper salts. If the signs related to disturbance in nervous system once appears than they cannot be treated⁽²⁰⁻²¹⁾.

Future Considerations

Although the findings are good for some patients treated by copper therapy⁽²²⁾ but most of the patients will require additional approaches for the treatment of Menkes disease. Gene therapy may be one the possibilities for its treatment.

References

- Kaler SG, Liew CJ, Donsante A, Hicks JD, Sato S, Greenfield JC. Molecular correlates of epilepsy in early diagnosed and treated Menkes disease. *J Inherit Metab Dis.* 2010; 33:583-9.
- Kasama T, Tanaka H. Effects of copper administration on fetal and neonatal mice. *J Nutr Sci Vitaminol* 1988;595-605.
- Bahi-Buisson N, Kaminska A, Nabbout R, Barnerias C, Desguerre I, De Lonlay P, Mayer M, Plouin P, Dulac O, Chiron C. Epilepsy in Menkes disease: analysis of clinical stages. *Epilepsia.* 2006; 47(2):380-6.
- Danks DM. Of mice and men, metals and mutations. *J Med Genet.* 1986 ;23:99-106.
- Kaler SG. In: Pagon RA, Bird TC, Dolan CR, Stephens K, editors. *ATP7A-Related Copper Transport Disorders.* GeneReviews. Seattle (WA): University of Washington, Seattle; 1993-2003 , 9.
- James, William; Berger, Timothy; Elston, Dirk (2005). *Andrews' Diseases of the Skin: Clinical Dermatology.* (10th ed.). Saunders. p. 765.
- Liu Y, Pilankatta R, Hatori Y, Lewis D, Inesi G. Comparative features of copper ATPases ATP7A and ATP7B heterologously expressed in COS-1 cells. *Biochemistry.* 2010 (Ahead of Print).
- Kaler SG. ATP7A-related copper transport diseases-emerging concepts and future trends. *Nat Rev Neurol.* 2011 ;7(1):15-29.
- Southon A, Palstra N, Veldhuis N, Gaeth A, Robin C, Burke R, Camakaris J. Conservation of copper-transporting P(1B)-type ATPase function. *Biometals.* 2007; 27(3):278-91.
- Kodama H, Murata Y. Molecular genetics and pathophysiology of Menkes disease. *Pediatr Int.* 1999 ;41(4):430-5.
- Kodama H, Fujisawa C, Bhadhprasit W. Pathology, clinical features and treatments of congenital copper metabolic disorders - Focus on neurologic aspects. *Brain Dev.* 2010 (ahead of print).
- Kodama H, Murata Y, Kobayashi M. Clinical manifestations and treatment of Menkes disease and its variants. *Pediatr Int.* 1999; 41(4):423-9.
- Tümer Z, Møller LB. Menkes disease. *Eur J Hum Genet.* 2010 ;18(5):511-8
- Kaler SG. Metabolic and molecular bases of Menkes disease and occipital horn syndrome. *Pediatr Dev Pathol.* 1998 ;1(1):85-98.
- Tümer Z, Tønnesen T, Böhm J, Marg W, Horn N. First trimester prenatal diagnosis of Menkes disease by DNA analysis. *J Med Genet.* 1994; 31(8):615-7.
- Lenartowicz M, Starzyński R, Wiecezszak K, Krzeptowski W, Lipiński P, Styrna J. Alterations in the expression of the Atp7a gene in the early postnatal development of the mosaic mutant mice (ATP7a(mo-ms)) - An animal model for Menkes disease. *Gene Expr Patterns.* 2010 (ahead of print).
- Goldstein DS, Lenders JW, Kaler SG, Eisenhofer G. Catecholamine phenotyping: clues to the diagnosis, treatment, and pathophysiology of neurogenetic disorders. *J Neurochem.* 1996;67(5):1781-90.
- Qadir MI. Qadirvirtide. *Pak J Pharm Sci.* 2011; 24(4): 593-595.
- Christodoulou J, Danks DM, Sarkar B, Baerlocher KE, Casey R, Horn N, Tümer Z, Clarke JT. Early treatment of Menkes disease with parenteral copper-histidine: long-term follow-up of four treated patients. *Am J Med Genet.* 1998; 76(2):154-64.
- Tümer Z, Horn N. Menkes disease: recent advances and new insights into copper metabolism. *Ann Med.* 1996; 28(2):121-9.
- Kaler SG, Buist NR, Holmes CS, Goldstein DS, Miller RC, Gahl WA. Early copper therapy in classic Menkes disease patients with a novel splicing mutation. *Ann Neurol.* 1995; 38(6):921-8.
- Kaler SG, Das S, Levinson B, Goldstein DS, Holmes CS, Patronas NJ, Packman S, Gahl WA. Successful early copper therapy in Menkes disease associated with a mutant transcript containing a small in-frame deletion. *Biochem Mol Med.* 1996; 57(1):37-46.