

## Lobular histology and response to neoadjuvant chemotherapy in invasive breast cancer

Esther H. Lips · Rita A. Mukhtar · Christina Yau · Jorma J. de Ronde ·  
Chad Livasy · Lisa A. Carey · Claudette E. Loo · Marie-Jeanne T. F. D. Vrancken-Peeters ·  
Gabe S. Sonke · Donald A. Berry · Laura J. van't Veer · Laura J. Esserman ·  
Jelle Wesseling · Sjoerd Rodenhuis · E. Shelley Hwang · I-SPY TRIAL Investigators

Received: 4 May 2012 / Accepted: 24 August 2012  
© Springer Science+Business Media, LLC. 2012

**Abstract** Invasive lobular carcinoma (ILC) has been reported to be less responsive to neoadjuvant chemotherapy (NAC) than invasive ductal carcinoma (IDC). We sought to determine whether ILC histology indeed predicts poor response to NAC by analyzing tumor characteristics such as protein expression, gene expression, and imaging features, and by comparing NAC response rates to those seen in IDC after adjustment for these factors. We combined datasets from two large prospective NAC trials, including in total 676 patients, of which 75 were of lobular

histology. Eligible patients had tumors  $\geq 3$  cm in diameter or pathologic documentation of positive nodes, and underwent serial biopsies, expression microarray analysis, and MRI imaging. We compared pathologic complete response (pCR) rates and breast conservation surgery (BCS) rates between ILC and IDC, adjusted for clinico-pathologic factors. On univariate analysis, ILCs were significantly less likely to have a pCR after NAC than IDCs (11 vs. 25 %,  $p = 0.01$ ). However, the known differences in tumor characteristics between the two histologic types, including hormone receptor (HR) status, HER2 status, histological grade, and p53 expression, accounted for this difference with the lowest pCR rates among HR+/HER2– tumors in both ILC and IDC (7 and 5 %, respectively). ILC which were HR– and/or HER2+ had a pCR rate of 25 %.

Esther H. Lips and Rita A. Mukhtar contributed equally to this study.

**Electronic supplementary material** The online version of this article (doi:10.1007/s10549-012-2233-z) contains supplementary material, which is available to authorized users.

E. H. Lips · J. J. de Ronde  
Department of Experimental Therapy, The Netherlands Cancer Institute, Amsterdam, The Netherlands  
e-mail: e.lips@nki.nl

R. A. Mukhtar · L. J. Esserman · E. Shelley Hwang  
Department of Surgery, University of California, San Francisco, San Francisco, CA, USA

C. Yau  
Buck Institute for Aging, Novato, CA, USA

C. Livasy · L. A. Carey  
Lineberger Comprehensive Cancer Center, University of North Carolina at Chapel Hill, Chapel Hill, NC, USA

C. E. Loo  
Department of Radiology, The Netherlands Cancer Institute, Amsterdam, The Netherlands

M.-J. T. F. D. Vrancken-Peeters  
Department of Surgery, The Netherlands Cancer Institute, Amsterdam, The Netherlands

G. S. Sonke · S. Rodenhuis (✉)  
Department of Medical Oncology, The Netherlands Cancer Institute, Plesmanlaan 121, 1066 CX Amsterdam, The Netherlands  
e-mail: s.rodenhuis@nki.nl

D. A. Berry  
Department of Biostatistics, MD Anderson Cancer Center Statistical Center, Houston, TX, USA

L. J. van't Veer  
University of California San Francisco Helen Diller Family Comprehensive Cancer Center, San Francisco, CA, USA

J. Wesseling  
Departments of Pathology, The Netherlands Cancer Institute, Amsterdam, The Netherlands

E. Shelley Hwang (✉)  
Department of Surgery, Duke University Comprehensive Cancer Center, 465 Seeley Mudd Building, Durham, NC 20010, USA  
e-mail: shelly.hwang@duke.edu

Expression subtyping, particularly the NKI 70-gene signature, was correlated with pCR, although the small numbers of ILC in each group precluded significant associations. BCS rate did not differ between IDC and ILC after adjusting for molecular characteristics. We conclude that ILC represents a heterogeneous group of tumors which are less responsive to NAC than IDC. However, this difference is explained by differences in molecular characteristics, particularly HR and HER2, and independent of lobular histology.

**Keywords** Neoadjuvant chemotherapy · Lobular breast cancer · Gene expression arrays · Predictive factors

## Introduction

Neoadjuvant chemotherapy (NAC) is increasingly used in the treatment of patients with large but still operable breast cancer or proven lymph node metastases. Although the overall survival benefit is similar to that of adjuvant chemotherapy [1, 2], NAC has two main advantages. First, reducing the tumor burden in the breast increases the rate of breast conservation surgery [3, 4]. Second, it allows assessment of tumor response to specific chemotherapeutic agents. The conventional outcome measurement of NAC is pathologic complete response (pCR) at surgery, which has been shown to be associated with improved survival [5, 6].

The rates of pCR differ among molecular subtypes, but it is not known how tumor histology affects these rates. Invasive breast cancers can be divided into two main histologic subtypes: ductal and lobular. Invasive lobular cancers (ILCs) account for 10 % of breast cancers, comprising a small but important subgroup. They are characterized by loss of the cell adhesion marker e-cadherin, and a diffuse growth pattern characterized by non-cohesive cells arranged in a single-file pattern [7, 8].

ILC and invasive ductal cancer (IDC) differ in expression of standard histopathology markers, molecular expression patterns, and radiographic appearance [9–11]. Compared to IDC, ILCs are more likely to be hormone receptor (HR) positive [12], less likely to be high grade, and often appear more diffuse both radiographically and clinically. Some of these differences are attributable to differences in cell adhesion resulting from loss of e-cadherin, rather than to different anatomical origins, as both ILC and IDC are derived from the terminal duct lobular unit [11].

Several reports have suggested that ILC is less responsive to chemotherapy than IDC and thus should be treated with endocrine therapy only [10, 13, 14]. Similarly, investigators have noted a lower pCR rate to NAC among lobular cancers, which may result in a lower rate of breast

conservation surgery (BCS) than in IDC [15, 16]. However, it remains unclear whether lower rates of pCR and BCS observed in ILC are due to histology or to biologic and molecular factors associated with histology, such as HR status [16–19].

In view of the controversy over the role of NAC in ILC, we compared ILC and IDC in a large series of neoadjuvantly treated breast cancer patients for whom MR imaging and gene expression data were available. We compared clinical, pathological, and molecular features of ILC and IDC using pCR and BCS rates as the primary outcome variables. We report the combined results from two neoadjuvant studies with a total sample size of 676 locally advanced breast cancers, of which 75 were ILCs. We compare molecular characteristics, and relate them to differences in pathologic and surgical outcomes for ILC and IDC.

## Methods

### Subjects

Study subjects were treated through the I-SPY 1 trial ( $n = 221$ ) or two ongoing neoadjuvant studies at the Netherlands Cancer Institute (NKI,  $n = 455$ ). The I-SPY 1 trial was a multi-center NAC trial in the United States which accrued patients between 2002 and 2006 [20, 21]. Eligible patients were women with invasive breast cancer measuring at least 3 cm by clinical examination or imaging, with no evidence of distant metastatic disease. All patients received anthracycline-based NAC, with the use of taxanes left to the discretion of the treating physicians. After 2005, trastuzumab was given to patients whose tumors were HER2+ ( $n = 20$ ). Patients underwent serial core needle biopsies before, during, and after NAC, as well as serial MRI examinations.

The two NKI trials accrued 181 and 274 patients between 2004 and 2010. Eligible patients had a breast carcinoma with either a primary tumor size of at least 3 cm, or the presence of axillary lymph node metastases proven by fine needle aspiration (FNA) [22, 23]. A treatment regimen was assigned to each patient, consisting of one of the following, depending on the study: (1) six courses of dose-dense doxorubicin/cyclophosphamide (ddAC) or (2) six courses of capecitabine/docetaxel (XD). If the therapy response was considered unfavorable by MRI evaluation after three courses, ddAC was changed to XD or vice versa. Patients with HER2+ tumors received three 8-week courses of trastuzumab, paclitaxel, and carboplatin (PTC). Patients underwent serial core needle biopsies before and after NAC. A subset of patients ( $n = 138$ ) underwent serial MRI examinations.

## Standard pathology biomarkers

All breast pathology slides were reviewed by specialty trained breast pathologists (JW for the NKI, CL for the I-SPY 1 trial). A tumor was termed ILC based on histologic growth pattern. E-cadherin staining was performed centrally for the I-SPY subjects and NKI subjects, respectively, but was not included in the definition of ILC. Standard clinical biomarkers including HR and HER2 status were measured at local sites using immunohistochemistry and/or fluorescence in situ hybridization assays (FISH) in the case of HER2. P53 expression was assessed by immunohistochemistry, centrally for the I-SPY 1 patients or at the NKI for the NKI patients. pCR was defined as the absence of invasive tumor in both the breast and axillary lymph nodes after NAC. A patient with only residual DCIS or microscopic tumor cells was considered to have a pCR.

## Molecular data

High quality gene-expression arrays were available on 149 patients from the I-SPY trial (Agilent arrays) and 265 patients from the NKI trials (Illumina 6v3 arrays). From the I-Spy 1 trial, intrinsic subtype classification was determined by PAM50 50-gene assays [24]. The 70-gene prognostic profile was determined using representative probes as previously described and classifies patients as high or low risk for recurrence [25]. The wound healing signature was used to classify tumors as quiescent or activated [26].

## Imaging data

For I-SPY 1 patients, centrally trained breast radiologists at each site read all MRIs and assigned an imaging phenotype for the pre-treatment MRI based on five previously described imaging patterns: (1) well defined, unicentric mass; (2) well defined, multilobulated mass; (3) area enhancement with nodularity; (4) area enhancement without nodularity; and (5) septal spreading [27]. For the subjects enrolled at NKI, a specialized breast radiologist (CL) determined whether pre-treatment MRIs showed the tumor to be either mass-like, multinodular, or diffuse. For purposes of analysis, the 5 phenotypes used in the I-SPY 1 trial were collapsed such that phenotypes 1 and 2 were defined as mass-like; phenotype 3 was multinodular; and phenotypes 4 and 5 were considered to be diffuse. A consort diagram showing availability of pathology biomarker, molecular, and imaging data (overall and by site) is shown in Fig. 1.

## Statistical analysis

Data from the I-SPY 1 and NKI trials were combined and analyzed together, without adjustments for site-specific

differences. Associations between histologic subtype and other clinical, pathological, molecular, and imaging parameters were assessed using the Chi-square test for categorical and Student's *t* test for continuous variables, respectively. pCR and BCS rates for ILCs and IDCs were compared using the Fisher exact test over all cases and within subsets defined by histologic subtype-associated variables. Associations between pCR and BCS with histologic subtype-associated features were also assessed using univariate logistic regression and provided as supplemental results. Data were analyzed in Stata Version 11 (College Station, Texas) and JMP 9.0.0 (SAS Institute Inc).

## Results

### Clinical and pathological characteristics of ILC versus IDC

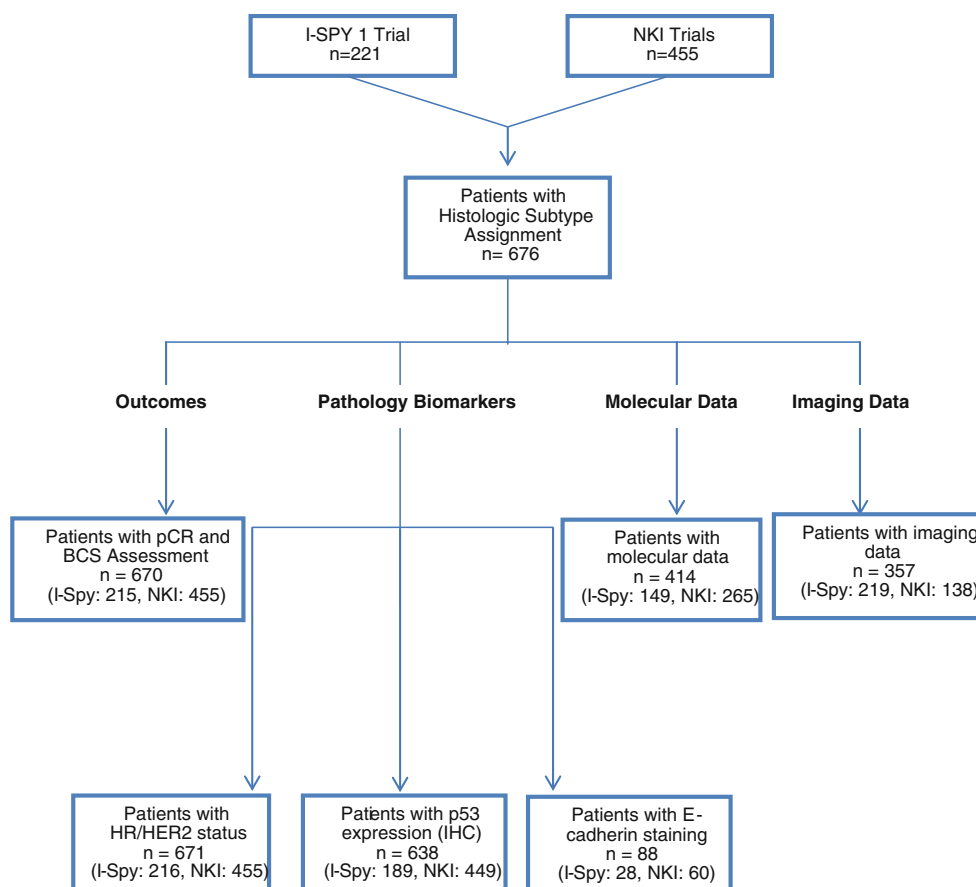
Subjects with ILC were older at diagnosis, more likely to have larger tumors at presentation (defined as higher T stage by pre-treatment MRI) and a multinodular pattern on MRI when compared to subjects with IDC (Table 1). However, when the analysis was restricted to HR+/HER2– tumors, there were no significant differences between MRI pattern (60 and 31.5 % multinodular in ILC and IDC, respectively,  $p = 0.099$ ). Race, proportion of patients with positive lymph nodes, and chemotherapeutic regimens administered were similar between subjects with ILC and IDC.

### Molecular characteristics of ILC versus IDC

ILC cases were more likely to be HR+/HER2– than IDC cases (79 vs. 46 %,  $p < 0.001$ ). Additionally, ILC cases were less likely to be high grade, and had lower rates of p53 expression than IDC cases. Overall, 85 % of ILC designated on the basis of histopathology were negative for e-cadherin.

A subset of cases (41/75 ILC and 368/595 IDC) had evaluable gene expression data. Consistent with the HR and HER2 comparison, the luminal A subtype was more common in lobular than ductal cancers (Table 1). Despite the prevalence of the luminal A subtype, ILCs were heterogeneous, with all intrinsic subtypes represented (Table 1). In particular, 4/41 (10 %) of ILCs were found to be of the basal intrinsic subtype, compared to 26 % of IDC. All four basal ILC cases were grade 2; two were e-cadherin negative, and two were e-cadherin positive.

ILC cases had decreased expression of the activated wound healing signature compared to IDCs (22 vs. 65 %,  $p < 0.001$ ) and lower risk according to 70-gene prognostic profile (56 vs. 90 %,  $p < 0.001$ ). Significant differences



**Fig. 1** Consort diagram showing data availability

persisted when analysis was restricted to HR+ cases only: 18 % of HR+ ILC versus 56 % of HR+ IDC expressed the activated wound healing signature, and 54 % of HR+ ILC versus 84 % of HR+ IDC had a the high risk 70-gene prognostic profile in this cohort (data not shown).

#### Pathologic response to neoadjuvant therapy in ILC versus IDC

ILCs were significantly less likely to have a pCR after NAC than IDCs (11 vs. 24 %,  $p = 0.008$ ). However, ILC and IDC have different clinical, pathological, and molecular characteristics; and among the nine variables showing a significant association with histological subtype (Table 1), six were also significantly correlated with pCR (HR/HER2 subtype, grade, p53 expression, molecular subtype, wound healing signature, and 70-gene signature risk groups, Supplemental Table 1). When we adjusted for these six features, differences in pCR rates between ILC and IDC were no longer significant within individual clinical HR/HER2 subtypes or dichotomized subsets defined by grade (1/2 or 3) and p53 expression ( $\leq 75$  or  $>75$  %) (Table 2). Among the 41 ILC cases for which gene expression data were available, ILC had significantly

lower pCR rates within the 70-gene high risk group than IDCs (4 vs. 27 %,  $p = 0.013$ ). None of the basal-like ILC had pCR, compared to 41 % among the IDC. In addition, ILC cases within the wound healing quiescent group also appeared less likely to achieve a pCR than their IDC counterparts (0 vs. 15 %,  $p = 0.026$ ).

#### Surgical outcomes in ILC versus IDC

Overall, ILCs had a significantly lower rate of successful BCS after NAC than IDCs (33 vs. 46 %, Fisher exact test  $p = 0.037$ ). However, among the clinical, pathological, and molecular features associated with lobular histology, age, T stage, and MRI pattern were also significantly associated with BCS (Supplemental Table 2). Patients over the age of 49 were 1.5 times as likely to have BCS ( $p = 0.007$ , 95 % CI 1.12–2.1). Higher T stage at presentation was significantly associated with decreased odds of BCS (OR 0.38 for T2 tumors compared to T1,  $p = 0.006$ , 95 % CI 0.19–0.76), as was a non-mass pattern on MRI (OR 0.26 and 0.43,  $p < 0.001$  and  $p = 0.002$ , 95 % CI 0.15–0.44 and 0.26–0.73 for multinodular and diffuse patterns, respectively, when compared to the mass MRI pattern). The difference in BCS rates between ILC and IDC

**Table 1** Clinical, histological, and molecular characteristics of the study cohort: comparison of ILCs and IDCs

	ILC	IDC	Overall	<i>p</i> value
Mean age (years), <i>t</i> test	( <i>n</i> = 75) 50	( <i>n</i> = 601) 46	( <i>n</i> = 676) 47	0.004
Race	( <i>n</i> = 75)	( <i>n</i> = 601)	( <i>n</i> = 676)	0.6
Caucasian	71 (95 %)	549 (91 %)	620 (92 %)	
African American	3 (4 %)	39 (6.5 %)	42 (6 %)	
Other	1 (1 %)	13 (2 %)	14 (2 %)	
Tumor stage at presentation (by MRI)	( <i>n</i> = 75)	( <i>n</i> = 600)	( <i>n</i> = 675)	0.001
T1	0 (0 %)	38 (6.3 %)	38 (5.6 %)	
T2	25 (33 %)	289 (48 %)	314 (47 %)	
T3	44 (59 %)	220 (37 %)	264 (39 %)	
T4	6 (8 %)	53 (8.8 %)	59 (8.7 %)	
Node positive	( <i>n</i> = 74)	( <i>n</i> = 600)	( <i>n</i> = 674)	0.11
47 (64 %)	435 (73 %)	482 (72 %)		
Chemotherapy regimen	( <i>n</i> = 75)	( <i>n</i> = 601)	( <i>n</i> = 676)	0.32
AC	29 (39 %)	229 (38 %)	258 (38 %)	
ACT	38 (51 %)	259 (43 %)	297 (44 %)	
ACT and herceptin	8 (12 %)	110 (18 %)	118 (18 %)	
ACT and other	0 (0 %)	3 (0.5 %)	3 (0.4 %)	
MRI pattern	( <i>n</i> = 46)	( <i>n</i> = 385)	( <i>n</i> = 431)	<0.001
Mass	6 (13 %)	173 (45 %)	179 (42 %)	
Multinodular	26 (57 %)	101 (26 %)	127 (30 %)	
Diffuse	14 (30 %)	111 (29 %)	125 (29 %)	
Marker subtypes	( <i>n</i> = 75)	( <i>n</i> = 596)	( <i>n</i> = 671)	<0.001
HR+/HER2–	59 (79 %)	276 (46 %)	335 (50 %)	
HR+/HER2+	10 (13 %)	82 (14 %)	92 (14 %)	
HR–/HER2+	3 (4 %)	79 (13 %)	82 (12 %)	
HR–/HER2–	3 (4 %)	159 (27 %)	162 (24 %)	
Grade 3	( <i>n</i> = 51)	( <i>n</i> = 436)	( <i>n</i> = 487)	<0.001
2 (3.9 %)	212 (49 %)	214 (44 %)		
p53 expression (IHC, %)	( <i>n</i> = 71)	( <i>n</i> = 567)	( <i>n</i> = 638)	0.001
<10	51 (72 %)	267 (47 %)	318 (50 %)	
10–25	11 (16 %)	84 (15 %)	95 (15 %)	
26–50	3 (4.2 %)	42 (7.4 %)	45 (7.1 %)	
51–75	1 (1.4 %)	21 (3.7 %)	22 (3.5 %)	
>75	5 (7 %)	153 (27 %)	158 (25 %)	
NKI 70-gene risk	( <i>n</i> = 41)	( <i>n</i> = 373)	( <i>n</i> = 414)	<0.001
Low risk	18 (43 %)	37 (10 %)	55 (13 %)	
High risk	23 (56 %)	336 (90 %)	359 (87 %)	
Molecular subtype	( <i>n</i> = 41)	( <i>n</i> = 373)	( <i>n</i> = 414)	<0.001
LumA	29 (71 %)	102 (27 %)	131 (32 %)	
LumB	2 (5 %)	80 (21 %)	82 (20 %)	
Basal	4 (10 %)	97 (26 %)	101 (24 %)	
HER2	2 (5 %)	64 (17 %)	66 (16 %)	
Normal	4 (10 %)	30 (8 %)	34 (8 %)	
Wound healing signature	( <i>n</i> = 41)	( <i>n</i> = 373)	( <i>n</i> = 414)	<0.001
Quiescent	32 (78 %)	132 (35 %)	164 (40 %)	
Activated	9 (22 %)	241 (65 %)	250 (60 %)	

**Table 2** Comparison of rates of pCR in ILC and IDC: stratified analysis among histological types

	ILC		IDC		Total		Fisher's exact test <i>p</i> value
	pCR/total	%	pCR/total	%	pCR/total	%	
HR/HER2 subtype <sup>a</sup>	8/75	11	144/595	24	152/670	23	<b>0.008</b>
HR+/HER2–	4/59	7	15/273	5	19/332	5	0.76
HR+/HER2+	3/10	30	26/81	32	29/91	32	1
HR–/HER2+	1/3	33	45/79	57	46/82	56	0.58
HR–/HER2–	0/3	0	56/157	36	56/160	35	0.55
Grade <sup>a</sup>	3/51	6	104/430	24	107/281	22	
1 or 2	2/49	4	32/221	14	34/270	13	0.056
3	1/2	50	72/209	34	73/211	35	1
p53 expression (IHC) <sup>a</sup>	6/71	8	129/562	23	135/633	21	
<75 %	5/66	8	66/409	16	71/475	15	0.092
≥75 %	1/5	20	63/153	41	64/158	41	0.65
NKI 70-gene risk <sup>a</sup>	1/41	2	90/368	24	91/409	22	
Low	0/18	0	0/37	0	0/55	0	na
High	1/23	4	90/331	27	91/354	26	<b>0.013</b>
Molecular subtype <sup>a</sup>	1/41	2	90/368	24	91/409	22	
LumA	0/29	0	4/101	4	4/130	3	0.58
LumB	0/2	0	8/79	10	8/81	10	1
Basal	0/4	0	39/96	41	39/100	39	0.15
HER2	1/2	50	31/63	49	32/65	49	1
Normal	0/4	0	8/29	28	8/33	24	0.55
Wound healing signature <sup>a</sup>	1/41	2	90/368	24	91/409	22	
Quiescent	0/32	0	19/131	15	19/163	12	<b>0.026</b>
Activated	1/9	11	71/237	30	72/246	29	0.29

<sup>a</sup> Total number of pCR/evaluable cases for each assay

Bold values indicate  $p < 0.05$

were no longer significant when evaluated within T stage and MRI pattern defined subsets (Table 3). ILCs remained significantly less likely to have BCS than IDCs within the older cohort (32 vs. 54 %,  $p = 0.021$ ), but not the younger cohort (35 vs. 41 %,  $p = 0.60$ ).

## Discussion

While most NAC trials have not distinguished outcome between lobular and ductal cancers, those that have done so frequently find lower rates of pCR and BCS in ILC compared to IDC. This apparent lack of benefit from NAC has led many to question whether physicians should offer NAC to patients with ILC, while others have argued that insufficient evidence exists to recommend either for or against its use [9, 10, 14, 18, 28]. Many have pointed out that lobular histology may be a marker of poor response to NAC because of its association with other factors, and not because of a difference intrinsic to lobular histology [16, 18, 19]. However, previous studies have had a small number of lobular cancers available for

**Table 3** Comparison of rates of breast conserving surgery (BCS) in ILC and IDC: stratified analysis among histologic types

	ILC		IDC		Total		Fisher's exact test <i>p</i> value
	BCS/total	%	BCS/total	%	BCS/total	%	
Overall	25/75	33	275/595	46	300/670	45	<b>0.037</b>
Age							
≤49	13/37	35	149/362	41	162/399	41	0.60
>49	12/37	32	126/233	54	138/270	51	<b>0.021</b>
T stage							
T1/T2	11/25	44	194/326	60	205/351	58	0.14
T3/T4	14/50	28	81/268	30	95/318	30	0.87
MRI pattern							
Mass	2/5	40	81/136	60	83/141	59	0.40
Multinodular	6/20	30	23/88	26	29/108	27	0.78
Diffuse	5/14	36	34/88	39	39/102	38	1

Bold values indicate  $p < 0.05$

analysis precluding the molecular subset analyses that have been performed for ductal cancers.

Given the prevailing belief that: (1) ILC represents a more homogeneous breast cancer type than IDC and that (2) ILC demonstrates a homogeneously poor response to NAC, we wished to determine whether ILC in fact consisted of different subtypes in which tumor biology rather than histology alone could be driving response to NAC. By combining findings from three NAC trials which prospectively collected clinical, molecular, and MR imaging data we had the opportunity to identify features associated with lobular histology which could explain the apparent decreased responsiveness to NAC. We postulated that a sufficiently large cohort would allow comparison of biologic and molecular predictors of response to NAC between ILC and IDC using the endpoints of pCR and BCS rate.

We confirmed that ILC differed from IDC in clinical presentation, histopathologic characteristics, gene expression, and MR imaging features. Subjects with ILC presented at older ages with higher T stage, and ILC tumors were more likely to be lower grade, HR+, HER2-, and have lower p53 expression. These findings are consistent with previous reports [7, 10, 14, 15]. In the combined cohort, pCR was achieved in 11 % of ILC and 24 % of IDC. However, when adjusted for HR and HER2 status, lobular histology was not an independent predictor of response to NAC. Regardless of histology, cancers which were HR+/HER2- had very low pCR rates (7 and 5 % among HR+/HER2- lobular vs. ductal cancers, respectively). These findings support that tumors with lobular histology generally respond poorly to NAC, but that this is due to the enrichment of the HR+/HER2- phenotype among ILC, rather than histology.

Only 41 ILC had molecular subtyping. While most of the ILC cases expressed the luminal A intrinsic subtype, nearly 10 % expressed the basal subtype. These were not due to inclusion of pleomorphic lobular cases, as none of the tumors were grade 3. The identification of a basal subset within ILC has also been reported by another group which found cytokeratin 5/6 expression, a commonly accepted marker of the basal subtype, in 17 % of ILC cases tested [29]. These observations support that both clinical and molecular heterogeneity exist among ILC.

We also found that a proportion of the ILC cases expressed the activated wound healing gene expression signature (22 % among ILC and 65 % among IDC) and more than half had a high risk 70-gene prognostic signature (56 % in ILC and 90 % in IDC), indicating the presence of biologically high risk tumors even within the ILC subset. Tumors with an activated wound healing signature express genes indicative of a wound healing environment, while tumors without expression of these genes are said to be quiescent. The activated wound healing signature is associated with poor outcomes [26]. We also compared the

70-gene prognostic signature which is a validated profile that identifies patients at a high risk of distant metastases and death [25]. The high risk 70-gene prognostic profile has also been found to be associated with pCR [30]. In this subset, the low risk signature (found in 43 % of ILC and 10 % of IDC) was 100 % predictive of failure to achieve pCR among both ILC and IDC, again supporting that the ILC phenotype includes a higher prevalence of those molecular predictors of poor NAC response when compared to IDC and that these expression patterns predict for low pCR rates in both ILC and IDC.

Radiographic findings have emerged as important clinical biomarkers, and baseline MRI characteristics in particular have been shown to be an important predictive biomarker of NAC response [31]. In this context, we sought to determine how MR findings might differ between invasive ductal and ILCs. We found that MR imaging features were significantly different between ILC and IDC, but that this observation was driven by differences between HR(+) cancers and HR(-) cancers, rather than tumor histology. Multinodular and diffuse patterns of enhancement were more prevalent among lobular cancers, with mass-like enhancement more commonly seen among ductal cancers, specifically among the HER2(+) IDC (35 % mass-like) and HR(-) IDC (61 % mass-like) compared to ILC (13 % mass-like). Although MR enhancement pattern did not independently predict for pCR, a mass-like pattern was associated with a higher breast conservation rate among women treated with neoadjuvant therapy among all tumor subtypes.

As pCR rates are low in lobular cancer, it is important to consider whether partial response rate is also a clinically meaningful goal for neoadjuvant therapy in ILC, since even if a patient does not achieve pCR, a partial response can make BCS possible. Methods for more quantitative assessment of tumor response have recently been developed including the previously described residual cancer burden and the neoadjuvant response index (NRI) [23, 32]. Analysis in the NKI cohort using NRI as the outcome yielded the same results as the pCR-based analysis, indicating that lobular histology is not independently associated with lower likelihood of partial response (data not shown). Thus, in the small subset of patients with HER2(+) or HR-negative lobular cancers, or in those patients with a mass-like pattern in MRI, there may be a role for NAC in improving outcomes of breast conserving surgery, even if pCR is not achieved.

An important limitation of this study is the small number of lobular cases for which expression data were available, even with the combined results of three clinical trials. Specifically, we discovered that although the pCR rate was 8/75 (11 %) among the total group of ILC, only one case among the 41 ILC that had expression data (2 %)

had a pCR. The clinical features of those cases with and without microarray data were reviewed, and no obvious differences emerged. We confirmed that all microarray assays were performed on pre-treatment biopsies. Given the small size of samples, the cases subjected to microarray analysis were selected for high tumor cellularity; in the lobular cases, those might have represented the more chemotherapy resistant tumors. However, the numbers are too small to derive definitive answers and the source of this substantial bias remains unclear. Conclusions based on these molecular data should therefore be interpreted with caution and confirmation in other studies is necessary to understand the clinical role of molecular subtyping in predicting response to neoadjuvant therapy in lobular cancers.

In this clinical trial cohort, we confirmed that ILC has a lower pCR rate than IDC in the setting of NAC. However, this difference could be attributed to clear differences in tumor characteristics. Among these patients, HR and HER2 status determined response to NAC independent of tumor histology. The lowest pCR rate was seen in HR+/HER2– tumors for both ILC and IDC; the low pCR rate in ILC thus reflected the high prevalence of this tumor type among lobular cancers. The small subset of HR– and/or HER2+ ILC derived benefit from neoadjuvant therapy as demonstrated by a pCR rate of 25 % in this group. Molecular heterogeneity was found among ILCs including the discovery of biologically high risk tumors as defined by high NKI score or activated wound healing signature. Future marker studies will allow greater confidence to conclude whether molecular and radiologic subtyping can enhance the ability to predict response to chemotherapy above and beyond HR and HER2 status.

**Acknowledgments** The NKI study was carried out within the framework of CTMM, the Center for Translational Molecular Medicine ([www.ctmm.nl](http://www.ctmm.nl)), Project Breast CARE Grant 030-104. The authors would like to thank Lennart Mulder for technical assistance in generating the gene expression profiles and Andrew Vincent for statistical review.

**Conflict of interest** Laura J. van't Veer declares an employment/leadership role and has stock or other ownership interests at Agendia Inc. (Chief Research Officer). The other authors declare no conflict of interest.

## References

- Gralow JR, Burstein HJ, Wood W, Hortobagyi GN, Gianni L, von Minckwitz G, Buzdar AU, Smith IE, Symmans WF, Singh B, Winer EP (2008) Preoperative therapy in invasive breast cancer: pathologic assessment and systemic therapy issues in operable disease. *J Clin Oncol* 26(5):814–819
- Mauri D, Pavlidis N, Ioannidis JP (2005) Neoadjuvant versus adjuvant systemic treatment in breast cancer: a meta-analysis. *J Natl Cancer Inst* 97(3):188–194
- Fisher B, Bryant J, Wolmark N, Mamounas E, Brown A, Fisher ER, Wickerham DL, Begovic M, DeCillis A, Robidoux A, Margolese RG, Cruz AB Jr, Hoehn JL, Lees AW, Dimitrov NV, Bear HD (1998) Effect of preoperative chemotherapy on the outcome of women with operable breast cancer. *J Clin Oncol* 16(8):2672–2685
- Mieog JS, van der Hage JA, van de Velde CJ (2007) Neoadjuvant chemotherapy for operable breast cancer. *Br J Surg* 94(10):1189–1200
- van der Hage JA, van de Velde CJ, Julien JP, Tubiana-Hulin M, Vandervelden C, Duchateau L (2001) Preoperative chemotherapy in primary operable breast cancer: results from the European Organization for Research and Treatment of Cancer trial 10902. *J Clin Oncol* 19(22):4224–4237
- Rastogi P, Anderson SJ, Bear HD, Geyer CE, Kahlenberg MS, Robidoux A, Margolese RG, Hoehn JL, Vogel VG, Dakhil SR, Tamkus D, King KM, Pajon ER, Wright MJ, Robert J, Paik S, Mamounas EP, Wolmark N (2008) Preoperative chemotherapy: updates of National Surgical Adjuvant Breast and Bowel Project Protocols B-18 and B-27. *J Clin Oncol* 26(5):778–785
- Gonzalez-Angulo AM, Sahin A, Krishnamurthy S, Yang Y, Kau SW, Hortobagyi GN, Cristofanilli M (2006) Biologic markers in axillary node-negative breast cancer: differential expression in invasive ductal carcinoma versus invasive lobular carcinoma. *Clin Breast Cancer* 7(5):396–400
- Sullivan PS, Apple SK (2009) Should histologic type be taken into account when considering neoadjuvant chemotherapy in breast carcinoma? *Breast J* 15(2):146–154
- Cristofanilli M, Gonzalez-Angulo A, Sneige N, Kau SW, Broglio K, Theriault RL, Valero V, Buzdar AU, Kuerer H, Buccholz TA, Hortobagyi GN (2005) Invasive lobular carcinoma classic type: response to primary chemotherapy and survival outcomes. *J Clin Oncol* 23(1):41–48
- Katz A, Saad ED, Porter P, Pusztai L (2007) Primary systemic chemotherapy of invasive lobular carcinoma of the breast. *Lancet Oncol* 8(1):55–62
- Turashvili G, Bouchal J, Baumforth K, Wei W, Dziechciarkova M, Ehrmann J, Klein J, Fridman E, Skarda J, Srovnal J, Hajdich M, Murray P, Kolar Z (2007) Novel markers for differentiation of lobular and ductal invasive breast carcinomas by laser microdissection and microarray analysis. *BMC Cancer* 7:55
- Arpino G, Bardou VJ, Clark GM, Elledge RM (2004) Infiltrating lobular carcinoma of the breast: tumor characteristics and clinical outcome. *Breast Cancer Res* 6(3):R149–R156
- Cocquyt VF, Blondeel PN, Depypere HT, Praet MM, Schelfhout VR, Silva OE, Hurley J, Serreyn RF, Daems KK, Van Belle SJ (2003) Different responses to preoperative chemotherapy for invasive lobular and invasive ductal breast carcinoma. *Eur J Surg Oncol* 29(4):361–367
- Tubiana-Hulin M, Stevens D, Lasry S, Guinebretiere JM, Bouita L, Cohen-Solal C, Cheral P, Rouesse J (2006) Response to neoadjuvant chemotherapy in lobular and ductal breast carcinomas: a retrospective study on 860 patients from one institution. *Ann Oncol* 17(8):1228–1233
- Boughey JC, Wagner J, Garrett BJ, Harker L, Middleton LP, Babiera GV, Meric-Bernstam F, Lucci A, Hunt KK, Bedrosian I (2009) Neoadjuvant chemotherapy in invasive lobular carcinoma may not improve rates of breast conservation. *Ann Surg Oncol* 16(6):1606–1611
- Straver ME, Rutgers EJ, Rodenhuis S, Linn SC, Loo CE, Westeling J, Russell NS, Oldenburg HS, Antonini N, Vrancken Peeters MT (2010) The relevance of breast cancer subtypes in the



- outcome of neoadjuvant chemotherapy. *Ann Surg Oncol* 17(9):2411–2418
17. Costa SD, Loibl S, Kaufmann M, Zahm DM, Hilfrich J, Huober J, Eidtmann H, du BA, Blohmer JU, Ataseven B, Weiss E, Tesch H, Gerber B, Baumann KH, Thomssen C, Breitbach GP, Ibishi S, Jackisch C, Mehta K, von MG (2010) Neoadjuvant chemotherapy shows similar response in patients with inflammatory or locally advanced breast cancer when compared with operable breast cancer: a secondary analysis of the GeparTrio trial data. *J Clin Oncol* 28(1):83–91
  18. Mathieu MC, Rouzier R, Llombart-Cussac A, Sideris L, Koscielny S, Travagli JP, Contesso G, Delalogue S, Spielmann M (2004) The poor responsiveness of infiltrating lobular breast carcinomas to neoadjuvant chemotherapy can be explained by their biological profile. *Eur J Cancer* 40(3):342–351
  19. Wenzel C, Bartsch R, Hussian D, Pluschnig U, Altorjai G, Zielinski CC, Lang A, Haid A, Jakesz R, Gnant M, Steger GG (2007) Invasive ductal carcinoma and invasive lobular carcinoma of breast differ in response following neoadjuvant therapy with epidoxorubicin and docetaxel + G-CSF. *Breast Cancer Res Treat* 104(1):109–114
  20. Esserman LJ, Berry DA, Cheang MC, Yau C, Perou CM, Carey L, DeMichele A (2012) Chemotherapy response and recurrence-free survival in neoadjuvant breast cancer depends on biomarker profiles: results from the I-SPY 1 trial (CALGB 150007/150012; ACRIN 6657). *Breast Cancer Res Treat* 132(3):1049–1062
  21. Esserman LJ, Berry DA, DeMichele A, Carey L, Davis SE, Buxton MB, Hudis C, Gray J, Perou CM (2012) Pathologic complete response predicts recurrence-free survival more effectively by cancer subset: results from the I-SPY 1 trial (CALGB 150007/150012; ACRIN 6657). *J Clin Oncol*. [Epub ahead of print]
  22. Hannemann J, Oosterkamp HM, Bosch CA, Velds A, Wessels LF, Loo C, Rutgers EJ, Rodenhuis S, van de Vijver MJ (2005) Changes in gene expression associated with response to neoadjuvant chemotherapy in breast cancer. *J Clin Oncol* 23(15):3331–3342
  23. Rodenhuis S, Mandjes IA, Wesseling J, van de Vijver MJ, Peeters MJ, Sonke GS, Linn SC (2010) A simple system for grading the response of breast cancer to neoadjuvant chemotherapy. *Ann Oncol* 21(3):481–487
  24. Parker JS, Mullins M, Cheang MC, Leung S, Voduc D, Vickery T, Davies S, Fauron C, He X, Hu Z, Quackenbush JF, Stijleman IJ, Palazzo J, Marron JS, Nobel AB, Mardis E, Nielsen TO, Ellis MJ, Perou CM, Bernard PS (2009) Supervised risk predictor of breast cancer based on intrinsic subtypes. *J Clin Oncol* 27(8):1160–1167
  25. van't Veer LJ, Dai H, van de Vijver MJ, He YD, Hart AA, Mao M, Peterse HL, van der Kooy K, Marton MJ, Witteveen AT, Schreiber GJ, Kerkhoven RM, Roberts C, Linsley PS, Bernards R, Friend SH (2002) Gene expression profiling predicts clinical outcome of breast cancer. *Nature* 415(6871):530–536
  26. Chang HY, Nuyten DS, Sneddon JB, Hastie T, Tibshirani R, Sorlie T, Dai H, He YD, Van't Veer LJ, Bartelink H, van de RM, Brown PO, van d V (2005) Robustness, scalability, and integration of a wound-response gene expression signature in predicting breast cancer survival. *Proc Natl Acad Sci USA* 102(10):3738–3743
  27. Esserman LJ, Kumar AS, Herrera AF, Leung J, Au A, Chen YY, Moore DH, Chen DF, Hellawell J, Wolverson D, Hwang ES, Hylton NM (2006) Magnetic resonance imaging captures the biology of ductal carcinoma in situ. *J Clin Oncol* 24(28):4603–4610
  28. Purushotham A, Pinder S, Cariati M, Harries M, Goldhirsch A (2010) Neoadjuvant chemotherapy: not the best option in estrogen receptor-positive, HER2-negative, invasive classical lobular carcinoma of the breast? *J Clin Oncol* 28(22):3552–3554
  29. Fadare O, Wang SA, Hileeto D (2008) The expression of cytokeratin 5/6 in invasive lobular carcinoma of the breast: evidence of a basal-like subset? *Hum Pathol* 39(3):331–336
  30. Straver ME, Glas AM, Hannemann J, Wesseling J, van de Vijver MJ, Rutgers EJ, Vrancken Peeters MJ, van Tinteren H, Van't Veer LJ, Rodenhuis S (2010) The 70-gene signature as a response predictor for neoadjuvant chemotherapy in breast cancer. *Breast Cancer Res Treat* 119(3):551–558
  31. Padhani AR, Hayes C, Assersohn L, Powles T, Makris A, Suckling J, Leach MO, Husband JE (2006) Prediction of clinicopathologic response of breast cancer to primary chemotherapy at contrast-enhanced MR imaging: initial clinical results. *Radiology* 239(2):361–374
  32. Symmans WF, Peintinger F, Hatzis C, Rajan R, Kuerer H, Valero V, Assad L, Poniacka A, Hennessy B, Green M, Buzdar AU, Singletary SE, Hortobagyi GN, Pusztai L (2007) Measurement of residual breast cancer burden to predict survival after neoadjuvant chemotherapy. *J Clin Oncol* 25(28):4414–4422