

Surgical Management of Congenital Chylothorax in Children

Authors

R. Le Nué¹, F. Molinaro¹, C. Gomes-Ferreira¹, C. Scheib-Brolly², B. Escande², P. Kühn², I. Lacreuse¹, R. Favre³, F. Becmeur¹

Affiliations

¹University Hospital of Strasbourg, Department of Pediatric Surgery, Strasbourg, France

²University Hospital of Strasbourg, Neonatal Intensive Care Unit, Strasbourg, France

³University Hospital of Strasbourg, Obstetrics and Gynaecology, Strasbourg, France

Key words

- ▣ congenital chylothorax
- ▣ surgical management
- ▣ pleural abrasion
- ▣ pleurectomy

received December 21, 2009
accepted after revision
April 05, 2010

Bibliography

DOI <http://dx.doi.org/10.1055/s-0030-1254164>
Published ahead of print:
24 June 2010
Eur J Pediatr Surg 2010; 20:
307–311 © Georg Thieme
Verlag KG Stuttgart · New York
ISSN 0939-7248

Correspondence

Rachel Le Nué
Hôpitaux Universitaires de
Strasbourg
Service de Chirurgie Pédiatrique
Hôpital de Hautepierre
67200 Strasbourg
France
Tel.: + 33 631 05 44 85
Fax: + 33 388 12 72 95
ln.rachel@gmail.com

Abstract

▼
Purpose: Aim of the study was to determine the role of surgery in the management of congenital chylothorax (CC).

Methods: We retrospectively reviewed the data of patients with CC requiring medical or surgical treatment postnatally in our institution between January 2001 and March 2009.

Results: Ten patients were treated for CC. We divided our population into 2 groups: group A consisted of patients in whom CC healed after conservative medical treatment (thoracocentesis, pleural drainage, total parental nutrition, somatostatin, intrapleural injections of povidone-iodine), and group B of patients who needed both medical and surgical treatment (pleural abrasion and/or pleurectomy). Conservative postnatal therapy was successful in 50% of cases. Of the 3 patients treated preoperatively with intrapleural injections of povidone-iodine, 2 presented with severe complications. Surgical treatment was successful in all cases, with no

surgical complications. Patients in group B had a significantly lower birth term ($p=0.0254$) and birth weight ($p=0.0021$) compared to patients in group A. Patients with a massive chylothorax (≥ 50 mL/kg/day) needed surgery significantly more often than those with chylothorax < 50 mL/kg/day ($p=0.0119$).

Conclusion: The initial postnatal medical management of CC should consist of thoracocentesis, drainage by tube thoracostomy, and total parenteral nutrition. If this treatment fails after 10 days, we propose using alternative therapies such as somatostatin (although its efficacy is not clear) and surgery. Chemical pleurodesis by intrapleural injection of povidone-iodine must be avoided in infants and small babies. Surgical management by pleural abrasion and/or pleurectomy appears to be safe and effective. Early surgical management is proposed for babies with low birth term, birth weight and massive chylothorax > 50 mL/kg/day. Long-term follow-up is needed to evaluate the potential consequences of this therapy.

Introduction

▼
Chylothorax in children can be divided into two main etiological categories: congenital and postoperative. Series in the literature generally mix both types [2,3,8,10,16,20], although they may receive different treatments. Patients with congenital chylothorax (CC) may benefit from prenatal diagnosis and management. Prenatal procedures have vastly improved during the last 15 years [5,9,12,14,19]. Intrapartum thoracocentesis and pleuro-amniotic drainage are increasingly performed and studied. The postoperative chylothorax process is not the same as the congenital one. In postoperative chylothorax, there is generally iatrogenic leakage in the thoracic duct, and the logical surgical treatment, if performed, is ligation of this thoracic duct

[13,18]. In the case of CC, no precise leakage can usually be identified, leading to more conservative strategies and other surgical treatments such as pleuroperitoneal shunts [2,10,16,20], pleural abrasion and pleurectomy. Indications for the timing and type of surgery to be performed for CC still need to be clarified.

Material and Methods

▼ Patients

We reviewed all children who had medical or surgical management of CC in the pediatric department of our institution between 1 January 2001 and 31 March 2009. The diagnosis of chylothorax was confirmed by cytological analysis of the pleural liquid (lymphocyte rates higher than

70%, high rates of total cell numbers, high triglyceride rates in cases of previous enteral nutrition).

We reviewed the medical data of the patients for a retrospective study. We divided our population into 2 main groups: group A (cases 1–5) consisted of patients with CC which resolved after conservative medical treatment; group B (cases 6–10) consisted of patients who required both medical and surgical treatment.

We collected the following data for all patients: sex of the child, time of diagnosis, side of chylothorax, cytological analysis of the pleural effusion, birth term, birth weight, type of postnatal treatment, complications after treatment and rate of recurrence.

For patients with a prenatal diagnosis of CC, the following data were added: prenatal treatment of the chylothorax and type (intrapartum thoracocentesis or pleuro-amniotic drainage). Pleuro-amniotic drainage was indicated in these cases: high liquid pressure during pleural thoracocentesis, good expansion of the lung at the end of thoracocentesis, lymphocyte rate > 90%, no associated malformation, associated ascites, hydrops or hydramnios.

Medical treatment

Conservative treatment was defined as the stepwise implementation of the following procedures: thoracocentesis, tube thoracostomy, total parenteral nutrition, somatostatin and intrapleural injections of povidone-iodine. However, use of this last step was not systematic. Somatostatin was administered intravenously, with a progressive daily increase in the dose up to 10 µg/kg/hour to minimize the adverse effects as described by Büttiker [7]. In the case of failure, surgical treatment was performed. The procedure consisted of pleural abrasion, which was more or less associated to a pleurectomy. After favorable evolution of the chylothorax, a medium-chain triglyceride-based diet was generally given (for periods between 1 week and 6 months).

Statistical analysis was done using the Instat statistical program (Graphpad Inc, San Diego, CA, USA). For the comparison of variables such as birth weight or prematurity, two-sided Student's *t*-test for unpaired groups was used to compare the means of different groups. When appropriate, 95% confidence intervals were calculated for the observed differences. Statistical evaluation of categorical variables, using contingency tables, calculation of odds ratio (OR) and 95% confidence interval (CI), were performed using Fischer's exact test. A two-sided *p* value of ≤0.05 indicated statistical significance.

Surgical procedure

All procedures were performed under general anesthesia. Different surgical approaches performed by several operators were used in our study: thoracotomy, video-assisted thoracic surgery and thoracoscopy. In all cases, a source of chyle leakage was searched for at the beginning of the procedure but never identified. A tip cleaner was used to scratch the pleura. If the pleura looked abnormal and thick, parietal pleurectomy was performed. Mediastinal and diaphragmatic pleura were treated by pleural abrasion, avoiding the phrenic nerve. In some cases, gentle abrasion of the visceral pleura of the lung was also done. One or two drains were left in each operated hemithorax at the end of the procedure.

Results

▼ We identified 10 patients for review, 6 girls and 4 boys. They were 5 in group A and 5 in group B (● Table 1).

In group A, the diagnosis of CC was postnatal for 2 patients and prenatal for 3 patients. In group B, the diagnosis was postnatal for 1 patient and prenatal for 4 patients. The prenatal diagnosis of CC did not significantly influence the type of postnatal therapy.

In group A, only 1 patient had bilateral chylothorax, while in group B, 4 out of 5 patients had bilateral chylothorax. Nevertheless, the location of the chylothorax did not significantly influence the type of postnatal treatment in our small population ($p=0.2063$).

The mean birth term in group A was 38.2 weeks of amenorrhea (WA) and the mean birth weight was 3416g. In group B, the mean birth term was 35.6 WA and the mean birth weight was 2478g. The patients who required surgery (group B) were born significantly earlier ($p=0.0254$) and with a lower birth weight ($p=0.0021$) than the patients treated only conservatively (● Fig. 1, 2).

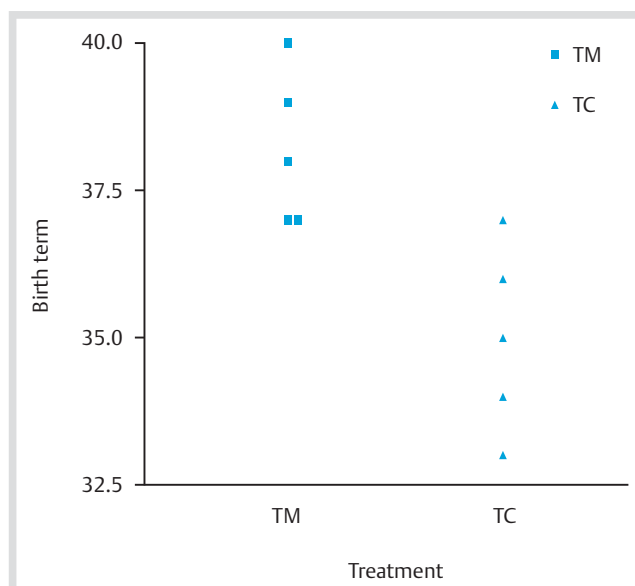


Fig. 1 Distribution of birth term depending on the type of treatment. Legend: TM: medical or conservative treatment; TC: surgical treatment.

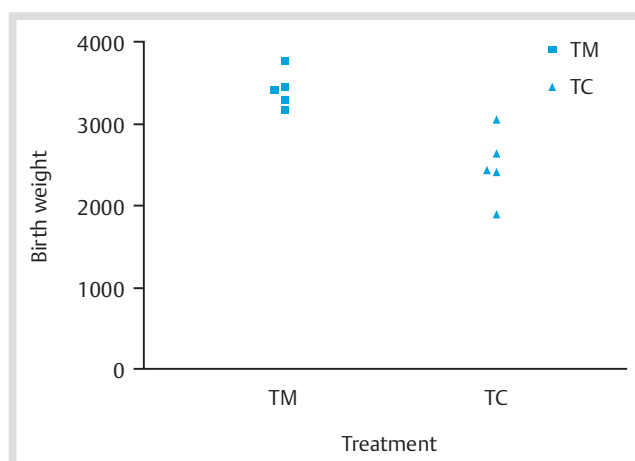


Fig. 2 Distribution of the birth weights dependent on the type of treatment. Legend: TM indicates medical or conservative treatment and TC indicates surgical treatment.

Table 1 Case series and relevant clinical parameters.

Case n°	Side	Timing of diagnosis	Antenatal treatment	Birth term (WA)	Birth weight (g)	Associated malformation syndrome	Thoraco-centesis	Maximum output of tube thoracostomy (mL/kg/day)	TPN	Octreotide	Povidone iodine injection	Duration of CT (days)	Surgery	Outcome
1	B (GAN)	AN 30WA+3d	PHA	39+4d	3 170	Schinzell Glédion	Y	13				10		H
2	L	AN 37WA		38	3 450		Y					2		H
3	R	AN 37WA		37	3 750	metabolic disease	Y	40	Y			10		H
4	R	birth		37+1d	3 300		Y					3		H
5	R	PN 3 weeks		39	3 410		Y	37				8		H
6	B	AN 31WA		35+4d	2 400		Y	50	Y	Y	B	53	Y	H
7	B	AN 35WA	BT	35+3d	2 636		Y	78	Y	Y	R	40	Y	H
8	B	AN 32WA	BD	33+6d	2 425	Noonan (suspicion)	Y	126	Y	Y	R	32	Y	H/D
9	B	AN 32WA	BD	33	1 890		Y	241	Y	Y	per-op	20	Y	H
10	L	PN 8 days		37+1d	3 040		Y	60	Y	Y		23	Y	H

L: left side; R: right side; B: bilateral; AN: antenatal; WA: weeks of amenorrhea; d: days; D: pleuro-amiotic drain; PHA: puncture of hydramnios; T: transabdominal thoracocentesis; Y: yes; SR: spontaneous regression; R: regression; H: healing (of the chylothorax); D: death; PR: partial regression

Associated malformations were identified in 3 patients: in 2 patients in group A and in 1 patient in group B. The presence of an associated malformation syndrome did not significantly influence the type of postnatal treatment.

Conservative postnatal treatment was successful in 50% of the cases (group A). Somatostatin and chemical pleurodesis obtained by injecting povidone-iodine preoperatively in the pleural cavity were ineffective in all cases. Somatostatin was started between the 6th and the 35th day of conservative management (mean 16.6 days) and administered for 6 (case No. 9) to 14 consecutive days (mean 9.8 days). One patient (case No. 9) tolerated somatostatin badly and showed adverse digestive and hemodynamic effects. These effects disappeared when the drug was stopped and did not reappear when it was resumed at a lower dose. However, the dose of 10 µg/kg/hour could not be reached in this patient. Another patient (case No. 10) only reached a dose of 7.5 µg/kg/hour over a period of 8 days, although no adverse effects were reported. We observed 2 complications following chemical pleurodesis by povidone-iodine: 1 case of respiratory distress leading to a re-intubation (case No. 7), and 1 case of respiratory distress associated with hemodynamic failure (case No. 8). The patient who had a perioperative injection of povidone-iodine presented with postoperative cardiorespiratory failure (case No. 9). The mean length of conservative treatment in the neonatal period for patients in group A was 6.6 days (range 2–10); in group B, the mean length of conservative treatment was 33.6 days (range 20–53). Thus, the length of the conservative treatment was significantly higher in group B ($p=0.0025$). If the conservative treatment was effective, it was effective within a maximum of 10 days.

The surgical treatment is described in **Table 2**. All patients who required surgery had a maximum drainage volume superior or equal to 50 mL/kg/day, whereas the drainage volume of patients treated only conservatively was under 50 mL/kg/day (significant difference: $p=0.0119$). Surgical treatment was effective in all patients if performed. The mean period of postoperative drainage was 4 days. No drain had to be reinserted after removal. In 1 case (No. 8), the chylous pleural effusion was stopped, but the patient died on the 48th day of life from severe acute respiratory distress syndrome. The mean follow-up for all patients was 30 months.

Discussion

Conservative treatment

In agreement with Murphy et al. [16] and Engum et al. [10], we are not in favor of prolonged conservative medical treatment. Indeed, it can be a source of severe complications such as infections, malnutrition, coagulation factor deficiency [1] and other complications caused by the prolonged hospital stay. We propose a stepwise treatment strategy.

Medical treatment, consisting of emptying the pleural space by thoracocentesis and/or pleural drainage, remains the first line option. Medical treatment must be accompanied by dietary measures, such as limiting fat intake to medium-chain triglycerides. We prefer parenteral alimentation as it has been proved to be effective within a shorter period of time [11].

In our series, all cases who improved under conservative treatment did so within a maximum of 10 days. As continuing the conservative strategy for periods of 20–53 days proved to be useless in the patients requiring surgery (group B), we

Table 2 Characteristics of surgical procedures of pleural abrasion (PA)/pleurectomy (PI).

Case n°	Surgical procedure	Duration of post-operative drainage (days)	Complications	Outcome	Follow-up (months)
6	bilateral thoracotomy – one session (PA)	3 + 3	bronchospasm	H	51
7	right VATS and left thoracoscopy – two procedures (PA)	4 + 2		H	51
8	bilateral thoracotomy – two sessions (PA)	7 + 9		H + D	/
9	bilateral thoracoscopy (one procedure) + povidone-iodine injection (PA)	2 + 7	cardiorespiratory distress	H	9
10	left thoracoscopy (PA + PI)	3		H	8

H: healing (of the chylothorax); D: death; PR: partial regression

recommend considering an alternative strategy as early as 10 days after the failure of drainage and dietary measures. The first alternative consists of the intravenous administration of somatostatin, which corresponds to the “maximal medical therapy” described by Cleveland et al. [8] But our results showed that this treatment was not effective. However, this result should be interpreted with care as two patients did not receive the recommended dose of 10 µg/kg/hour, one because of adverse effects, and one for no reported reason. As most of the successes reported in the literature are case reports [6, 7, 17] and as our series shows contradicting results, studies need to be carried out in larger populations to evaluate the efficacy of this therapy. If started as a second line strategy, the use of somatostatin may lead to an additional delay of 8 more days due to the gradual increase in doses until reaching a dosage that could be effective (10 µg/kg/hour) [7, 17].

A second alternative requiring proper consideration is a surgical approach. Surgery may be performed after the failure of somatostatin treatment (i.e., around 18 days after commencing medical treatment), or instead of somatostatin treatment (after 10 days of medical treatment). In our study, somatostatin was ineffective, which might be an argument in favor of performing surgical treatment after 10 days of failed conservative therapy. This could avoid the complications of prolonged and ineffective medical treatment, potentially shortening the stay in hospital. However, broader controlled evaluations focusing on the efficacy and adverse effects of both somatostatin treatment and surgical treatment are needed.

Finally, we strongly advise against the use of chemical pleurodesis by injecting povidone-iodine due to its ineffectiveness and the associated risks in small babies and infants. The postoperative complications of the patient who received a perioperative injection (case No. 9) indicate that the use of this therapy is questionable. Indeed, the complications were similar to those observed in patient Nos. 7 and 8, who presented with severe adverse effects directly after receiving preoperative intrapleural injections of povidone-iodine. Severe adverse effects had already been reported previously and included: an increase in respiratory distress, acidosis, hemodynamic instability, and acute renal failure evolving into severe and chronic failure [4, 15]. Consequently, we believe that intrapleural injections of povidone-iodine should no longer be performed in infants and small babies.

Surgical procedure

In congenital idiopathic and malformative chylothorax, where it is not possible to locate the precise leakage of chyle, we prefer to perform pleural abrasion rather than thoracic duct ligation. We also prefer pleural abrasion to pleuroperitoneal shunts for sev-

eral reasons. First, in our pediatric population, shunts are external and therefore a potential source of infection. Secondly, mechanical complications such as a shunt obstruction or a broken valve leading to secondary surgical intervention are not rare. Thirdly, in our series we encountered a failure in a neonate with postoperative chylothorax. We considered the failure to be a consequence of the peritoneal cavity not being able to absorb an effusion of 700 ml per day. We are therefore reluctant to perform shunting in small babies with massive chylothorax. Finally, shunt treatment is far lengthier, ranging from weeks to months [2, 10, 20], whereas the mean duration of thoracic postoperative drainage in our series was 4 days.

Pleural abrasion is a safe and efficient procedure for the management of CC resistant to conservative therapy, but the long-term effects of this technique are still unknown. We have to consider the potential consequences for pulmonary function, as well as the side effects associated with the loss of sliding between the pleura and the lung. Thus, long-term follow-up of our patients is required.

Factors in favor of early surgical treatment

We identified 3 factors significantly predisposing to surgical treatment: prematurity, a low birth weight, and a maximal daily drainage volume equal or superior to 50 mL/kg/day. As regards birth term and birth weight, we were unable to determine a reference threshold for early surgery, due to the small number of patients in our series. According to the data in **Fig. 1, 2**, the thresholds of 37 WA and 3 000 g should be studied in series with a greater number of patients, as the potential upper limits where surgery could offer significant improvement. With regard to drainage volume, we are in agreement with Cleveland and coworkers, who defined a chylothorax as massive when drainage volume was above 50 mL/kg/day [8]. Other thresholds, such as 15 mL/kg/day as discussed by Beghetti et al. [3], were not relevant to predict surgery in our experience. Massive chylothorax should lead to rapid surgical treatment if medical treatment fails. In such cases, we consider that the alternative therapy should be surgery if 10 days of conservative treatment has failed. We believe that surgery is preferable to waiting for the somatostatin to take effect, as there is a high risk of complications associated with the significant daily loss of nutrients with this type of chylothorax. The death of one of our patients who presented with these three risk factors (massive drainage volume, preterm birth and low birth weight) may be an additional argument in favor of early surgical treatment in these cases.

Bilateralism could also be a factor predisposing to earlier surgical management. It has been described as a negative factor in prenatal studies [14]. However the number of patients in our series did not permit us to confirm this. Surprisingly, the asso-

ciation with a malformation syndrome did not appear as a negative factor in our study. It is probably necessary to differentiate between syndromes associated with chylothorax as a whole and a subgroup of malformation syndromes affecting the lymphatic system specifically and diffusely.

Conclusion

▼ The primary management of postnatal CC is medical and includes thoracentesis, drainage by tube thoracostomy and total parenteral nutrition. We support early consideration of alternative therapies after 10 days of this initial treatment, if the medical treatment fails. Somatostatin can then be used, but it is not always effective. Chemical pleurodesis by intrapleural injection of povidone-iodine must be avoided in infants and small babies due to the significant risk of severe complications associated with uncertain benefits. Should somatostatin fail, at 8 days after having reached the required recommended dose at the latest, the treatment of choice is surgical management by pleural abrasion and/or pleurectomy, as this appears to be safe and effective. Surgical treatment can be performed using minimally invasive techniques such as thoracoscopy, our preferred option. Very early surgical management after 10 days of failed medical treatment is proposed for babies with a low birth term and birth weight and massive chylothorax above 50 mL/kg/day. Long-term follow-up will be needed to evaluate the potential consequences of this therapy.

Conflict of Interest: None

References

- 1 Allen EM, van Heeckeren DW, Spector ML et al. Management of nutritional and infectious complications of postoperative chylothorax in children. *J Pediatr Surg* 1991; 26 (10): 1169–1174
- 2 Azizkhan RG, Carfield J, Alford BA et al. Pleuroperitoneal shunts in the management of neonatal chylothorax. *J Pediatr Surg* 1983; 18 (6): 842–850
- 3 Beghetti M, La Scala G, Belli D et al. Etiology and management of pediatric chylothorax. *J Pediatr* 2000; 136 (5): 653–658
- 4 Brissaud O, Desfrer L, Mohsen R et al. Congenital idiopathic chylothorax in neonates: chemical pleurodesis with povidone iodine (Betadine). *Arch Dis Child Fetal Neonatal Ed* 2003; 88 (6): F531–533
- 5 Brito T, Oliveira C, Sousa L et al. Congenital chylothorax: a case report. *Ultrasound Obstet Gynecol* 2003; 21: 70–71
- 6 Bulbul A, Okan F, Nuhoglu A. Idiopathic congenital chylothorax presented with severe hydrops and treated with octreotide in term newborn. *J Matern Fetal Neonatal Med* 2009; 22 (12): 1197–1200
- 7 Büttiker V, Hug M, Burger R et al. Somatostatin: a new therapeutic option for the treatment of chylothorax. *Intensive Care Med* 2001; 27: 1083–1086
- 8 Cleveland K, Zook D, Harvey K et al. Massive chylothorax in small babies. *J Pediatr Surg* 2009; 44: 546–550
- 9 Dendale J, Comet P, Amram D et al. Le chylothorax de découverte anténatale. *Arch Pediatr* 1999; 6: 867–871
- 10 Engum SA, Rescorla FJ, West KW et al. The use of pleuroperitoneal shunts in the management of persistent chylothorax in infants. *J Pediatr Surg* 1999; 34 (2): 286–290
- 11 Fernandez Alvarez JR, Kalache KD, Grauel EL. Management of spontaneous congenital chylothorax: oral medium-chain triglycerides versus total parenteral nutrition. *Am J Perinatol* 1999; 16 (8): 415–420
- 12 Hagay Z, Reece A, Roberts A et al. Isolated pleural effusion: a prenatal management dilemma. *Obstet Gynecol* 1993; 81 (1): 147–152
- 13 Le Coultre C, Oberhänsli I, Mossaz A et al. Postoperative chylothorax in children: differences between vascular and traumatic origin. *J Pediatr Surg* 1991; 26 (5): 519–523
- 14 Longaker MT, Laberge JM, Dansereau J et al. Primary fetal hydrothorax: natural history and management. *J Pediatr Surg* 1989; 24 (6): 573–576
- 15 Mitanchez D, Walter-Nicolet E, Salomon R et al. Congenital chylothorax: what is the best strategy? *Arch Dis Child Fetal Neonatal Ed* 2006; 91: F153–154
- 16 Murphy MC, Newmen BM, Rodgers BM. Pleuroperitoneal shunts in the management of persistent chylothorax. *Ann Thorac Surg* 1989; 48: 195–200
- 17 Paget-Brown A, Kattwinkel J, Rodgers BM et al. The use of octreotide to treat congenital chylothorax. *J Pediatr Surg* 2006; 41 (4): 845–847
- 18 Selle JG, Snyder WH, Schreiber JT. Chylothorax: indications for surgery. *Ann Surg* 1973; 177 (2): 245–249
- 19 Watson WJ, Munson DP, Christensen MW. Bilateral fetal chylothorax: results of unilateral in utero therapy. *Am J Perinatol* 1996; 13 (2): 115–117
- 20 Wolff AB, Silen ML, Kokoska ER et al. Treatment of refractory chylothorax with externalized pleuroperitoneal shunts in children. *Ann Thorac Surg* 1999; 68: 1053–1057