

hip dislocations are extremely rare sports injuries and have not previously been reported in conjunction with a knee ligament injury. The severe pain and obvious deformity from the hip injury can distract from other injuries, in particular to the ipsilateral knee. This case reinforces the need for a thorough assessment of the knee joint

before hip reduction if possible and certainly after reduction of the dislocation.

▲ Croft SJ, Brenchley J, Badhe SP, et al. An unusual rugby injury. *Emerg Med J* 2006;23:e40. <http://emjonline.com/cgi/content/full/23/6/e40> doi: 10.1136/emj.2005.031013

## IMAGES IN EMERGENCY MEDICINE .....

### Unusual way of purging

**A** 17 year old woman presented to the emergency room after accidental ingestion of a toothbrush. The patient tearfully admitted that she had been self inducing vomiting to control her weight for the past 8 months. Four hours prior her admission and after a copious lunch, she used her toothbrush to induce vomiting and unintentionally swallowed it. After the accident, she noted chest pain and an intractable cough, which had resolved spontaneously by the time she reached the hospital. Plain chest radiography was performed and showed the toothbrush in the stomach (fig 1A). Gastroscopy was performed and the toothbrush was grasped with a polypectomy snare and withdrawn without complications (fig 1B).

Long ingested objects (longer than 60–100 mm) are unlikely to pass the duodenal sweep and should be removed. The accidental ingestion of the toothbrush in this case revealed an underlying serious eating disorder.

R Slim  
A Geagea  
C Yaghi  
K Honein  
R Sayegh

Gastroenterology Unit, Hotel Dieu de France Hospital, Achrafieh, Beirut, Lebanon

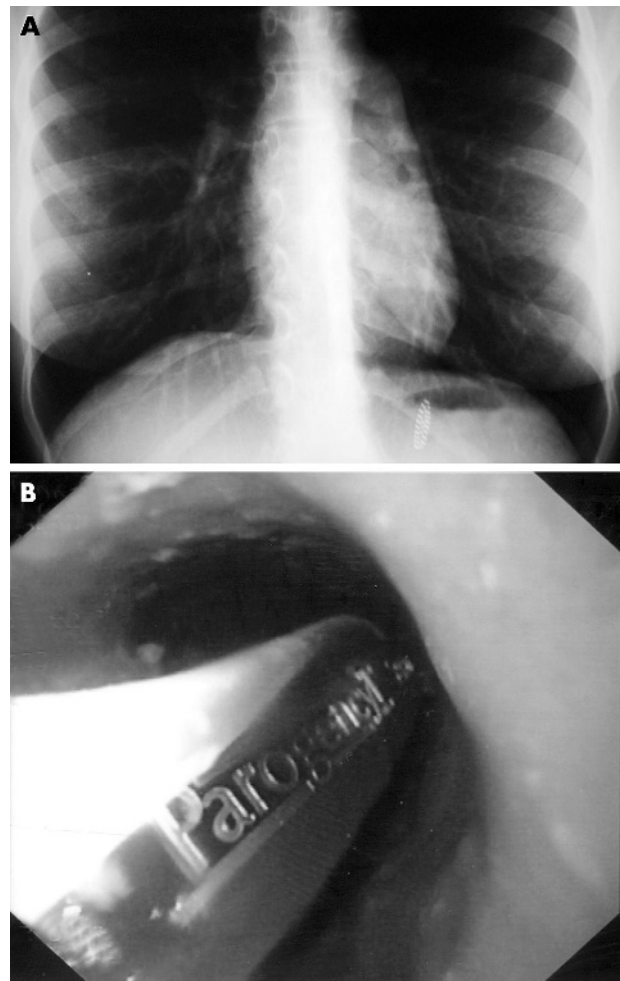
Emergency Unit, Hotel-Dieu de France Hospital, Achrafieh, Beirut, Lebanon

Correspondence to: Dr R Slim, Gastroenterology unit, Hotel-Dieu de France University Hospital; [rslimkaram@hotmail.com](mailto:rslimkaram@hotmail.com)

doi: 10.1136/emj.2005.033308

### Reference

- 1 Eisen GM, Baron TH, Dominitz JA, et al. Guideline for the management of ingested foreign bodies. *Gastrointest Endosc* 2002;55:802–6.



**Figure 1** (A) Radiograph showing toothbrush in the stomach; (B) gastroscopy view showing toothbrush.