

---

# Amelanotic Esophageal Malignant Melanoma: Case Report and Short Review of the Literature

Michael Kranzfelder<sup>a</sup> Stefan Seidl<sup>b</sup> Martin Dobritz<sup>c</sup>  
Björn L.D.M. Brücher<sup>d</sup>

Departments of <sup>a</sup>Surgery and <sup>b</sup>Pathology, and <sup>c</sup>Institute of Radiology, Technical University of Munich, Munich; <sup>d</sup>Department of Surgery, Comprehensive Cancer Center, University of Tübingen, Tübingen, Germany

## Key Words

Malignant melanoma · Esophageal cancer · FDG-PET

## Abstract

Malignant melanoma in the esophagus is a rare condition which has been described only occasionally in case reports or in larger series of patients with esophageal disease. We describe here the very rare case of a patient who presented initially with a 2-month history of dysphagia and weight loss which led to the endoscopic diagnosis of an unclear lesion in the distal esophagus. Biopsies were taken revealing positive immunohistochemical staining against HMB-45. As there were no signs of skin melanoma and there was an absence of pigmentation, a diagnosis of primary amelanotic malignant melanoma was made. Primary staging of the lesion was completed with computed tomography (CT), which revealed a locally advanced tumor with lymph node metastases at the lesser curvature of the stomach and celiac trunk. As there is still a lack of potential protocols for multimodal neoadjuvant treatment for this rare tumor entity, a palliative abdomin thoracic esophagectomy with systemic lymphadenectomy and intrathoracic anastomosis was carried out. Due to an intraoperative R2 situation, clip marking was performed to allow postoperative radiotherapy. Two months postoperatively, the planning CT scan for radiotherapy revealed progression of the retroperitoneal tumor mass, which was enclosing the celiac trunk, renal vein, and superior mesenteric artery. Multiple new liver and lung metastases were also found. During the following weeks, the patient developed acute renal failure and was admitted for dialysis, and the planned radiotherapy was deferred. At the end of May 2007, 4 months after the primary diagnosis, the patient died due to acute renal failure.

## Introduction

Primary malignant melanoma of the esophagus (PMME) is a very rare tumor entity. Exact incidence rates are not available, since only small series and case reports have been reported so far. Patients suffering from PMME are usually diagnosed at a late stage, as the lesion's initial symptoms are nonspecific and challenging for any physician. In approximately 50% of cases in Western countries, esophageal neoplasms present at locally advanced tumor stages – the most frequent type being adenocarcinoma, ahead of squamous cell carcinoma. It has been estimated that approximately 0.1–0.2% of malignant esophageal tumors are malignant melanomas. Amelanotic PMME account for 10–25% of melanomas in the esophagus [1]. The most frequently reported site for esophageal malignant melanoma is the distal part of the esophagus. Overlapping sites and unknown sites account for 26% of small bowel cancers. Neoplasms and malignant melanomas in the esophagus become overt when symptoms of dysphagia, odynophagia, weakness, or weight loss develop due to mechanical constriction.

The pathogenesis of PMME is still unclear. In the mid-20th century, it was thought that the esophageal epithelium is devoid of melanoblasts, until in 1963 melanoblasts and granules, from which PMME is capable of developing, were described in the normal esophageal mucosa. Although the origin of the melanoblasts is still unclear, it appears that they migrate from the neural crest and later differentiate into melanocytes in the esophageal wall [2].

This report describes a case of locally advanced amelanotic PMME, with locoregional lymph node metastases. Postoperative radiotherapy was planned for the patient following a palliative R2 esophagectomy. A follow-up examination after 2 months revealed progression of the retroperitoneal tumor mass, which was enclosing the celiac trunk, renal vein, and superior mesenteric artery. Multiple new liver and lung metastases were also found. Four weeks later, the patient developed acute renal failure and died in May 2007 after a short period of dialysis.

## Case Report

### *Patient History and Diagnostic Procedures*

A 57-year-old man was admitted to the surgical department in January 2007 due to a 3-month history of dysphagia, odynophagia, and weight loss of 10 kg. His medical history included a thyroidectomy due to a toxic nodular goiter, smoking (10 pack-years), arterial hypertension, and an unremarkable family history. Examination showed no evidence of skin melanoma lesions. Esophagogastroduodenoscopy identified an ulcerated tumor, 7 cm in length, in the distal esophagus. Inspection of the tumor did not raise any suspicion of malignant melanoma (fig. 1a).

Endoscopic ultrasound showed that the tumor was at a locally advanced stage (uT3 N+), with inhomogeneous tumor formation and cystic and solid components (fig. 1b). Biopsies were taken, revealing pleomorphic and hyperchromatic nuclei in the tumor cells and brown-black melanin pigmentation in the cytoplasm. Immunohistochemical staining was positive for HMB-45, MIB-1, and PAN melanoma marker Melan A, and negative for S100 protein and cytokeratin KL1.

The further staging work-up included computed tomography of the chest and abdomen, tests for cardiac and pulmonary function, and laboratory tests, which were inconspicuous except for moderate left ventricular hypertrophy. Radiographic findings showed an eccentric tumor mass in the esophageal wall and enlarged lymph nodes in the mediastinum, at the lesser curvature of the stomach, and surrounding the celiac trunk (fig. 2).

Positron-emission tomography with  $^{18}\text{F}$ -fluorodeoxyglucose (FDG-PET) correlated well with the computed tomography and revealed an accumulation of the tracer in the distal esophagus, the lesser curvature of the stomach, and the celiac trunk, with no other suspicious areas. A diagnosis of PMME was made.

### *Surgery and Histopathology*

Following an interdisciplinary discussion, the decision was taken to carry out a palliative abdominothoracic esophagectomy with systematic lymphadenectomy and with an intrathoracic esophagogastric anastomosis. In addition, abdominal tumor debulking was planned, as well as intraoperative clip marking to allow postoperative radiotherapy, due to the high risk of a macroscopic R2 resection in the area of the celiac trunk. The surgical specimen contained the ulcerative tumor in the distal esophagus and distinct lymph node conglomerates. Neoplastic infiltration included the muscularis propria and marked tumor tissue around the celiac trunk. Histopathology showed tumor cells with highly atypic nuclei, prominent macronucleoli, and high mitosis rates. No pigment was observed in the areas examined. The lymph nodes were macroscopically suspicious for tumor invasion, and histopathology revealed tumor infiltration into the mediastinal lymph nodes ( $n = 10$ ). Resection of the primary tumor was macroscopically and microscopically complete, while the lymph node conglomerate around the celiac trunk only allowed R2 resection. Immunohistochemical staining was positive for S100 (in contrast to the biopsies) and HMB-45, and was negative for CD45 and pancytokeratin. Histopathology established a diagnosis of amelanotic PMME ([fig. 3](#)).

The postoperative course was uneventful, and the patient was discharged in good condition on the 14th postoperative day. In view of the R2 situation (in the celiac trunk), a CT examination was carried out 2 months postoperatively, in March 2007, before the planned radiotherapy. The CT showed progression of the retroperitoneal tumor mass, enclosing the celiac trunk, renal vein, and superior mesenteric artery, as well as multiple liver and lung metastases. Four weeks later, the patient was admitted for dialysis due to acute renal failure, and he died in May 2007, 4 months after first being diagnosed with PMME. The relatives declined an autopsy.

### **Discussion**

The first case of PMME was described by Baur in 1906 [3]; until now, 100 years later, only approximately 250 cases have been published in the worldwide literature [4]. PMME is a very rare tumor entity, representing only 0.1–0.2% of all esophageal malignancies [5]. Amelanotic PMME account for 10–25% of melanomas in the esophagus [2] and true amelanotic PMME, which show no melanin on histopathological examination, account for only 2% [6]. PMME occur mainly in the sixth and seventh decades of life, but may develop at any age, with a male-to-female ratio of 2:1 [4]. The patient described here was a 57-year-old man. In over 90% of the reported cases, the lesions develop in the lower third of the esophagus. PMME are diagnosed at a late stage, when mechanical obstruction develops, and the patients present with symptoms of dysphagia, odynophagia, and weight loss, similar to the presentation in adenocarcinoma or squamous cell carcinoma of the esophagus. The patients usually have a symptomatic history lasting a mean of 3.5 months before a diagnosis is established [2]. In the case described here, the tumor was situated in the distal part of the esophagus, and the patient presented with a 3-month history of dysphagia, odynophagia, and weight loss.

The procedure of choice in patients with symptoms of dysphagia or odynophagia is esophagogastroduodenoscopy, with biopsies being taken at the same time, and endoluminal ultrasonography to establish the extent of the tumor in the esophageal wall. Computed tomography is used to estimate local tumor growth and peritumoral lymph node enlargement and to exclude distant metastases. Another method of detecting tumor growth in malignant melanoma is FDG-PET. The advantage of this diagnostic tool is that it is able not only to detect metastatic disease and locoregional lymph node metastases,

but also makes it possible to monitor disease activity during chemotherapy or radiotherapy [7]. According to Crippa et al. [8], FDG-PET scanning has a sensitivity for detecting lymph node metastases that ranges from 83% (in lesions 6–10 mm in size) to 100% (in lesions >10 mm). In the case presented here, FDG-PET and CT were both carried out. Gallium-67 single-photon emission computed tomography (SPECT) can also be used to image tumor size and potential metastases.

Despite the poor prognosis [1], the treatment of choice in patients with PMME is surgical resection, causing a longer mean survival than chemo- or radiotherapy alone (14 months vs. 3 months) [4]. Uthoff et al. [9] reported no difference in the survival time (14.8 months, n = 85) with surgery in comparison with radiotherapy (14.9 months, n = 10), but this might have been due to the smaller number of patients treated with radiotherapy in the group described, and radiotherapy is not generally recommended as the primary treatment for PMME [9]. To date, four patients with 5-year survival have been reported, all of whom underwent surgical resection [5]; only one patient who received radiotherapy has been reported to have a 5-year survival [10].

If a total or near total esophagectomy is not possible due to the patient's general condition, a local resection should be the therapy of choice, yielding a mean survival of 9 months [2]. In the present case, an abdominothoracic esophagectomy with intrathoracic anastomosis was carried out, and postoperative radiotherapy was planned due to an R2 resection.

A neoadjuvant multimodal therapy protocol is not currently available for gastrointestinal malignant melanoma, but some authors have reported that preoperative chemotherapy with dacarbazine and interferon beta has a marked effect on esophageal melanoma [5]. Kato et al. [11] reported that postoperative adjuvant therapy with a combination of dacarbazine, nimustine, and vincristine was effective in a patient with lymph node metastases.

PMME is clinically confirmed when no other skin lesions (e.g., in the eyes or anal mucosa) are found. In 1953, Allen and Spitz [12] defined the following diagnostic criteria for PMME: (1) typical histological pattern of melanoma, with melanin granules inside the tumor cells; (2) origin in an area of junctional changes in the squamous epithelium; (3) junctional activity with melanotic cells in the adjacent epithelium.

More accurate pretreatment diagnosis is nowadays achieved with immunohistochemical staining, as PMME typically reacts positively to HMB-45 and S100 protein and negatively to cytokeratin [4]. The case reported here met all of these criteria, despite the absence of melanin granules inside the tumor cells, and a histopathological diagnosis of amelanotic PMME was therefore made. Histopathological examination of the specimen revealed infiltration of tumor cells into the submucosal layer, as is usually reported in PMME.

When there is an R2 resection, clip marking of the area is very helpful for the radiotherapist for identifying the location for radiotherapy, which usually consists of 35–48 Gy for these patients. The prognosis for patients with PMME continues to be poor, with a reported mean survival period of approximately 13.5 months and an overall survival of 4% at 5 years [13]. Only six patients with a survival of more than 5 years have been reported in the literature [14], with 12 years being the longest reported survival period [13].

The follow-up examination after 2 months of the patient described here revealed progression of the retroperitoneal tumor mass, which was enclosing the celiac trunk, renal

vein, and superior mesenteric artery. Multiple new liver and lung metastases were also found. He died 4 months after first being diagnosed with PMME due to acute renal failure.

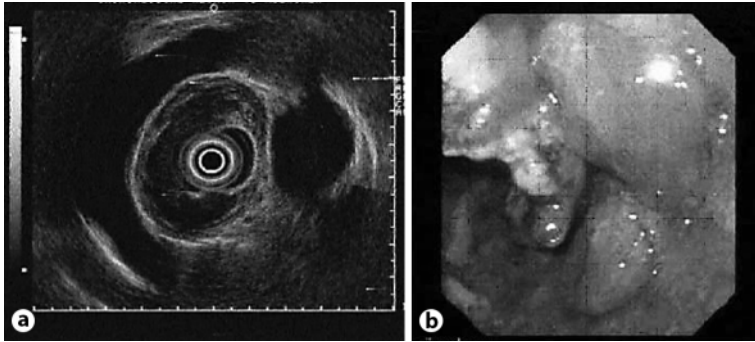
Due to the rareness of PMME, follow-up treatment for these patients has to be based on the guidelines for esophageal cancer in general [15], although the significance of postoperative radiotherapy or chemotherapy needs further investigation [8]. Until now, there are only a few cases of neoadjuvant treatment of PMME described in the literature in which either chemo- or radiotherapy [5, 14] was administered. Except in one case, where the patient already suffered from cerebral metastasis by the time of diagnosis, surgical resection was performed after neoadjuvant treatment. The mean survival period was 49.7 months, however, in two cases adjuvant chemotherapy was administered after surgical resection [14]. Excluding these two patients, who survived 132 and 88 months, the mean survival was definitely lower with 9.5 months but slightly better than the outcome after local resection. Taking this into account, neoadjuvant chemotherapy followed by total or near total esophagectomy and adjuvant chemotherapy may increase the patients' mean survival considerably, however, more data is needed to prove these findings.

In the field of adjuvant therapy, neither chemotherapy nor radiotherapy seem to show a significant effectiveness for the treatment of PMME compared to surgery alone [4]. At present, there are approximately 20 cases published in the literature [2], showing a mean survival of 15 months for patients treated with adjuvant chemotherapy and 19 months for adjuvant radiotherapy. Although not significantly affecting the mean survival of patients with PMME, some authors state that adjuvant radiotherapy is likely to be effective in preventing the probability of relapses [4].

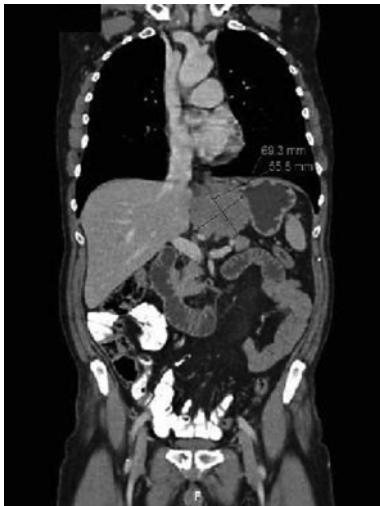As approximately 80–85% of the patients with PMME die due to/with a disseminated disease [4], surgical resection of local recurrence respectively distant metastasis plays only a minor role in the treatment concept. However, there are single cases described, where surgical resection of metastasis 2 years after the primary operation led to a disease-free follow-up of 5 to 38 months.

In conclusion, PMME is a very rare neoplasm with a poor prognosis. In most of the reported cases, widespread disease is already present at the time of diagnosis. Since there is no reliable neoadjuvant treatment, surgical resection is the therapy of choice. At present, there are no definitive data regarding the effect of postoperative chemotherapy or radiotherapy on overall 5-year survival, although some authors have reported disease control after administration of chemoradiotherapy.

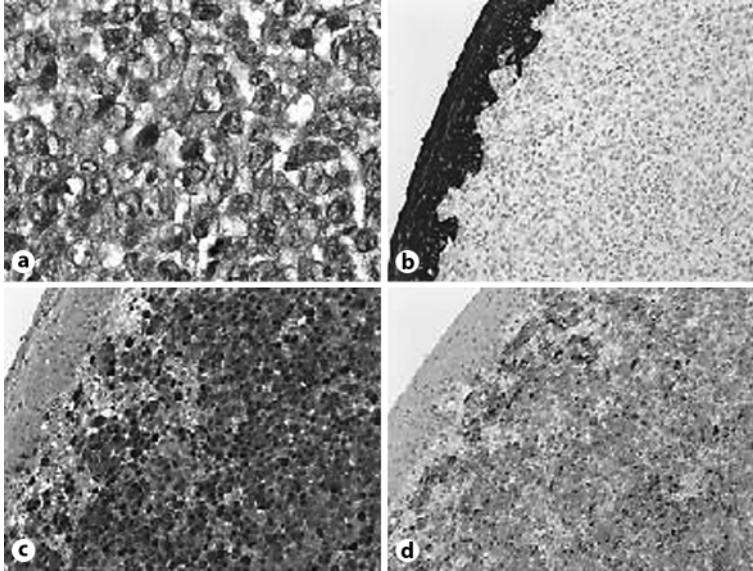
**Fig. 1.** **a** Esophagogastroduodenoscopy, showing an ulcerated tumor, 7 cm in length, in the distal part of the esophagus. **b** Endoscopic ultrasonography, showing a locally advanced tumor (uT3 N+).



**Fig. 2.** Computed tomography, showing an eccentric tumor mass in the esophageal wall and enlarged lymph nodes in the mediastinum, lesser curvature of the stomach, and surrounding the celiac trunk.



**Fig. 3.** **a** Hematoxylin-eosin staining of the tumor, showing polymorphic nuclei, prominent macronucleoli, and mitosis. **b** Pancytokeratin staining is positive in the overlying epithelium and negative in the tumor. **c** There is strongly positive staining of the tumor cells for S100. **d** Positive staining of the tumor cells for HMB-45.



## References

- 1 Stringa O, Valdez R, Beguerie JR, et al: Primary amelanotic melanoma of the esophagus. *Int J Dermatol* 2006;45:1207–1210.
- 2 Sabanathan S, Eng J: Primary malignant melanoma of the esophagus. *Scand J Thorac Cardiovasc Surg* 1990;24:83–85.
- 3 Baur EH: Ein Fall von primärem Melanom des Oesophagus. *Arb Geb Pathol Anat Inst Tuebingen* 1906;5:343–354.
- 4 Volpin E, Sauvanet A, Couvelard A, Belghiti J: Primary malignant melanoma of the esophagus: a case report and review of the literature. *Dis Esophagus* 2002;15:244–249.
- 5 Yano M, Shiozaki H, Murata A, et al: Primary malignant melanoma of the esophagus associated with adenocarcinoma of the lung. *Surg Today* 1998;28:405–408.
- 6 Watanabe H, Yoshikawa N, Suzuki R, et al: Malignant amelanotic melanoma of the esophagus. *Gastroenterol Jpn* 1991;26:209–212.
- 7 Vandewoude M, Cornelis A, Wyndaele D, Brussaard C, Kums R: (18)FDG-PET-scan in staging of primary malignant melanoma of the oesophagus: a case report. *Acta Gastroenterol Belg* 2006;69:12–14.
- 8 Crippa F, Leutner M, Belli F, et al: Which kinds of lymph node metastases can FDG PET detect? A clinical study in melanoma. *J Nucl Med* 2000;41:1491–1494.
- 9 Uthoff K, Jahne J, Meyer HJ, Pichlmayr R: Surgical therapy of primary malignant melanoma of the esophagus (in German). *Chirurg* 1996;67:86–89.
- 10 Wayman J, Irving M, Russell N, Nicoll J, Raimes SA: Intraluminal radiotherapy and Nd:YAG laser photoablation for primary malignant melanoma of the esophagus. *Gastrointest Endosc* 2004;59:927–929.
- 11 Kato N, Kamino K, Yamashita T, Umeyama K, Mitsuhashi T: Primary malignant melanoma of the esophagus (in Japanese). *Gan No Rinsho* 1986;32:1459–1465.
- 12 Allen AC, Spitz S: Malignant melanoma; a clinicopathological analysis of the criteria for diagnosis and prognosis. *Cancer* 1953;6:1–45.
- 13 Hamdy FC, Smith JH, Kennedy A, Thorpe JA: Long survival after excision of a primary malignant melanoma of the oesophagus. *Thorax* 1991;46:397–398.
- 14 Uetsuka H, Naomoto Y, Fujiwara T, et al: Primary malignant melanoma of the esophagus: long-term survival following pre- and postoperative adjuvant hormone/chemotherapy. *Dig Dis Sci* 2004;49:1646–1651.
- 15 Mariette C, Piessen G, Triboulet JP: Therapeutic strategies in oesophageal carcinoma: role of surgery and other modalities. *Lancet Oncol* 2007;8:545–553.

This paper contains original material that has not been published in or submitted to another journal.