

## IMAGES IN MEDICINE

# ICD Device Assistance in Diagnosis and Management of Atrial Tachyarrhythmia

Antonis S. Manolis, MD, Anastasio Koumoulidis, MD,  
Prokopis Papadimitriou, MD, Nikolaos Sakellaris, MD

First Department of Cardiology,  
Evangelismos General Hospital of  
Athens, Athens, Greece

---

**ABSTRACT**


---

An implanted cardiac resynchronization and defibrillator device was helpful in clarifying the diagnosis of atrial tachyarrhythmia and cardioverting the arrhythmia, and thus restoring atrio-biventricular synchrony, followed by quick response to pharmacotherapy and stabilization of a patient with acute exacerbation of heart failure.

A 75-year-old gentleman with ischemic cardiomyopathy and severe left ventricular dysfunction, fitted with a cardiac resynchronization therapy (CRT) device (biventricular cardioverter defibrillator / CRT-D device), presented with acute decompensation of heart failure three days before Christmas. A 12-lead electrocardiogram (ECG) initially showed a mostly regular rhythm at 95 bpm without apparent pacing except for an occasional beat (Figure, Panel A). He was treated with intravenous furosemide and metolazone, infusion of dobutamine, increase in the dosage of carvedilol and a bolus of digoxin; he continued receiving his regular doses of eplererone, irbesartan, amiodarone, and acenocoumarol. A repeat ECG showed a paced rhythm at the previously programmed lower rate limit of 85 bpm with not clearly discernible P waves (Panel B). The next day the patient's device was interrogated via the external programmer, which displayed the intracardiac electrograms (IEGMs) confirming a diagnosis of atrial flutter (Panel C; asterisks indicate the atrial electrograms- F or flutter waves). Subsequent attempt of conversion of the arrhythmia by overdrive pacing via the device led to degeneration into atrial fibrillation (Panel D; thin arrows point to the f waves), which, with the delivery of 30 joules through the CRT-D device (Panel D, thick arrow), was finally cardioverted into an atrio-biventricular paced rhythm (Panels E and F). Following this intervention, which restored both atrio-ventricular and intra-ventricular synchrony, the patient showed signs of rapid response to anti-congestive therapy with considerable amelioration of the respiratory, hemodynamic and clinical status. He had an increased diuresis with subsiding fluid retention and edema with resultant weight loss, was weaned off inotropic therapy, and had a remarkable and swift recovery allowing him to get discharged home the next day (Christmas Eve), just in time to celebrate Christmas at home with his family.



Atrial tachyarrhythmias, comprising atrial flutter (AFlu) and atrial fibrillation

**ABBREVIATIONS**

AF = atrial fibrillation  
AFlu = atrial flutter  
CRT = cardiac resynchronization therapy  
CRT-D = cardiac resynchronization  
therapy-defibrillator (device)  
ECG = electrocardiogram  
ICD = implantable cardioverter  
defibrillator

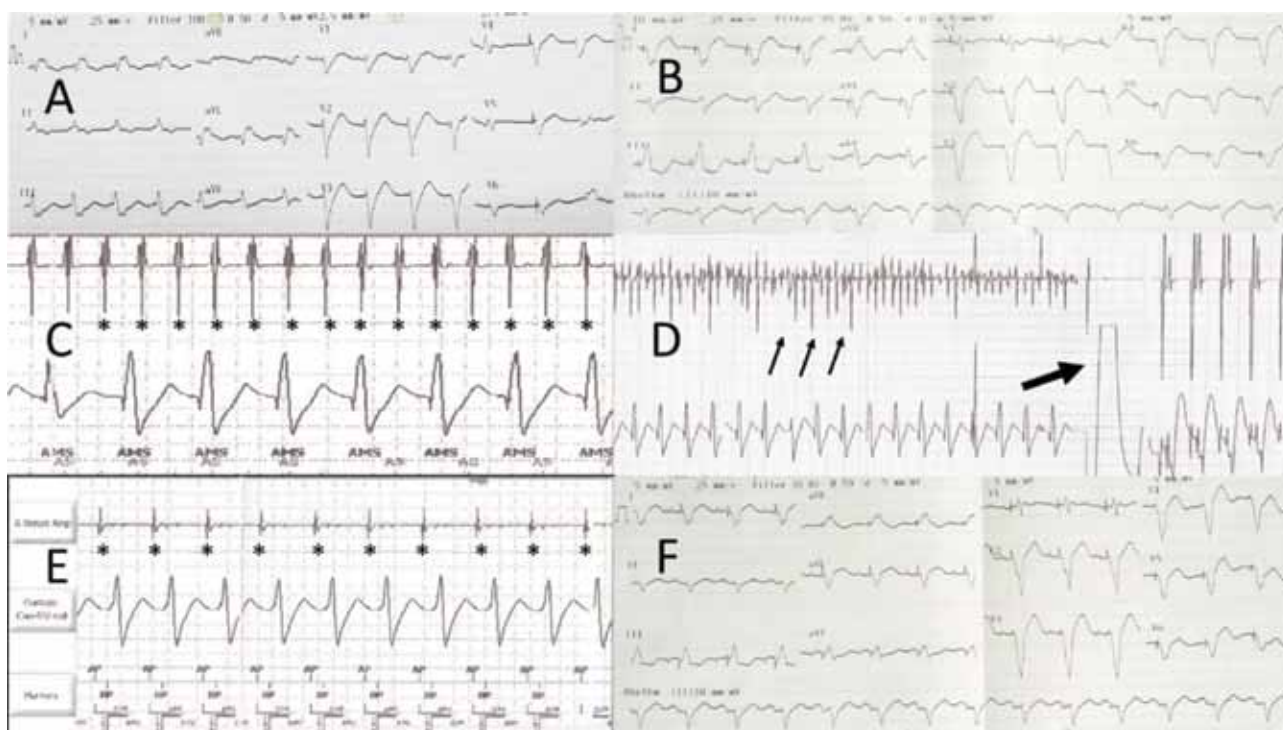
*Correspondence to:*

Antonis Manolis, MD, Evangelismos  
Hospital, Athens, Greece; *E-mail:*  
[asm@otenet.gr](mailto:asm@otenet.gr)

*Manuscript received December 24, 2013;*

*Accepted December 30, 2013*

Conflict of Interest: none declared



(AF), are particularly common in patients with left ventricular dysfunction and heart failure and their prevalence depends on the degree and severity of the underlying cardiac pathology, ranging from 10%-20% in mild to moderate heart failure to 40-50% in patients with more advanced disease.<sup>1</sup> Approximately one quarter of patients who receive an implantable cardioverter defibrillator (ICD) device have documented atrial tachyarrhythmias before implantation, while a large proportion of patients without prior history of atrial tachyarrhythmias will develop these arrhythmias after ICD implantation. Cardiac resynchronization therapy (CRT), effected via biventricular pacing usually combined with an ICD (CRT-D device), has emerged as an important and established therapy for patients with drug refractory heart failure due to systolic dysfunction (left ventricular ejection fraction <35%) and with cardiac dyssynchrony present in patients with a prolonged QRS complex, mainly in the form of left bundle branch block.<sup>2</sup> Similar to patients with ICDs, atrial tachyarrhythmias may complicate the course of up to 40% of patients with CRT-D devices.<sup>2</sup>

Management of atrial tachyarrhythmias in patients with ICDs or CRT-D devices is important because of the significant associated independent risk of increased morbidity and mortality and the increased cost of medical care conferred by the occurrence of these arrhythmias. Aside from loss of atrio-ventricular coordination, the main problem that AF or AFu produce is a fast ventricular response that exceeds the pacing rate, leading to loss of or poor response to CRT, and also to delivery of inappropriate ICD shocks if the ventricular rate is

very rapid, while fast tracking of the arrhythmia by the device further exacerbates heart failure.<sup>2</sup>

External cardioversion has long been a cause of concern regarding the potential adverse effects on the device generator and on the leads induced by the electrical shocks.<sup>3</sup> However, in a patient with an ICD or CRT-D device needing cardioversion, the shock can be delivered using the implanted device rather than the external defibrillator.<sup>4</sup> The benefit of using the internal device is that it avoids the risk of a skin irritation from an external shock and averts possible damage to the implanted system from the shock. The drawback of using the internal device is that it drains some of the battery in the device and may not always be effective in cardioverting atrial tachyarrhythmias.

In the present case, the device was also very useful in rendering the correct diagnosis, allowing to apply overdrive pacing therapy,<sup>5,6</sup> albeit it did not work in this case, and finally delivering effective internal electrical cardioversion. The ensuing restoration of atrio-biventricular synchrony led to an enhanced and remarkable response to anti-congestive therapy in this patient and an expeditious discharge from the hospital, further curtailing medical cost.

## REFERENCES

1. Yancy CW, Jessup M, Bozkurt B, et al. 2013 ACCF/AHA Guideline for the management of heart failure. *J Am Coll Cardiol* 2013; 62:e147-239.

## IMPLANTED DEVICE AIDING DIAGNOSIS & TREATMENT OF ATRIAL FLUTTER

2. 2012 EHRA/HRS expert consensus statement on cardiac resynchronization therapy in heart failure: implant and follow-up recommendations and management. EHRA; ESC; HRS; HFSA; ASE; AHA; EAE; HFA, Daubert JC, Saxon L, Adamson PB, et al. *Heart Rhythm* 2012;9:1524-1576 & *Europace* 2012;14:1236-1286.
3. Waller C, Callies F, Langenfeld H. Adverse effects of direct current cardioversion on cardiac pacemakers and electrodes: is external cardioversion contraindicated in patients with permanent pacing systems? *Europace* 2004; 6:165-168.
4. Turco P, D'Onofrio A, Stabile G, et al. Feasibility and efficacy of electrical cardioversion after cardiac resynchronization implantation in patients with permanent atrial fibrillation. *J Interv Card Electrophysiol* 2012; 35:331-336.
5. Adler SW 2nd, Wolpert C, Warman EN, Musley SK, Koehler JL, Euler DE. Efficacy of pacing therapies for treating atrial tachyarrhythmias in patients with ventricular arrhythmias receiving a dual-chamber implantable cardioverter defibrillator. *Circulation* 2001; 104:887-892.
6. Manolis AS, Dragazis I, Kapelakis I, Papadimitriou P, Sakellaris N. Transesophageal overdrive pacing: a simple and versatile tool. *Hosp Chronicles* 2013, 8:143-145.